

CASE REPORT

<https://www.ncbi.nlm.nih.gov/nlmcatalog/101671413>

www.joadms.org

Implant Insertion Using Custom Made Tooth Supported Metal Surgical Guide - A Case Report

Sauvik Mazumdar ¹, Sudipta Dutta ²

¹ Senior Lecturer, Department of Prosthodontics, Awadh Dental College and Hospital, Jamshedpur, Jharkhand

² EX Consultant, Sishu Mangal Hospital, Kolkata

ARTICLE INFO



Keywords: Implant , Tooth Supported , Implant Surgical Guide , Custom Made

ABSTRACT

Dental implants are becoming the most advanced treatment option nowadays. For a better prognosis in the implant treatment accurate placement or insertion of the implant is very much necessary. This can be achieved by fabrication of a navigation or transfer device which can be stable, static , conventional and cost effective.

Several surgical guides has been registered in the literature by various authors for precise placement of the implant.

This article provides a case report for the placement of the dental implant using custom made metal surgical guide.

Introduction

The success of implant therapy greatly depends on placing dental implants in the optimum position and angulation during surgery. Different types of surgical guides have been advocated. Stability of the surgical guide is crucial during implant placement. Most of the guides are positioned intraorally by resting them on the teeth adjacent to the implant site. ¹

However anchoring devices are costly and the procedure poses further surgical trauma to the patient. The surgical guide described is stable during surgery due ti cross arch fixation. Compared with anchor pins and transitional implants, this technique is more convenient ,

economical and less traumatic for the patient. It can be used with any implant system and only minimum materials and components are required. ¹

Although implant placement in jaws is a surgical procedure, reports on this topic, using a surgical guide, while inserting an implant, are sparse. To identify accurate implant placement pre-surgically, various kinds of surgical templates have been proposed. Such templates can be constructed from a wax-up, by duplicating the patient's existing denture. ²

Several authors have reported the use of computer- aided design surgical guide templates . Others have preferred using custom-made surgical templates. It has been claimed that dental implants placed using surgical

guides are more accurately positioned than those placed without a guide. Correct angulation and occlusal relationships can be assessed much more easily using dental casts, because the lingual tissues are not obscured by the tongue, than in the patient's mouth. If a dental implant is inserted with correct angulation, the position of abutment will be suitable and will result in a functional and aesthetically pleasing prosthesis.²

Alveolar bone supported templates were preferred until recently as stereolithographic guides; however, there was no depth control of the osteotomy drills. Tooth or mucosa-supported guides were then used to insert implants without the need for flap elevation. With implant insertion via stereolithographic surgical templates based on dental volumetric tomography, soft tissue was reported to create a difficulty. The accuracy of placed implants, compared with the planned implants, has been a significant concern with all guide systems. Without a doubt, the soft tissue is an important factor affecting the precision of implant positioning.³

Mucosa-supported guides are seated over the mucosa using a previously prepared occlusal bite registration and fixed through previously

planned osteosynthesis screw holes to the underlying alveolar bone. In this technique, the soft tissue is an additional factor rise to discrepancies between planned and placed implant positions. Therefore, it would be important to determine whether, by elimination of the soft-tissue factor, the desired precision can be achieved.³

CAD/CAM technology uses data from computerized tomography scan (CT) to plan implant rehabilitation. The CT images are converted into data that are recognized by a CT imaging and planning software. This software then transfers this presurgical plan to the surgery site using stereolithographic drill guides.⁴

Accuracy of CAD/CAM technology in dental implant planning and predictable transfer of the presurgical plan to the surgical site has been documented. However, the effectiveness has not yet become an established fact and still needs ongoing research. This technique has certain drawbacks. Special training for familiarity with the entire system and special equipment is necessary.⁴

Also, a considerable number of technique-related complications were observed. The various complications recorded were related to

inaccurate planning, radiographic stent error, intrinsic errors during scanning, software planning, the rapid prototyping of the guide stent, and the transfer of information for the prosthetics. However, if the clinician recognizes these sources of inaccuracy, efforts can be made to minimize the error and optimize patient treatment.⁴

We reported an usual case of dental implant insertion in maxillary right lateral incisor in adult male with the help of custom guided tooth supported metal surgical guide.

CASE REPORT

A 52 years old male patient reported to the department of dentistry, Shishu mangal hospital kolkata (Ramkrishna Mission Seva Pratishtan) with a chief complaint of missing maxillary right lateral incisor and wanted to get that replaced. There was no significant medical and dental history.

Extraoral examination revealed convex facial profile and presence of good facial balance in all proportions.

Intraoral clinical examination revealed missing 12. A comprehensive periodontal examination was done which included the soft and hard supporting tissues of the dentition. The patients

tissue biotype was thick over the supporting bone with flat gingival architecture, supported by thick labial and palatal plates of alveolar bone (Classified according to Becker and Oschenbein). The crestal bone level was 3mm from the CEJ of the adjacent teeth with mild gingival recession. The inter proximal attachment level in the future prosthetic site as well as the gingival architecture, the position of teeth relative to the arch shape and opposing occlusion was normal.

Bone mapping was done with the help of bone calliper which revealed Siebert's class II and Lekholm and Zarb class II bone quality.

Preliminary diagnostic study models for both maxilla and mandible was made to evaluate the occlusion, the edentulous space, ridge relationship to the adjacent teeth and the opposing dentition, amount of vertical and horizontal overlap as well as the restorative space available.

Radiographic examination was done with a preliminary orthopantomogram (OPG) and an intraoral periapical radiography followed by a Cone Beam Computerised tomographic scan (CBCT). All financial obligations, treatment consent as well as aesthetic goals are established prior to taking any further steps.

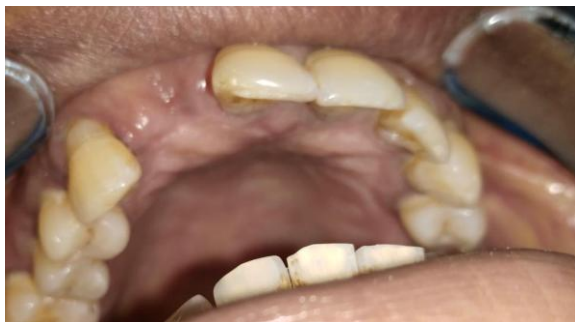

Fig 1. Per operative intraoral picture

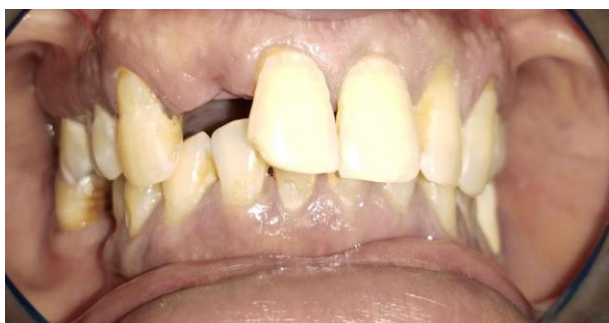

Fig 2. Pre operative intraoral picture

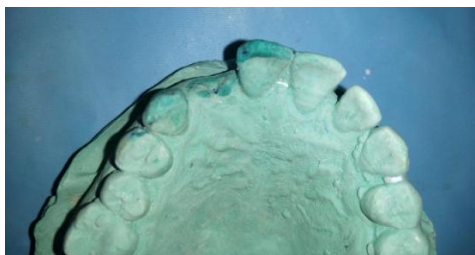

Fig 3. Pre operative Picture of the diagnostic cast

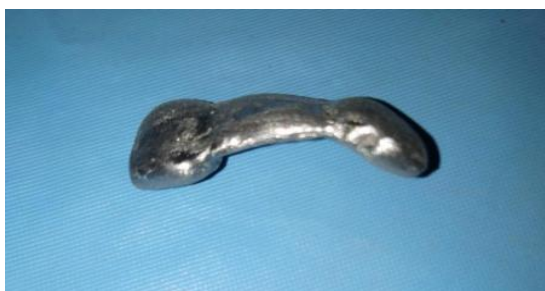

Fig 4. Picture of the metal custom made surgical guide

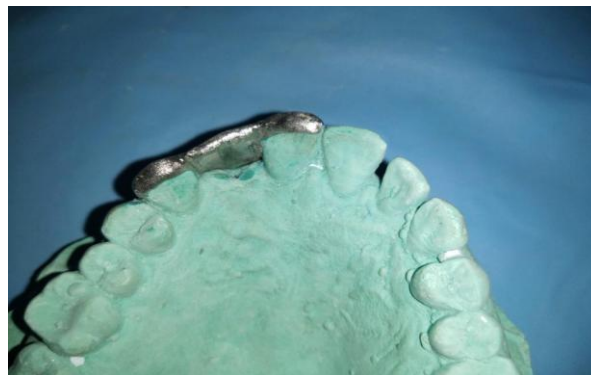

Fig 5. Picture of the custom made metal surgical guide in the cast

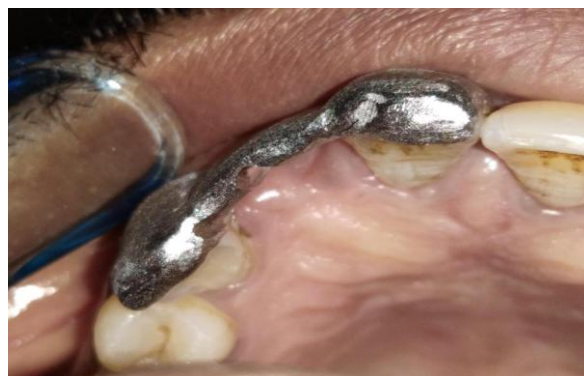

Fig 6 . Picture of the metal custom made implant surgical guide in the patient's mouth

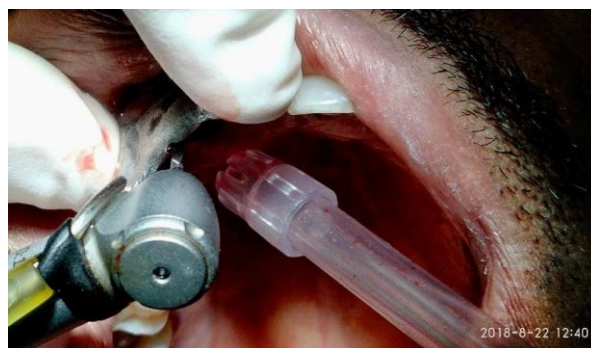

Fig 7. Picture of the metal custom made surgical guide in patient's mouth during drilling procedure

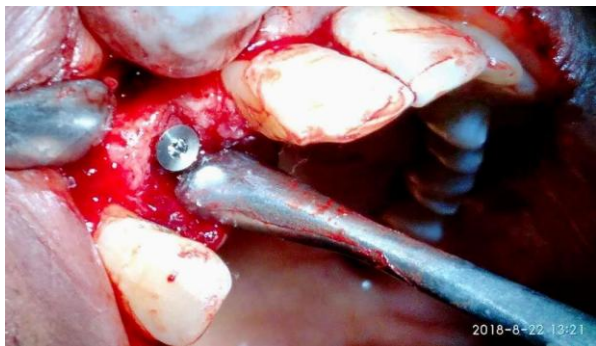

Fig 8. Picture of the place implant in the proposed site

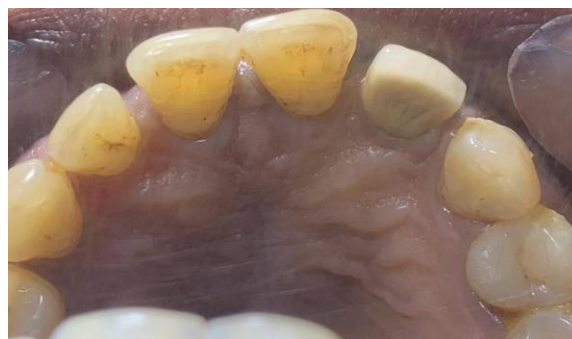

Fig 11 picture of the prosthesis after 3 months

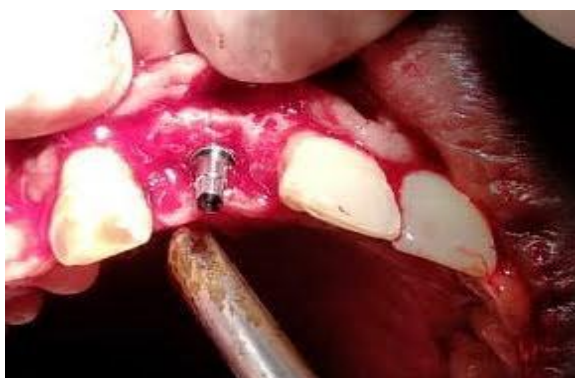

Fig 9 . Picture of the parallel pin in the proposed drill site

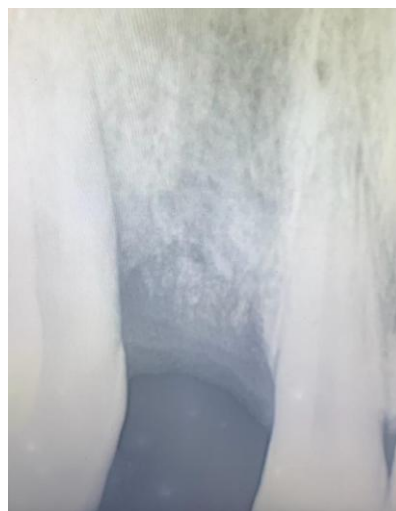

Fig 12. Pre operative radiograph

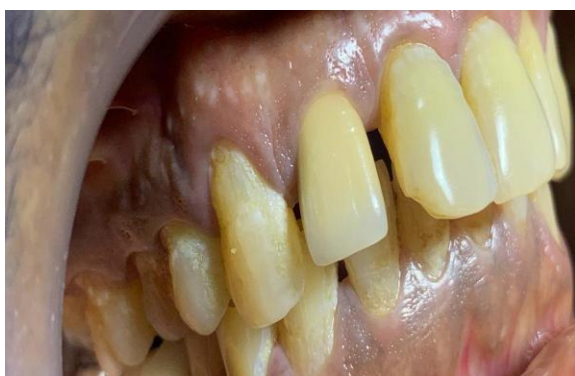

Fig 10. Picture of the Prosthesis placement after 3 months

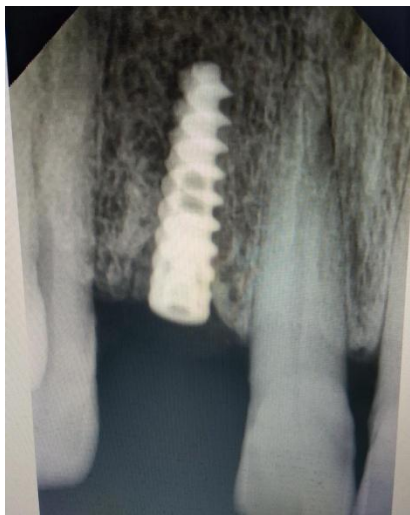


Fig 13. Post operative radiograph

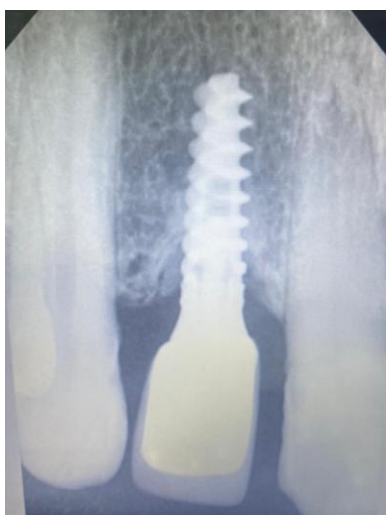

Fig 14. Post operative picture after prosthesis placement

Initial wax pattern (Kronenwachs BEGO , Germany)was fabricated on the diagnostic cast taking support from the occluso-labial half of the adjacent abutment teeth covering only the

facial portion of the edentulous ridge. The height of the pattern in the edentulous site was made in relation to the height of the adjacent abutments (11 and 13).

A crescent shaped cut back on the pattern was made in the proposed implant site that will help to position the initial drill at the centre of the ridge.

The accepted wax pattern was then casted in the centrifugal casting machine. After final finishing and polishing of the custom made metal surgical guide it was tried in the patients mouth for proper fit and stability prior to the implant placement procedure.

Finally the implant was placed with the help of the custom made metal surgical guide which allowed the fixture to be inserted in the desired prosthetically driven position.

DISCUSSION

One of the most challenging aspects of dental implant placement is predictable spatial positioning of the implant in the bone. The growing interest in minimally invasive surgery, together with the possibility of fitting prostheses with immediate function, has led to the development of software capable of planning and manufacturing a surgical guide

and prostheses that can be placed as soon as the surgery has been completed.²

A very recent evaluation of the surgical and prosthetic complications of implant treatment in 12 patients using the guided surgery technique, reported a success rate of 69.5%, together with patient comfort during and after treatment. A study involving 33 patients with edentulous upper maxillae who received implants which were loaded immediately reported a 91.9% success rate after one-year follow up.²

Possible errors can occur in manufacturing surgical guides. In the literature, it has been suggested that modelling of anatomical structures of maxilla and mandible through stereolithography is a technique that can be applied when planning surgery for implants.²

To justify the higher costs of stereolithographic surgical templates and dental volumetric tomography scanning, these methods must provide concrete advantages, such as flapless surgery and/or fabrication of provisional or definitive implant dentures prior to implant surgery. Limited studies show encouraging results, whereas there is controversy about the precision of implant placement exactly in the planned position.³

Smaller deviations were observed with tooth-supported guides, and screw fixation of the guide was recommended to reduce errors. Tooth-supported guides have been reported to show lower angular and linear deviations than bone-supported guides. The lowest deviations were reported for tooth-supported guides in several studies.³

Incorporation of prosthetic planning using a scanographic template allows the treatment to be optimized from a prosthodontics and biomechanical point of view; and the technique promotes flapless surgeries, allows presurgical construction of the master cast and provisional restorations, and facilitates immediate loading. The procedure for fabrication of CAD/CAM-based surgical guides can be divided into the following steps:

1. Fabrication of the radiographic template,
2. The computerized tomography scan,
3. Implant planning using interactive implant surgical planning software, and
4. Fabrication of the stereolithographic drill guide.

The radiographic template must be an exact replica of the desired prosthetic end result, as it allows the clinician to visualize the location of

planned implants from an esthetic and biomechanical standpoint. 4

Many studies have evaluated guided surgery for dental implants. Though the results vary based upon each study design, it has been documented that there are discrepancies between the planned implant location and the actual location of the implant. This should caution the clinician from attempting to place implants through guided surgery when adequate bone is not present to accommodate minor errors. The clinician should avoid trying to 'thread the needle' utilizing guided surgery, as slight deviations might result in perforations. Furthermore, since flapless techniques are commonly utilized for guided surgeries, the clinician is unable to visualize perforations if they do occur. 6

Guided surgery is challenging when the patient has limited mouth opening. Due to the extra height of the metal sleeves and the additional length of the drills used for the osteotomy, it might be difficult for some patients to open wide enough, especially when implants are being placed in the posterior region. Clinicians need to evaluate mouth opening prior to incurring the additional expenses involved in the fabrication of GST. 6

The clinician must understand the limitations and advantages associated with guided surgery so as to apply the benefits of this rapidly evolving technology when appropriately indicated. Bone dimension at the edentulous site, proximity of the planned implant site to vital anatomic structures, cost, need for sophisticated equipment and additional steps, increased accuracy and efficiency are all factors to be considered when selecting the type of surgical template for implant placement. 6

The use of a totally guided template may further minimize access points and angular deviations because of the potential influence of operator positioning errors while using more than one guide or during manual implant placement. 8

Tooth-supported surgical guides are relatively more stable. In Ozan's study they found that the tooth-supported guides were more accurate. Tooth-supported surgical guides may be more accurate than mucosa-supported guides, while partially guided templates can provide the same outcomes as totally guided templates, thus simplifying the surgical procedure. 8

The main drawback of the surgical template can be seen in the possible movement of the template during surgery and reproducibility of

the splint position between the CT exam and surgical procedure.⁹

The degree of the difference between the proposed and actual implant direction may be influenced by various factors, such as the construction accuracy of the template, the surgical accuracy using these templates, the accuracy of the study model, the accuracy of the stereolithographic machines and the measurement accuracy.⁹

The CT scan involves a higher dose/higher cost method. However, the CT scan is less time consuming when multiple implants are required, and it allows imaging of the entire jaw, making it possible to use software for virtual implant placement. As long as radiographic imaging has been enhanced by the development of various techniques, multi-slice, and spiral CT are being replaced by CBCT systems for oral and maxillofacial imaging, enabling a significant reduction dose.⁹

CONCLUSION

Tooth-supported surgical guides may be more accurate than mucosa-supported guides, while partially guided templates can provide the same outcomes as totally guided templates, thus simplifying the surgical procedure.

Implant insertion by using surgical templates are far more superior and precise when compared to free handed implant placement. It helps the clinician to place implants with a correct angulation and occlusal relationship. Moreover selection in the type of the surgical guides depends on the clinicians point of view based on the accuracy , efficiency , cost and the vital anatomic structures.

REFERENCES -

1. A surgical guide for dental implant placement in an edentulous jaw. peter Y.P. Wat , Edmond H. N. Pow et al ; The journal of Prosthetic dentistry ; october 2008 Volume 100, Issue 4, Pages 323–325.
2. A Study of a Custom-Made Surgical Guide for Dental Implant Insertion in Free-End Saddle Sites ; Hasan Ayberk Altug, Metin aencimen, Aydin Gulses ; OHDM - Vol. 10 - No. 3 - September, 2011.
- 3 . Accuracy of three different types of stereolithographic surgical guide in implant placement: an in vitro study. Turbush SK , Turkyilmaz I ; J Prosthet Dent. 2012 Sep;108(3):181-8.
4. Types of Implant Surgical Guides in Dentistry: A Review ; Kathleen Manuela

D'Souza, BDS* Meena Ajay Aras, MDS ;
Journal of Oral Implantology ; Vol.
XXXVIII/No. Five/2012.

5. CAD/CAM Guided Surgery in Implant
Dentistry: A Brief Review T. Kattadiyil, DDS,
MDS, MS; Ewa Parciak, DDS; Shweta Puri,
BDS; Michael D. Scherer, DMD, MS ; Alpha
Omegan | Spring 2014.

6. Accuracy of different types of computer-
aided design/ computer-aided manufacturing
surgical guides for dental implant placement ;
Wei Geng, Changying Liu, Yucheng Su, Jun
Li, Yanmin Zhou . Int J Clin Exp Med
2015;8(6):8442-8449.

7. Overview of surgical guides for implant
therapy ;T Umapathy , Chirenjeevi Jayam , BS
Anila , CP Ashwini ; Journal Of Dental Implant
; Year : 2015 | Volume : 5 | Issue : 1 | Page :
48-52.

8 . A Step toward Precision: A Review on
Surgical Guide Templates for Dental Implants ;
Amrita Pawar , Sangam Mittal , Ricky Pal
Singh , Rabbpreet Bakshi , Varun Sehgal ;
International Journal of Scientific Study |
February 2016 | Vol 3 | Issue 11 .

9. Implant placement accuracy using dynamic
navigation ; Michael S Block , Robert W
Emery et al ; International Journal Of Oral And

Maxillofacial Implant 2016. doi:
10.11607/jomi.5004.

10. Clinical applications and effectiveness of
guided implant surgery: a critical review based
on randomized controlled trials ; Marco
Colombo , Carlo Mangano , Eitan Mijiritsky ,
Mischa Krebs , Uli Hauschild and Thomas
Fortin. Colombo et al. BMC Oral Health (2017)
17:150.