

Case Report

A Diagnostic Paradox of Irritational Fibroma

Vishakha Srivastava¹, Srashti Sharma², Upendra Singh Rathore³, Anshita Shrivastava⁴

^{1,2,3} Post Graduate, Department of periodontology, Peoples Dental Academy, Bhopal, Madhya Pradesh India

⁴Consultant Periodontist, Bhopal, Madhya Pradesh India

ARTICLE INFO



Keywords: Fibroma, Buccal mucosa, Benign lesion

ABSTRACT

Irritation fibroma is reactive hyperplastic outgrowths seen within the mouth because of many factors like chronic irritation by plaque, calculus, overhanging margins, trauma and dental appliances.

Irritation fibroma represents a reactive focal fibrous hyperplasia because of trauma or local irritation.

The aim of this case report is to present the surgical removal of an irritation fibroma by scalpel.

Introduction

A general soft tissue reaction to strain from tooth/teeth or dental prostheses was first reported in 1846 as fibrous polyp and polypus¹. Various terms have been employed in oral pathology to explain a non - neoplastic fibrous lesion of oral mucosa like Irritation Fibroma, Irritational Fibroma, Fibrous Hyperplasia, Focal Fibrous Hyperplasia, Traumatic Fibroma, and Fibro epithelial Polyp². Fibroma, a benign neoplasm of fibroblastic origin, is reactive in nature and represents a reactive hyperplasia of fibrous animal tissue in response to local irritation or trauma instead of being a real neoplasm³. Traumatic or irritation fibroma is that the healed effect of the inflammatory hyperplastic lesion which might occur at any age from almost any soft-tissue site, tongue, gingiva, and buccal mucosa being the foremost common. it's usually characterized by a slow, painless growth accumulated over a period of months or years. (Fig 1, 2). They appear as broad-based lesions, lighter in colour than the encompassing normal tissue, with the surface often appearing white thanks

to hyperkeratosis or with surface ulceration caused by secondary trauma⁴. It is treated by surgical excision, and also the source of irritation must be eliminated. Conservative excisional biopsy is curative and its findings are diagnostic. Recurrences are rare and should be caused by repetitive trauma at the identical site. These lesions don't have a risk for malignancy.

CASE REPORT:

A 45-year-old female patient reported to the Department of Periodontology, People's Dental Academy, Bhopal with the chief complaint of swelling in lower front tooth region for 6 months. The lesion increased in size gradually with no history of bleeding and pain. Intra-oral clinical examination revealed a pedunculated, soft and oedematous in consistency and well-defined growth in relation to 31 41 42 on the lingual side, measuring 4.5 x 4 cm in diameter(fig.3), extending from distal surface of 31 to mesial surface of 42, upper border covers the middle third level of 31,41,42. (Fig.4)

* Corresponding author: Dr. Vishakha Srivastava, Department of periodontology, Peoples Dental Academy, Bhopal, Madhya Pradesh India. Email: drvishakha1624@gmail.com

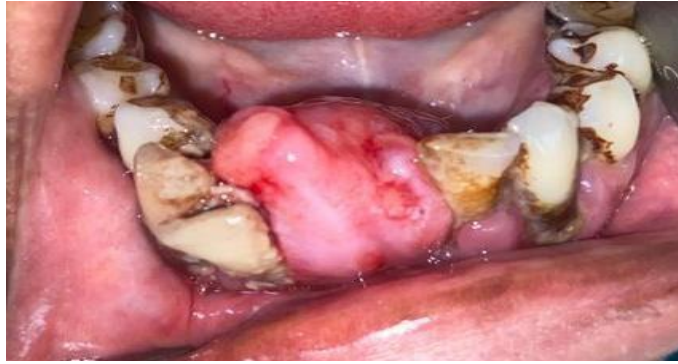

Fig. 1

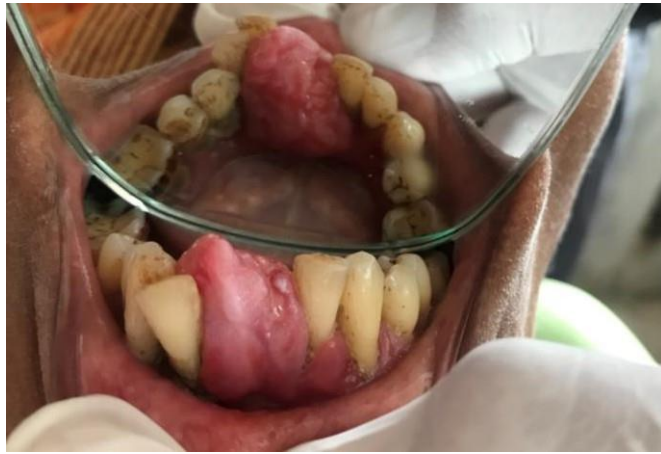

Fig. 2

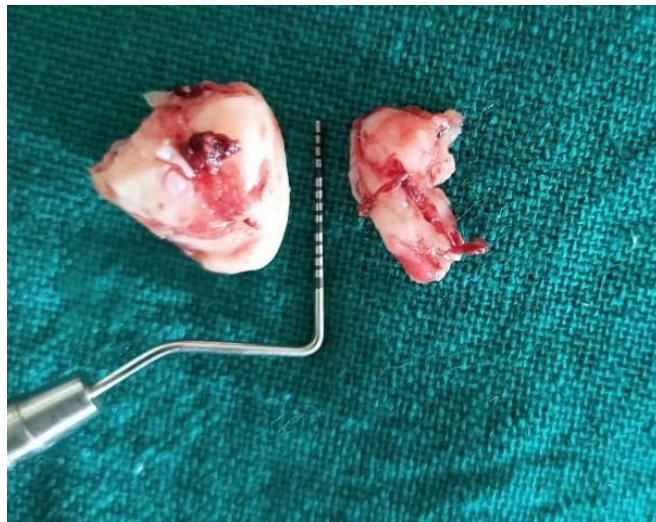

Fig.3

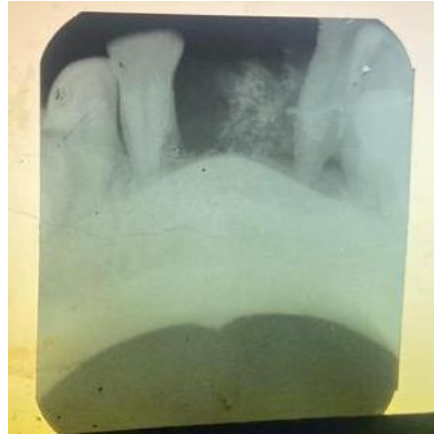

Fig.4

On the basis of histological and clinical evaluation, the provisional diagnosis made was irritation fibroma. Differential diagnosis was suggested as chronic fibrous epulis, traumatic fibroma osteosarcoma and pyogenic granuloma.⁵

A complete haematological investigation, radiograph (IOPA) was included (fig.4). Post-operative photographs after immediate procedure, one week and one month have been mentioned (fig.6,7,8). After that scaling and root planning was done. After phase 1 therapy, surgical excision of the fibroma was done with the use of scalpel. Educated assent was taken, effective sedative specialists (2% lignocaine hydrochloride and 1:80,000. adrenaline) was applied to the careful site and nearby sedative penetration was controlled. After sedation was

discovered to be compelling, extraction of fibroma was finished with the surgical blade. The patient was recalled after 7 days and 1 months, respectively for re-evaluation. Postoperative instructions were given, and antibiotic capsule amoxicillin (500 mg) thrice a day for 5 days and nonsteroidal anti-inflammatory drug paracetamol thrice a day for 3 days were prescribed to prevent postsurgical infection and pain. The postoperative session was uneventful with no delayed haemorrhage. The mucosa was found to be normal in colour and showed no vascular markings. The excised tissue was submitted to the Department of Oral Pathology for histopathological investigations. Based on the history, clinical examination, and histological analysis of biopsy, the case was diagnosed with

Peripheral ossifying fibroma. Histological examination manifested the presence of thin stratified squamous epithelium overlying interface was flat. Connective tissue stroma consisted of dense collagen bundles unorganizly arranged along with presence of blood vessels. Based on these findings, a diagnosis of fibroma was given (Fig5).

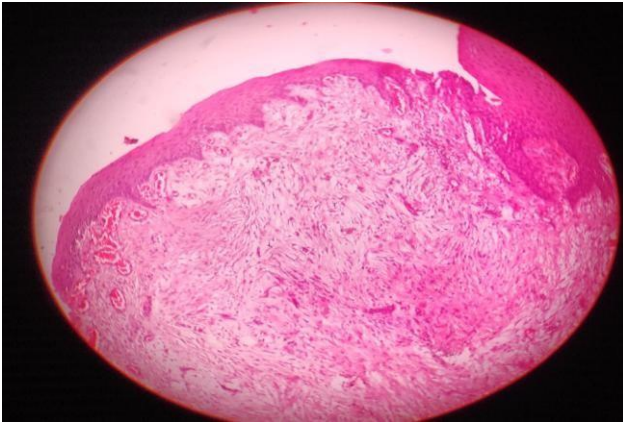


Fig 5

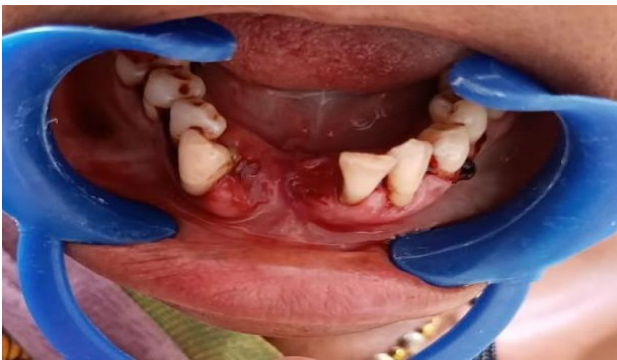

Fig.6

fibrocellular stroma. The epithelium connective tissue

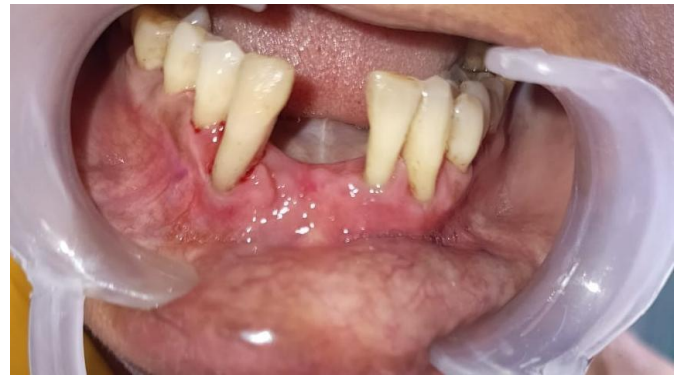

Fig. 7

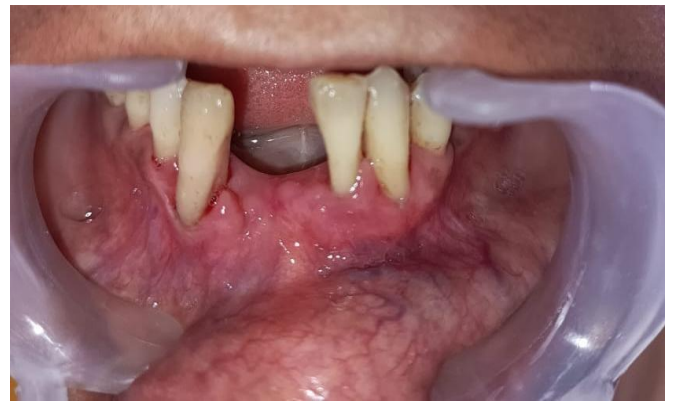

Fig. 8

DISCUSSION

The gingiva might have various types of hyper reactive lesions which occur on such as focal fibrous hyperplasia, pathology tumours, pyogenic granuloma, PGCG, and POF benign tumours. Irritation fibroma is treated by removing the etiological factors, scaling of adjacent teeth, and total surgical excision along with periosteum to minimize the possibility of

recurrence. any irritant which can be seen, such as an ill-fitting denture, root stumps, and rough restoration should be removed⁶⁻⁷.

Histologically stays disputable and there are two ways of thinking to comprehend the histogenesis of irritation fibroma. It might at first create as peripheral fibroma that goes through ensuing stringy development and calcification, that addresses the reformist phase of a similar range of pathosis. Other lesions, which can also arise as a result of irritation because of plaque microorganisms and other local irritants, include pyogenic granuloma, peripheral giant cell granuloma, and peripheral ossifying fibroma. Female predilection and a peak occurrence in the second decade of life suggested hormonal influences⁸. It Commonly occurs in anterior region and buccal mucosa or other sites like gingiva, palate, tongue, lips. It appears as an elevated growth of normal colour with a smooth surface and a sessile or occasionally pedunculated base.

CONCLUSION

Irritation fibroma clinically resembles as pyogenic granuloma, giant cell fibroma myofibroma or odontogenic tumors, so histopathological examination is important for accurate diagnosis. So, it's of importance to differentiate between hyperplasia and neoplasia as neoplasia don't seem to be self-limiting

conditions and long-standing hyperplastic lesions in presence of chronic irritation can get converted to neoplasia. Additionally to the physical characteristics of the lesion, the patient's demographics, presence of associated symptoms, related systemic disorders, and site and growth patterns of the lesion all give clues to adequately diagnose and treat their typical histopathologic architecture⁹.

References:

1. Singh A, Vengal M, Patil V, Sachdeva SK. Traumatic Fibroma A Saga Of Reaction Against Irritation. Dental Impact Vol. 4, Issue 1, June 2012.
2. Jinal D, Krishna D, Gaurav B, Dharmesh V. Traumatic fibroma - A review and report of two cases. Int J Current Res. 2017; 9: 52004-52006.
3. Barker DS, Lucas RB. Localised fibrous overgrowths of the oral mucosa. Br J Oral Surg 1967; 5:86-92.
4. Regezi JA, Sciubba JJ, Jordan RC, Abrahams PH. Oral pathology: Clinical pathologic correlations. Saunders. 2003.6.
5. Tewari N, Mathur VP, Mridha A, Bansal K, Sardana D. 940 nm Diode Laser assisted excision of Peripheral Ossifying Fibroma in a neonate. Laser therapy. 2017;26(1):53-7.

6. Gulati R, Khetarpal S, Ratre MS, Solanki M. Management of massive peripheral ossifying fibroma using diode laser. *Journal of Indian Society of Periodontology*. 2019 Mar;23(2):177-180.
7. Saharan K. "Irritational fibroma of gingiva in a young female: A case report". *J Med, Radiol, Pathol Surg* 2017;4:15-17.
8. Ashish Lanjekar. "An Unusually Large Irritation Fibroma Associated with Gingiva of Lower Left Posterior Teeth Region". *Case Rep Dent* (2016).
9. Hassan SA, Bhetaja S, Aggarwal N, Arora G. Irritation fibroma: A case report. *J Surg Allied Sci* 2019;1(3):66-7