

Review Article**Smile Designing :The Aesthetic Architecture****Prakriti Bhardwaj¹, Devendra Singh²**¹Dental Intern, Chandra Dental College and Hospital, Barabanki, UP, India²Ex- Senior Lecturer, Department of Orthodontics and Dentofacial Orthopedics, Chandra Dental College and Hospital, Barabanki, UP, India

ARTICLE INFO



Keywords: smile, dental esthetics, smile design, cosmetic dentistry, digital smile design

ABSTRACT

Today - due in part to a convergence of trends in tooth whitening. Extreme makeover style television shows and oral care companies spending millions on advertising- the smile has been solidified in the universe as a centerpiece of overall beauty. There is a great demand than ever before for elective, esthetically driven dentistry, which is a major shift from atmosphere of just a few generations ago, when a trip to dentist meant either a cleaning or the resolution of pain. Smile experts dwelling in the ocean retooling, redefining and rejuvenated atmosphere of smile have now added botox(6)(7) as a new tool to enhance the gummy smiles and the facial architecture like the frown lines, crows feet, droopy smiles etc.

Introduction

The search for beauty can be traced to the earliest civilizations; both the Phoenicians (app 800 BC) and Etruscians (app 900 BC) carefully carved animal tusks to simulate the shape, form and hue of natural teeth. It was not until the 18th century that dentistry was recognized as a separate discipline and its various branches were established. This article reviews the various principles that govern the art of smile designing. Facial beauty is based on standard esthetic principles that involve proper alignment, symmetry and proportion of face. Analyzing, evaluating and treatment planning for facial esthetics often involve a multidisciplinary approach which could include orthodontics, orthognathic surgery, periodontal therapy, cosmetic dentistry and plastic surgery.

COMPONENTS OF AESTHETIC SMILE

Harmonizing an esthetics smile requires a perfect integration of facial composition and dental composition. The dental composition relates more specifically to teeth and their relationship to gingival

tissues. A smile design should always include the evaluation and analysis of both facial and dental composition.

FACIAL COMPOSITION: Beauty is based on standard esthetic principles that involve proper alignment, symmetry and proportion of face. Analyzing, evaluating and treatment planning for facial esthetics often involve a multidisciplinary approach which could include orthodontics, orthognathic surgery, periodontal therapy, cosmetic dentistry and plastic surgery. Thus, an esthetic approach to patient care produces the best dental and facial beauty.[2] In classical terms, the horizontal and vertical dimensions for an ideal face are as follows:

1. **Horizontal:**

- The width of the face should be the width of five "eyes".
- The distance between the eyebrow and chin should be equal to the width of the face.

* Corresponding author: Dr. Kanwalpreet Kaur Bhullar Professor and Head, Department of Conservative Dentistry and Endodontics, Sri Guru Ram Das Institute of Dental Science and Research, Amritsar, Punjab, India, 143001. +91- 9815201712

2. **Vertical:** The facial height is divided into three equal parts from the forehead to the eyebrow line, from the eyebrow line to the base of the nose and from the base of the nose to the base of the chin.

DENTAL COMPOSITION

1.Tooth components

- a) Dental midline⁽²⁾
- b) Incisal lengths⁽²⁾
- c) Tooth dimensions⁽³⁾
- d) Zenith points⁽³⁾
- e) Axial inclinations⁽⁴⁾
- f) Interdental contact area (ICA) and point (ICP)⁽⁴⁾
- g) Incisal embrasure⁽⁴⁾
- h) Sex, personality and age⁽⁴⁾
- i) Symmetry and balance⁽⁴⁾

2.Soft tissue components

- a) Gingival health⁽⁵⁾
- b) Gingival levels and harmony⁽⁵⁾
- c)Gingival contouring and Tooth contouring⁽⁵⁾
- d) Interdental embrasure⁽⁵⁾
- e) Smile line⁽⁵⁾

❖ **Dental midline**

- It is parallel to the long axis of the face: the line angle that forms the contact between the centrals should be parallel to the long axis of the face;
- It is perpendicular to the incisal plane: the line angle that forms the contact between the centrals should be perpendicular to the incisal plane
- The maximum allowed discrepancy can be 2 mm.

❖ **Incisal lengths (incisal edge positions)**

Maxillary incisal edge position is the most important determinant in smile creation because it serves as a reference point to decide the proper tooth proportion and gingival levels. The

parameters used to help establish the maxillary incisal edge position are:

Degree of tooth display: When the mouth is relaxed and slightly open, 3.5 mm of the incisal third of the maxillary central incisor should be visible in a young individual. As age increases, the decline in the muscle tonus results in less tooth display.

Phonetics: Phonetics is a major determinant of the tooth length. In order to determine proper lip, tongue and incisal support and tooth position, it is necessary that the patient sits either erect or stands during the phonetic exercises. The various phonetics used are as follows:

- ❖ **Tooth dimensions:** The proportions of the centrals must be esthetically and mathematically correct. The width to length ratio of the centrals should be approximately 4:5 (0.8-1.0); a range for their width of 75-80% of their length is most acceptable. Various guidelines for establishing correct proportions in an esthetically pleasing smile are-

Golden proportion (Lombardi): When viewed from the facial, the width of each anterior tooth is 60% of the width of the adjacent tooth (mathematical ratio being 1.6:1:0.6) [Figure 1]. It is difficult to apply as patients have different arch form, lip anatomy and facial proportions. Strict adherence to golden proportion calculations limits creativity and this may lead to cosmetic failure.

Recurring esthetic dental proportion (Ward): The successive width proportion when viewed from the facial aspect should remain constant as we move posteriorly from midline. This offers great flexibility to match tooth properties with facial proportions [Figure 2].

M proportions (Methot): This method compares the tooth width with the facial width using a software. The whole analysis is done in the computer and hence

involves more of mathematics rather than artistic analysis.[fig3]

Chu's esthetic gauges: Dr. Chu's research supports Levin's RED concept and refutes the golden proportion.

A series of gauges are available to make intraoral analysis which allow for-
fast, simple analysis and diagnosis of tooth width problems, tooth length problems and gingival length discrepancies;
color coding predefines desired tooth proportions, quicker and easier to read than any other instrument;
used as a reference guide between clinician and lab technician, hence reduces the incidences of miscommunications errors.

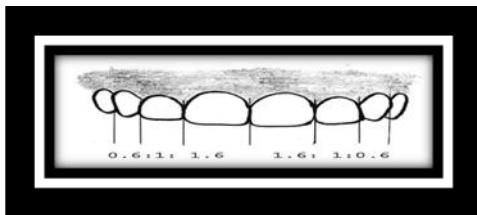


Figure 1: Golden proportion based on apparent width from the frontal view.



Figure 2 : Recurring esthetic dental proportion.

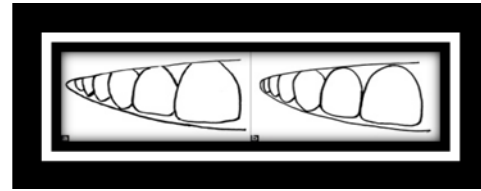


Figure 3: a) Insufficiently developed buccal corridor, b) properly developed buccal corridor

Zenith points : Zenith points are the most apical position of the cervical tooth margin where the gingiva is most scalloped. It is located slightly distal to the vertical line drawn down the center of the tooth. The lateral is an exception as its zenith point may be centrally located^(figure 4). They provide the illusion of bodily movement and reduce exaggerated triangular form and used for analysis of tooth angulation.



Figure 4: Zenith points and its relation to midline

- ❖ **Tooth inclinations** Axial inclination compares the vertical alignment of maxillary teeth, visible in the smile line, to central vertical midline. From the central to the canine, there should be natural, progressive increase in the mesial inclination of each subsequent anterior tooth. It should be least noticeable with the centrals and more pronounced with the laterals and slightly more so with the canines. evaluation of axial

inclination can be done on a photograph of the anterior teeth in a frontal view.

❖ Interdental contact and Point

1. Interproximal contact area (ICA):

- It is defined as the broad zone in which two adjacent teeth touch.
- It follows the 50:40:30 rule in reference to the maxillary central incisor .
- The increasing ICA helps to create the illusion of longer teeth by wider and also extend apically to eliminate black triangles.

2. Interproximal contact point (ICP):

- It is the most incisal aspect if the ICA.
- As a general rule, the ICP moves apically, the further posterior one moves from the midline .

- ❖ Incisal embrasures :The incisal embrasures should display a natural, progressive increase in size or depth from the central to the canine. [Figure 5]. The contact points in their apical progression should mimic the smile line. Failure to provide adequate depth and variation to the incisal embrasure will-make the teeth appear too uniform and make the contact areas too long and impart to the dentition a box like appearance. The individuality of the incisors will be lost if their incisal embrasures are not properly developed.

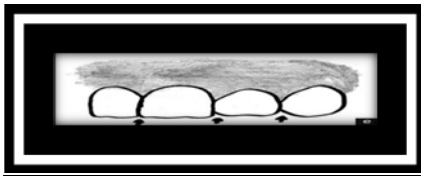


Figure 5: Incisal embrasure - increase in size and depth from central to canine.

- ❖ Sex, Personality and Age.Minor differences in the length, shape and positioning of the maxillary teeth allow for dramatic characterization, example of maxillary teeth -
 - Age - maxillary central incisor Youthful teeth: unworn incisal edge, defined incisal embrasure, low chroma and high value
Aged teeth: shorter; so less smile display, minimal incisal embrasure, high chroma and low value
 - Sex - maxillary incisors
Female form: round smooth, soft delicate
Male form: cuboidal , hard vigorous
 - Personality - maxillary canine
Aggressive, hostile angry: pointed long "fangy" cusp form
Passive, soft: blunt, rounded, short cusp form
- ❖ Symmetry and balance
- ❖ Symmetry is the harmonious arrangement of several elements with respect to each other. Symmetrical length and width is most crucial for the centrals. It becomes less absolute as we move further away from the midline
- ❖ Balance is observed as the eyes move distally from the midline, so that both the right and left sides of the smile are well balanced.
- ◆ Gingival health :The gingiva acts as the frame for the teeth; thus, the final esthetic success of the case is greatly affected by the gingival health. It is of paramount importance that the gingival tissues are in a complete state of health prior to the initiation of any treatment. Healthy gingiva is usually
 1. Coral pink in color, stippled, firm , resilient and, with a knife edged contour

2. located facially - 3 mm above the alveolar crestal bone and
3. located interdentally - 5 mm above the intercrestal bone papilla should be pointed and should fill the gingival embrasure right up to the contact area.

◆ Gingival Contouring and Tooth

Contouring: **Gingival (gum) contouring**, also known as gingival sculpting, is the process of reshaping the gum tissue around your teeth. If gums rest too high or too low on your teeth, and gum contouring surgery may be an option to consider. Also called tissue sculpting or gum reshaping.

Gingival level and harmony: Establishing the correct gingival levels for each individual tooth is the key in the creation of harmonious smile. The cervical gingival height (position or level) of the centrals should be symmetrical. [Figure 6]. The gingival margin of the lateral incisor is 0.5-2.0 mm below that of the central incisors.

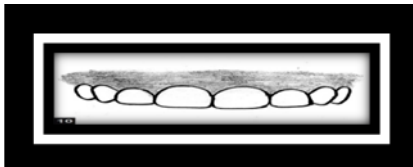


Figure 6: Ideal gingival level - centrals and canines same level and laterals cervical to them,

- ◆ Interdental embrasure (cervical embrasure): The darkness of the oral cavity should not be visible in the interproximal triangle between the gingiva and the contact area. If the most apical point of the restoration is 5 mm or less from the crest of the bone, then black triangles will be avoided. [Figure 7]

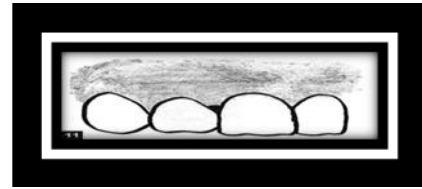


Figure 7 : Ideal gingival level - centrals and canines same level and laterals cervical to them,

- ◆ Smile line: Smile line refers to an imaginary line along the incisal edges of the maxillary anterior teeth which should mimic the curvature of the superior border of the lower lip while smiling. [Figure 8]. Ideally, the gingival margin and the lip line should be congruent or there can be a 1-2 mm display of the gingival tissue. Showing 3-4 mm or more of the gingiva (gummy smile) often requires cosmetic periodontal recontouring to achieve an ideal result.

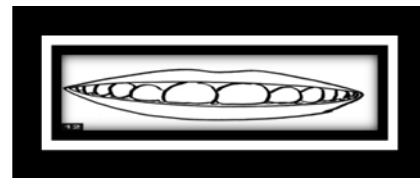


Figure 8: Smile line that follows the superior border of the lower lip

BOTULINUM TOXIN THE MAGICAL SPELL OF DENTISTRY : A CONSERVATIVE APPROACH TO MANAGEMENT OF GUMMY SMILE.

Botulinum (Botox) is an exotoxin procured from the anaerobic bacteria, the clostridium botulinum. Treatment with botox is conservative alternative to the invasive surgical procedures. Botox does not affect the statics of smile (e.g. lip length), only the smile dynamics (e.g. muscle activity on smile) .The use of botox is

appropriate in case of hypercontraction of elevator muscle of upper lip determined by the elimination of other etiologies. The botox molecules act at nerve terminals and prevents the release of acetylcholine by cleaving SNAP-25, which leads to muscle relaxation. When compared to other surgical procedures Botulinum Toxin provides effective, minimally invasive, temporary treatment of gummy smile for patients with hypermobile upper lip, which can be repeated if the patients like the aesthetic improvement achieved. Causes of gummy smile include; sex predilection, hyperfunctional, musculature and lip incompetence, altered passive eruption, skeletal disharmonies.

A non-surgical choice for reducing excessive gingival show offer appealing treatment for specific patients. Botox have been utilized as a part of solution since the 1970s for treating excessive muscular contraction and in aesthetic medicine for treating facial agony and migraines. Since 1987 its utilization has expanded significantly in correcting facial ageing.

TREATMENT FOR GUMMY SMILE

<u>Altered passive eruption</u>	Gingivectomy, Crown lengthening
<u>Altered passive eruption</u>	Apical reduction of the entire dentogingival complex with or without osseous reduction
<u>Skeletal Disharmonies</u>	Orthodontic treatment, orthognathic surgery,
<u>Hyperfunctional Musculature and Lip Incompetence</u>	Muscle resection, anterior nasal spine implant and Botulinum toxin

Mode of Action: This toxin acts by preventing the release of acetylcholine from presynaptic vesicles at the neuromuscular junction resulting in an inhibition of muscular contraction. Therapeutic effects of Botulinum toxin, first appear in 1 to 3 days, peak in 1 to 4 weeks, and decline after 3 to 4 months, after which sprouting of new axon terminals results in a return of neuromuscular function. Therefore, Botulinum toxin injections are needed to be administered 2-3 times a year.

Contraindication.

- patient with unrealistic expectations.
- Dependent on intact facial movements and expressions for their livelihood (e.g. actors, singers, musicians and other media personalities).
- Afflicted with a neuromuscular disorder (e.g. myasthenia gravis, Eaton-Lambert syndrome).
- Allergic to any of the components.
- drug interaction (e.g. aminoglycosides, penicillamine, quinine, and calcium blockers).
- Pregnant or lactating (category C drugs).

CONCLUSION :Timeless human esthetics implies a sense of beauty, a pleasing impulse, naturalness, and a youthful appearance relative to one’s age. Cosmetic means to do **“something superficial to cover a defect or deficiency” and secondarily “serving to beautify the body.”** The second part of this definition has a very large cultural component to this, ie, beauty is in the eye of the beholder. According to the Merriam-Webster dictionary, the definition of esthetics, on the other hand, is “responsive to or appreciative of what is pleasurable to the senses” or “pleasing in appearance.” Thus, cosmetics and esthetics are somewhat inseparably intertwined, but esthetics also encompasses appearances that do not have a “cosmetic appearance.” This article historically accepted smile design concepts and present research of smile parameters that will help the reader to design their esthetic treatments. It is very important to note **that smile design concepts have been presented in a very static manner, ie, specific measurements for form, color, and position of esthetic dental elements.**

References

1. Aschheim KW, Dale BG. Esthetic Dentistry - A clinical approach to techniques and materials. Dawson PE. Determining the determinants of occlusion. Int J Periodontics Restorative Dent 1983;3:8-Kokich VO Jr, Kiyak HA, Shapiro PA. Comparing the perception of Dentist and Lay people to altered Dental Esthetics. J Esthet Dent 1999;11:311-24.
2. Goldstein RE. Change your smile. Chicago, US : Quintessence Publication; 1997.
3. Davis NC. Smile Design. Dent Clin N Am 2007;51:299-318.
4. Lavere AM. Denture tooth selection: An analysis of the natural maxillary central incisor compared to the length and width of the face. Part I. J. Prosthet Dent 1992;67:661-3.
5. Bukhary SM, Gill DS, Tredwin CJ, Moles DR. The influence of varying maxillary lateral incisor dimensions on perceived esthetic smile. Br Dent J 2007;203:687-93.
6. Fradeani M. Evaluation of dentolabial parameters as part of a comprehensive esthetic analysis. Eur J Esthet Dent 2006;1:62-9.
7. Kokich VG, Spear FM, Kokich VO. Maximizing anterior esthetics: An interdisciplinary approach. Esthetics and Orthodontics. In: McNamara JA, editor. Carionafacial Growth Series, Centre for Growth and Development. Ann Arbor: University of Michigan; 2001.
8. Paul SJ. Smile analysis and face bow transfer: Enhancing esthetic restorative treatment. Pract Proced Aesthet Dent 2001;13:217-22.
9. https://www.researchgate.net/publication/317546810_Botulinum_Toxin_for_the_Treatment_of_Gummy_Smile.
10. https://www.academia.edu/37061900/Botox_the_magical_spell_of_dentistry_A_literature_review.