

## Case Report

### Rehabilitation of Malaligned Anterior Teeth with Porcelain Laminate Veneers - A Case Report

Aman Singhal<sup>1</sup>, Naveen S Yadav<sup>2</sup>, Kirti Somkuwar<sup>3</sup>, Puja Hazari<sup>4</sup>, Allan Joseph<sup>5</sup>, Avinash Chaurasia<sup>6</sup>

<sup>1</sup> Post graduate final year, Department of Prosthodontics, Peoples Dental Academy, Bhopal, Madhya Pradesh, India

<sup>2</sup> Professor and Head of Department of Prosthodontics, Peoples Dental Academy, Bhopal, Madhya Pradesh, India.

<sup>3</sup> Reader, Department of Prosthodontics, Peoples Dental Academy, Bhopal, Madhya Pradesh, India.

<sup>4</sup> Professor, Department of Prosthodontics, Peoples Dental Academy, Bhopal, Madhya Pradesh, India.

<sup>5</sup> Post graduate Second year, Department of Prosthodontics, Peoples Dental Academy, Bhopal, Madhya Pradesh, India.

<sup>6</sup> Post graduate First year, Department of Prosthodontics, Peoples Dental Academy, Bhopal, Madhya Pradesh, India

#### ARTICLE INFO



Keywords: Smile design, Veneers, Lithium disilicate

#### ABSTRACT

Aesthetic rehabilitation requires proper dental technique and knowledge of biometric principles to provide successful outcome. The porcelain laminate veneers have shown promising results with malaligned anterior teeth. Laminate veneers are minimally invasive and highly esthetic treatment. This case report describes the esthetic treatment of proclined and spaced upper anterior teeth.

#### Introduction

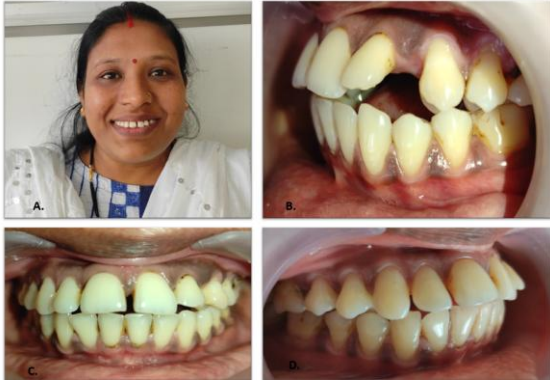Oral In this modern world patients are more esthetically conscious. Dentist should have thorough knowledge of principles of smile designing. With changing era people seeking dental intervention for esthetic purposes has tremendously increased. Smile lines are described as hypothetical lines drawn along the edges of the four maxillary anterior teeth which run parallel to curvature of the inner border of the lower lip<sup>1</sup>. By definition Porcelain laminate veneer is a thin, bonded ceramic restoration that restores the facial, incisal, and part of the proximal surfaces of teeth requiring esthetic restoration<sup>2</sup>. Porcelain laminate veneers are one of the most successful treatment modality for cosmetic improvement of unsightly anterior teeth<sup>3</sup>.

#### Case report-

A female of age 37 years reported in Department Of Prosthodontics, Peoples Dental Academy with chief complain of unpleasant smile with yellowish teeth and spaces between teeth. A thorough clinical examination was performed for analysis and treatment planning. Intraoral and extra oral photographs and diagnostic impressions were taken consecutively.

Mock preparation and diagnostic wax-up was done on the prepared model. After getting concern from patient, treatment was started. It was planned to provide Veneers (Emax) with Maxillary Right central incisor (11), Right lateral incisor (12), Right Canine(13), Left central incisor

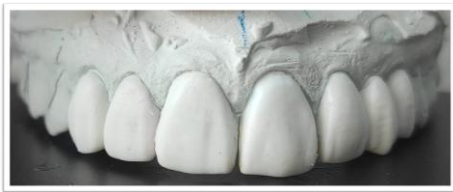\* Corresponding author: Dr. Aman Singhal, Department of Prosthodontics, Peoples Dental Academy, Bhopal, Madhya Pradesh, India. Email- dramansinghal@hotmail.com



**Photograph 1-** A. Extraoral Front View , B. Intraoral left lateral view, C. Intraoral front view, D. Intraoral right lateral view.

(21) tooth and all ceramic bridge with Left lateral incisor(22), missing left canine (x), left 1<sup>st</sup> premolar(24) teeth. Since left lateral incisor was more labially placed root canal treatment was done for the correction of the same.

Before starting the procedure Putty index was made using condensation silicone (Zhermack Zetaplus) on diagnostic wax-up for fabrication of temporary restorations.

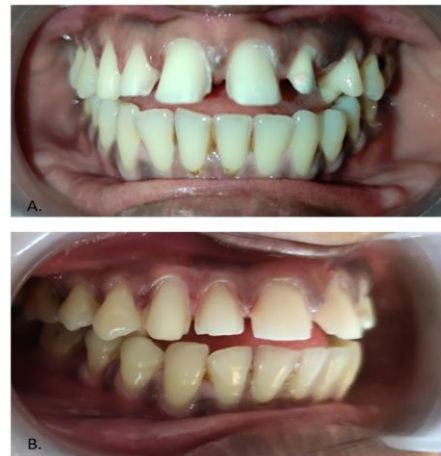

**Photograph 2-** Mock waxup from Right canine to Left 1<sup>st</sup> premolar

Teeth were prepared for Veneer on Maxillary Right central incisor (11), Right lateral incisor (12), Right Canine(13), Left central incisor (21) tooth and all ceramic bridge with Left lateral incisor(22), missing left canine (x), left 1<sup>st</sup> premolar(24).

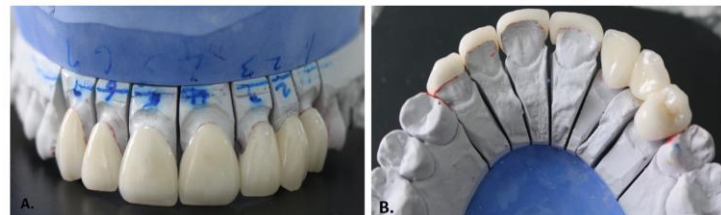
Veneer preparation: First using 0.5mm depth cutting bur (shofu) depth grooves were made on the teeth, followed

by leveling according to those grooves. Chamfer finish line was given interproximal and incisal reduction was done. A palatal wrap was created to provide proper emergence profile. All ceramic crown preparation was done with 22 and 24, more labial reduction was done with 22 as it was more labially proclined.



**Photograph 3- A&B.** Teeth Preparation

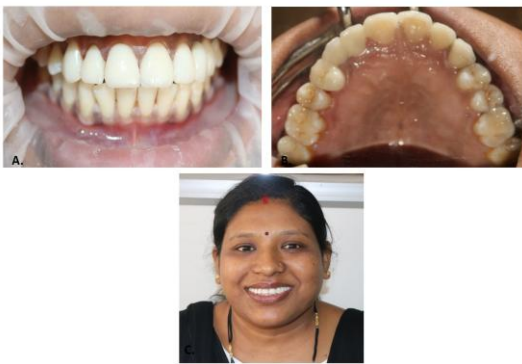Gingival retraction with (3M ESPE) gingival retraction paste was used to retract the gingiva. Retraction paste was completely removed by air water spray. Two-step Putty Impressions with addition silicone and light body (GC FLEXCEED) were made. Impressions were sent to laboratory. Lithium disilicate (Emax) veneers and a 3 unit FPD were fabricated.



**Photograph 4-** Received Lab work of Lithium disilicate Veneers and Bridge. A. Front view, B. Lingual view.

Try in was done in patient by using Clear try in paste (3M ESPE). Then intaglio surface of veneers and Fixed Partial Denture were etched with hydrofluoric acid for 10 seconds and rinsed thoroughly and teeth were dried.

Then 37% phosphoric acid was used for acid etching on tooth for 15-20 seconds, after which it was coated with Bonding agent (3M ESPE Single Bond Universal Adhesive) applied on teeth as well as on the veneers and FPD. A clear light cure resin (3M ESPE RELYX™ VENEER) veneer cement was used to lute the veneers and light cured with light curing gun (Blue-phase N Ivoclar Vivadent). Clear Light cure resin cement (3M ESPE RELYX™ ULTIMATE) was used to lute the Fixed partial denture. Tack curing was done and excess material from the margins was removed and full cycle light curing was done for 10s on each tooth. Post-operative intraoral and extra oral photographs were taken and follow up were done.



Photograph 5- Final Cementation of Lithium Disilicate Veneers on 11,12,13,21 and Lithium Disilicate bridge on 22, x,24. **A.** Intraoral front view, **B.** Palatal view. **C.** Extraoral front view.

### Discussion-

Smile designing requires an integration of the facial and the dental composition, Smile designing requires an integration of the facial and the dental composition, Smile designing requires an integration of the facial and the dental composition, Smile designing requires an integration of the facial and the dental aspects. Smile design depends on various factors like case selection treatment planning, proper tooth preparation and proper

use of adhesive cements<sup>4</sup>. Esthetic dentistry is not only to restore the aesthetics but to provide a restoration that provides the functional, biological and mechanical integrity<sup>4</sup>. Among various finish line, Chamfer finish line is preferred for all the gingival margins. It has advantages of preserving tooth structure, better esthetics, better emergence profile, and decrease stress concentration<sup>5</sup>. The veneers were fabricated from Lithium Disilicate ceramic in this case which have high translucency and strength when compared to low fusing feldspathic porcelain<sup>6</sup>.

### Conclusion-

The Smile designed on based principles and proportions of esthetic dentistry archives harmonious relationship with patient face and soft tissue. In today's world it is very important for a dentist to have updated knowledge and skills to provide best treatment to patient.

### Declaration of patient consent

The authors certify that they have obtained all appropriate patient consent forms. In the form the patient(s) has/have given his/her/their consent for his/her/their images and other clinical information to be reported in the journal. The patients understand that their names and initials will not be published and due efforts will be made to conceal their identity, but anonymity cannot be guaranteed.

1. Sarver DM, Ackerman MB. Dynamic smile visualization and quantification: Part 2. Smile analysis and treatment strategies. *Am J Orthod Dentofacial Orthop.* 2003 Aug;124(2):116–27.
2. Glossary of prosthodontic terms -9<sup>th</sup> edition
3. Gupta DR, Luthra DR, Kukreja DS. Designing a smile: A case report. *International Journal of Applied Dental Sciences.* 2017 Jun;2:146-9.

4. Radz GM. Minimum thickness anterior porcelain restorations. Dent Clin.North Am.
5. Gürel G. Porcelain Laminate Veneers: Minimal Tooth Preparation by Design. Dent Clin North Am. 2007 Apr;51(2):419–31.
6. Beier US, Kapferer I, Burtscher D, Dumfahrt H. Clinical performance of porcelain laminate veneers for up to 20 years.Int J Prosthodont. 2012;25(1):79–85.