

## **Case Report**

### **Root resection of maxillary left second molar : A case report & review of literature**

**Shilpa Shah<sup>1</sup>, Setu P. Shah<sup>2</sup>, Nishtha Patel<sup>3</sup>, Karna Jani<sup>4</sup>**

<sup>1,3</sup>Professor, Department of endodontics

<sup>2</sup>Reader, Department of oral and maxillofacial surgery,

<sup>4</sup>Sr. Lecturer, Department of endodontics,

College of dental sciences and research centre, Manipur, Ahmedabad, Gujarat, India.

#### ARTICLE INFO



Keywords: Root resection, root amputation, furcation, endodontic therapy, periodontitis.

#### ABSTRACT

The increased desire of patients to maintain their dentition has forced dental specialist to conserve the teeth in the mouth which are planned to be removed. In the light of this finding, it is known that periodontally compromised teeth with severe bone loss at furcation area or endodontically compromised teeth may well be retained of their roots. This type of surgical therapy enables clinicians to better access the remaining tooth structure for periodontal and subsequent prosthetic therapy. In this case report palatal root resection of the maxillary left second molar with a simple procedure is presented along with a brief review of root resection as a treatment modality.

#### INTRODUCTION

Root resection a process by which one or more of the roots of a tooth are removed at the level of the furcation while leaving the crown and remaining roots in function<sup>1</sup>. Proper maintenance of molar teeth becomes problematic if apical migration of osseous supporting structures occurs which allows bacterial invasion in the furcation area. Undeniably, untreated furcated molars will lead predictably to more bone loss.<sup>2</sup> Root resection has been performed in dentistry since the late 1800s.<sup>3</sup> With proper long-term monitoring and maintenance, a root resection is accepted as a valid treatment with reasonable long-term effectiveness.<sup>4</sup> Root-resection therapy is a treatment option for molars with periodontal, endodontic, restorative or prosthetic problems.<sup>5</sup>

#### Case report :-

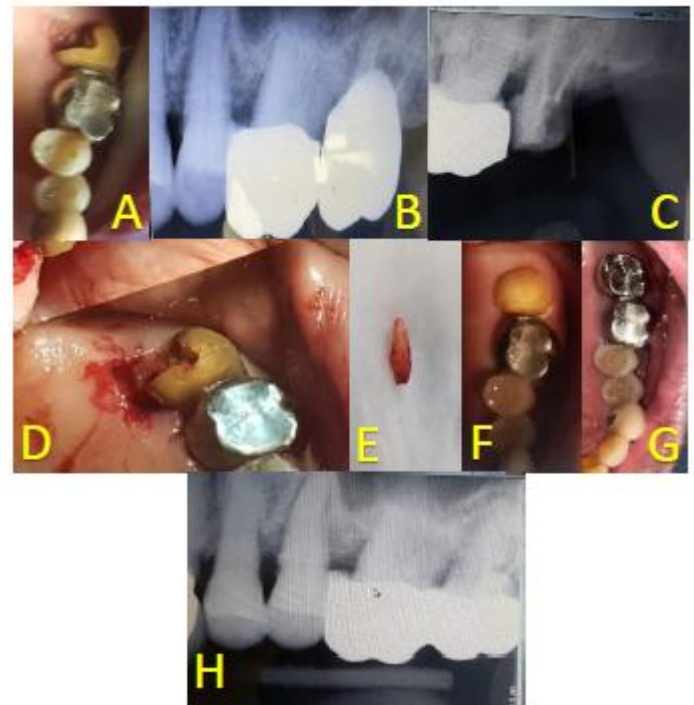
A 73 year old patient reported to a private dental clinic in Ahmedabad, Gujarat, with the complain of throbbing pain and pus discharge in upper left posterior region of jaw since last 1-2 months. Patient gave history of swelling with respect to maxillary left second molar. Complete medical history of the patient was obtained and found non-contributory. Intra oral examination showed generalized moderate periodontal pockets and dislodgement of previous restoration from maxillary left second molar. (Fig. 1A) Intra-oral periapical radiograph (IOPA) showed bone loss with palatal root of maxillary left second molar with furcation involvement. (Fig. 1B) Since mesio-buccal and disto-buccal root showed adequate bone support it was decided to retain these roots and remove the palatal root. Treatment plan and postoperative consequences were explained to the patient. An informed written consent was obtained following which the patient was scheduled for a

\* Corresponding author: **Dr. Setu P. Shah**, 202, Dev aryan appt., Thakore park soc., New vikas gruh road, Mahalaxmi, Paldi, Ahmedabad-380007. Phone: 097230-20772 Email : drshahsetu206@gmail.com

subsequent appointment. To begin with, a thorough phase I therapy was performed and surrounding tissue was assessed. With the adjunct use of antibiotics and anti-inflammatory during the phase I therapy, local infection and inflammation was controlled. Re-endodontic treatment was completed in frequent visits. (Fig. 1C)

Prophylactic antibiotics started 24 hours before the procedure to prevent infection, possible resorptive process and post-operative pain. The procedure was started by asking the patient to rinse with Betadine gargles (Kavy labs Ltd., India) and proper schedule of surgical disinfection was followed. 2% lignocaine hydrochloride (Lignox 2%, Indoco-Remedies Ltd., India) was administered to anesthetize posterior superior alveolar and greater palatine nerves. After appropriate local anesthesia, palatal full thickness mucoperiosteal flap was elevated. (Fig. 1D) A removal of a small amount of palatal bone was done to get access for root elevation, removal and root planning procedures. A cut was then directed just apical to the cemento-enamel junction of the tooth. This cut was made with a high-speed tapered fissure carbide bur. A curved periodontal explorer was used to aid in orienting the angle of the resection. The sectioned area was evaluated using a fine explorer. The palatal root was extracted from the socket (Fig. 1E), furcation area was trimmed for bony spicules and area was inspected for any periodontal irritation. Glass ionomer restoration (Fuji IX, GC, Europe), was used to seal the pulp chamber at the furcation area. The remaining roots were planned. The socket was irrigated with saline and betadine and the tooth was checked for occlusion to facilitate healing. The flap was repositioned and secured with 3-0 black silk interrupted suture (Sutures India Pvt Ltd; India). All routine post-extraction

instructions were given. The patient was instructed to have soft, semi-solid diet. Post-operative antibiotics and analgesics were continued for next 4 days. Sutures were removed after 7 days, healing was found to be satisfactory. After one month of the procedure tooth preparation was done for the metal prosthesis. (Fig. 1F) The patient was periodically evaluated for prognosis and post endodontic restoration was given. Metal prosthesis was given after 1 month and patient was recalled after 3 months, 6 months and 1 year. (Fig. 1G and 1H) No pain, swelling or tooth mobility were observed on subsequent visits.



**Fig. 1:-** Step wise procedure. (A) Pre-operative clinical photograph. (B). Pre-operative IOPA. (C). After repeat endodontic treatment in buccal roots. (D). After removal of palatal root. (E). Palatal root. (F). One month after the procedure. (G). One year after cementation of prosthesis. (G). One year post-operative IOPA after cementation of prosthesis.

**Discussion :-**

Aging of the dental tissue:-<sup>22</sup>

**ENAMEL**

The enamel of our teeth endures both chemical and morphological changes through the years. These tissues become less hydrated and experiences superficial increases in fluoride content with age, especially with the uses of dentifrice and tap water. Thickness of the enamel does change overtime, especially on the facial, proximal contacts, and incisal and occlusal surfaces due to the many chewing cycles and cleaning with abrasive dentifrices.

**DENTIN**

The volume of dentin increases through the continuous apposition of secondary dentin on the walls of the pulpal chamber. Aged dentin is more brittle, less soluble, less permeable, and darker than it was earlier in life. There is formation of tertiary dentin in response to trauma, caries or any irritation. Thus the dentinal changes are:-

- Increased peritubular dentin
- Increased dentinal sclerosis
- Increased number of dead tracts
- Decreased tubular permeability
- Increased reparative and secondary dentin formation
- Yellowish discoloration of dentin.

**PULP SPACE**

The size of the pulp chamber and volume of the pulpal tissue decreases with reparative and secondary dentin formation. The odontoblastic layer surrounding the pulp changes progressively from a multilayer organization of active columnar cells to a single layer of relatively inactive cuboidal cells. Calcification of the root canals increases with age, and the cementum volume within the

alveolus increases gradually overtime, notably in the apical and periapical areas.

**Age changes in the Pulp**

- Decreased cells
- Increased collagen fibers (fibrosis)
- Receding pulp horns
- Small volume of pulp space
- Calcifications
- Decrease in pulpal nerves and blood vessels
- Decreased pulpal healing capacity
- Disappearance of odontoblasts in pulpal floor areas especially in bifurcation and trifurcation.

**ROOTS**

- Increased cementum deposition at root apex
- Calcification of root canals.<sup>22</sup>

With above mentioned age changes in tooth structures with advancing age, chances of root fractures are higher

Root resection procedure have long been used as a treatment modality in various clinical situations involving multirooted teeth.<sup>6</sup> Marshall-Day et al. in 1955, also reported a rise in tooth mortality after age 40, and the maxillary and mandibular molars were the earliest lost teeth.<sup>7</sup> An early study by Marshall-Day and Skourie in 1949, on radiographic examinations of 568 subjects in India, ages 9 to 60 years old, concluded that the mandibular incisors and molars appeared to be most susceptible to osseous loss.<sup>8</sup> According to Eastman and Backmeyer in 1986, this approach can be performed for endodontic, prosthetic and periodontal reasons, the latter accounting for 87% of the indications.<sup>9</sup> It is reported that furcation involvement occurs three times more frequently among maxillary than mandibular molars.<sup>10</sup>

In 1894, Dr. W J. Younger while addressing the meeting of the American Medical Association on “Pyorrhea alveolaris” had said about the hopelessly involved roots of molar teeth. He suggested that treatment in these cases has been to open into these roots, remove their pulps, fill them and amputate (the involved root, then grind away enough of the articulating surface of the crown, immediately over the removal root, in order to bring the pressure in the effort of mastication upon the (solid) roots. By these means, these teeth can be made comfortable and serviceable for years.<sup>11</sup> In 1930, Coolidge emphasized the importance of a well sealed root canal prior to resection.<sup>5</sup> Later, Sommer in 2002, elaborated on the essentials for successful root resection and the role of proper root canal therapy in decreasing organisms and infection prior to root resection.<sup>11</sup>

Grossman in 2004, referred to root amputation as dental proof of the old age that half a better than none. Root amputation and hemi-section procedures were reported in the literature years ago.<sup>12</sup> Early in 1960’s, the therapy involving root amputation was right on the cutting edge in periodontics and endodontics. Hiatt and Amen contributed in the quest for salvaging teeth by comprehensively describing the indications and techniques for root amputation.<sup>13</sup> In reality, G. V. Black described almost the same methods in the nineteenth century and by Sharp in 1920.<sup>14</sup> Farrar in 1884 said that Root resection is one of the accepted surgical treatments for selected furcated molar teeth. A major complication for the successful management of furcated molars by either the periodontist or the patient is the complex anatomy of the inter-radicular aspect of the roots.<sup>15</sup>

Bower in 1979, microscopically examined the furcations of extracted maxillary and mandibular molars. A random sample of first permanent molar teeth (114 maxillary and 103 mandibular teeth) were sectioned at right angles to

the long axis at a level 2 mm apical to the most apical root division, and then examined using a dissection microscope. Maxillary first molars were concave in 94% of mesio-buccal roots, 31% of disto-buccal roots, and 17% of palatal roots, and the deepest concavity was on the inter-radicular aspect of the mesio-buccal root; mandibular first molars were concave in 100% of mesial roots and 99% of distal roots, and the deeper concavity was found in the mesial root rather than the distal root.<sup>16</sup> Everett in 1958, described another anatomic feature of molar teeth that complicates optimal plaque removal - the bifurcation ridge. This structure is located at the junction between the fluting on the radicular and apical surfaces of the root trunk.<sup>17</sup> Root resection is very technique sensitive and complex, so proper case selection is essential.<sup>18</sup>

Root separation or resection has been used successfully to retain teeth with furcation involvement. However, there are few disadvantages associated with it. As with any surgical procedure, it can cause pain and anxiety. Root surfaces that are reshaped by grinding in the furcation or at the site of hemi-section are more susceptible to caries. Often a favorable result may be negated by decay after treatment. Failure of endodontic therapy due to any reason will cause failure of the procedure. In addition, when the tooth has lost part of its root support, it will require a restoration to permit it to function independently or to serve as an abutment for a splint or bridge. Unfortunately, a restoration can contribute to periodontal destruction, if the margins are defective or if non-occlusal surfaces do not have physiologic form. Also, an improperly shaped occlusal contact area may convert acceptable forces into destructive forces and predispose the tooth to trauma from occlusion and ultimate failure of root separation and resection.<sup>19</sup> To achieve good results in periodontally

diseased molars, > 50% bone support of the remaining roots at the time of the root resection is an important factor.<sup>20</sup> Periodontal problems around resected molars have a tendency to recur and should be maintained through meticulous supportive periodontal treatment. In addition, a careful prosthetic plan should be designed to avoid a fracture of resected molars related to biomechanical impairment.<sup>21</sup>

### Conclusion :-

Root-resection therapy is still a valid treatment option for molars with furcation involvement. Root resection to treat periodontal problems showed a better prognosis than root resection performed for non-periodontal purposes. Root resection should be determined to retain and not remove the natural teeth. Also, medically compromised patients may benefit from the maintenance of existing roots, avoiding multiple reconstructive surgical procedures.

### References :-

1. Park SY, Shin SY, Yang SM, Kye SB. Factors influencing the outcome of root-resection therapy in molars: A 10-year retrospective study. *J Periodontol* 2009;80:32-40.
2. Sahoo S, Sethi K, Kumar P, Bansal A. Management of periodontal furcation defects employing molar bisection : A case report with review of the literature. *Dental Hypotheses* 2013;4(3):1-5.
3. Amen C. Hemisection and root amputation. *Periodontics* 1966;4:197.
4. Buhler H. Evaluation of root resected teeth. Results after 10 years. *J periodontal*.1988;59:805-10.
5. Mantri V, Maria R, Kamat S, Raut AW. Root amputation: Case Reports and review. *Endodontology*. 2013;25(2):89-96.
6. Green EN. Hemisection and root amputation. *J Am Dent Assoc* 1986;112:511-8.
7. Marshall-Day CD, Skourie KL. A roentgenographic survey of periodontal disease in India. *J Am Dent Assoc* 1949;39:572.
8. Marshall-Day CD, Septhens RG, Quigley L. Periodontal disease : Prevalence and incidence. *J Periodontol* 1955;26:185.
9. Eastman JR, Backmeyer J. A review of the periodontal, endodontic and prosthetic considerations in odontogenous resection procedures. *Int J Periodontics Restorative Dent* 1986;6(2):34.
10. Majzoub Z, Kon S. Tooth morphology following root resection procedures in maxillary first molars. *J Periodontol* 1992;63:290-6.
11. John I Ingle, Leif K Bakland. Ingle's Endodontics, 5<sup>th</sup> edition; B. C. Decker Inc. 2002:722-7.
12. Franklin S. Weine. Endodontic therapy, 6<sup>th</sup> edition; Mosby Inc. 2004:423-51.
13. Dalkiz M. Bicuspidization : A Case Report. *Gulhane Medial Journal* 2008;50(1):42-5.
14. Parmar G, Vashi P. Hemisection : A case report and review. *Endodontology* 2003;15:26-9.
15. Farrar JM. Radical and heroic treatment of alveolar abscess by amputation of roots of teeth. *Dental Cosmos* 1884;26:79.
16. Bower R. Furcation morphology relative to periodontal treatment. *J Periodontol* 1979;50:366-74.
17. Everett FB. The intermediate bifurcational ridge : A study of the morphology of the bifurcation

- of the lower first molar. *J Dent Res* 1958;37:162.
18. De Sanctis M, Murphy KG. The role of resective periodontal surgery in the treatment of furcation defects. *Periodntal* 2000;22:154-68.
  19. Kinsel RP, Lamb RE. The treatment dilemma of the furcated molar: root resection versus single-tooth implant restoration. A literature review. *Int J Oral Maxillofac Implants*.1998;13:322-32.
  20. Butt N, Talwar S. Root resection in maxillary molar with a retained fractured instrument and periodontal defect. *Indian J Dent Adv* 2014;6(2):1546-9.
  21. Javali MA, Safeena, Ayesha H. Root resection of maxillary first molar : A case report. *Heal talk* 2012;4(4):20-1.
  22. Santosh Kumar Singh, Aruna Kanaparthi, Rosiahh Kanaparthi, Ajay Pillai, Garima Sandhu. Geriatric Endodontics. *Journal of Orofacial Research*, July-September 2013;3(3):191-196