

Original Research

Accuracy of Intraoral Periapical Radiograph grid film overlaying Radiovisiography Sensor for measuring vertical linear dimensions in comparison with Cone Beam Computed Tomography for use in ideal implant cases: An observational comparative study

Vaidya Aayushi K¹, Ronad Sunil², Gandhewar Mahesh A³, Nagara Suresh M⁴, Girija Dodamani⁵, Yogita Zope⁶

¹BDS, (Perusing masters in Prosthodontics, II year PG MDS), ACPM Dental College, Dhule, Maharashtra, India

²MDS Prosthodontics, Reader, Dept. of Prosthodontics, ACPM Dental College, Dhule, Maharashtra, India

³MDS Prosthodontics, Professor and Head of Department (HOD), Dept. of Prosthodontics, ACPM Dental College, Dhule, Maharashtra, India

⁴MDS Prosthodontics, Professor, Dept. of Prosthodontics, ACPM Dental College, Dhule, Maharashtra, India

⁵MDS Prosthodontics, Reader, Dept. of Prosthodontics, ACPM Dental College, Dhule, Maharashtra, India

⁶MDS Oral Medicine and Radiology, Senior Lecturer, Dept. of Oral Medicine and Radiology, ACPM Dental College, Dhule, Maharashtra, India

ARTICLE INFO



Keywords:

Accuracy, Cone Beam Computed Tomography, Dental Radiovisiography, Grid

ABSTRACT

Background: Radiographic assessment is crucial for treatment planning and during intraoperative procedures in implant dentistry. A wide array of modern imaging tools is available. However, they pose a concern about their affordability, availability and radiation exposure. Radiovisiography yields a high-resolution planar image of a localized region. But Radiovisiography software grids fail to consider errors due to projection geometry. In this study accuracy of Intraoral Periapical grid film overlaying RadioVisiography sensor is estimated by comparing with Cone Beam Computed Tomography.

Material and Method: Group A comprised of Intraoral Periapical radiographs obtained by superimposing Radiovisiography sensors with grid film. Cone Beam Computed Tomography images of the same region formed Group B. Two reference points were considered for both groups: 1) Incisal/cuspal/occlusal and 2) apical. Liner distance was measured between them. Values obtained were tabulated and analyzed using SPSS software.

Results: Total 56 maxillary and mandibular samples were assessed. They were divided into anterior and posterior region. For correlation between grids and Cone Beam Computed Tomography P value of significance was calculated to be $p < 0.001$ for both arches showing high statistically significant correlation between both radiographic methods in determining vertical linear measurements irrespective of anterior or posterior region. Grids overestimate the measurements compared to Cone Beam Computed Tomography by an average of 1.50mm. Grids showed greater average magnification for maxillary arch and anterior region.

Conclusion: Grid film overlaying Radiovisiography sensor can be effectively used to measure linear dimensions with minimal deviation in case of unavailability of modern diagnostics aids in ideal implant cases.

INTRODUCTION

Radiographic imaging is a keystone in understanding and delivery of craniofacial health care and appropriate treatment.^[1] The dimensional accuracy of dental radiographic images, and linear measurements derived from them, are crucial for the assessment of various

parameters necessary for treatment planning, such as tooth length^[2] and root length determination,^[3,4] alveolar bone height,^[5-8] size of periapical lesions,^[9] and implant site evaluation,^[10] Accuracy refers to those characteristics of the image which allow true representation of the object in the image:^[11] radiographic

* Corresponding author: **Dr. Vaidya Aayushi K**, BDS, (Perusing masters in Prosthodontics, II year PG MDS), ACPM Dental College, Dhule, Maharashtra, India.

accuracy is geometrically determined by radiation source-to-object distance (SOD), receptor-to-object distance (ROD) and horizontal and vertical cone or receptor angulation.^[12]

Preoperative planning is imperative in dental treatment. Pre-surgical radiographic assessment is in turn an important step for preoperative planning. Radiographic assessment is also required during intraoperative procedure. Plenty of modern diagnostic imaging tools are available to accomplish this purpose. However, these modalities pose a concern about their affordability, availability and radiation exposure.^[13]

Radiovisiography (RVG) yields a high-resolution planar image of a localized region of the jaws.^[14] Significant details about the implant site such as information on the trabecular pattern and the relationships of the anatomical structures can be precisely *procured*. Their wide use in dental clinical setup is attributable to their feasibility, ease of availability, lower cost and less radiation exposure.^[15,16]

Various techniques are proposed to assess size and distance from Intraoral Periapical (IOPA) radiographs. One such approach is the incorporation of grids (calibrated in millimeters).^[17] It employs lines 1 mm apart, running both lengthwise and crosswise. Lines at very fifth millimeter are accentuated by heavier lines to aid in easier measurements.^[18] In use, the grid is taped over the IOPA film such that it lies between the object and the sensor during exposure so that the pattern gets incorporated in the final radiographic image.

Cone Beam Computed Tomography (CBCT) has been proven to be a reliable technique for providing visualization of anatomical structures in the maxillofacial region. It also provides valuable assessment of the relationship of teeth and alveolar bone to the adjacent anatomic structures such as the maxillary sinus, inferior

alveolar canal and the mental foramen. Software programs integrating sophisticated algorithms are applied to the image data generated involving a 360 °scan of the patient's head. The applied algorithms generate a 3D volumetric data set which can be used to provide primary reconstruction images in three orthogonal planes i.e axial, sagittal and coronal. In combination with software modeling, a CBCT scan can be used as a virtual planning environment to attain ideal placement of implant.^[19]

Many studies have proven the high accuracy of CBCT measurements over other imaging techniques.^[20-28]

To facilitate measurements RVG softwares provides a function of electronically overlaying an evenly spaced horizontal and vertical grid over the obtained image. The electronically overlaying grid incorporated in the RVG software does not take into account the magnification due to variation in projection geometry. On the other hand, overlaying a grid film over the sensor such that it lies between the object and the sensor may help to overcome this problem as it will be subjected to the same magnification as the area it overlies.

The purpose of this study was to investigate the accuracy of IOPA grid superimposed over RVG sensor to determine tooth length by correlating the results with CBCT measurements as a reference gold standard.

MATERIAL AND METHOD

Data collection: In this study 56 patients, who *demand*ed for dental implantation at the Department of Prosthodontics and had CBCT were enrolled and examined. The ethical clearance had been obtained from the institutional ethical committee. All the patients were informed about the nature of the study and an informed consent was obtained prior.

For CBCT scanning, NewTom Giano was used. CBCT DICOM (Digital Imaging and Communication in Medicine) image files were available for measurement. Translucency and segmentation were adjusted initially and maintained on every DICOM for clear view. Original axial thickness was 0.150mm, with FSV 90KV, FOV [11x5] hi resolution, Air kerma 10.71 mGy, exposure time 9 sec. The inclusion criteria were: patients with clear CBCT images, showing fully developed teeth with intact, undamaged root structure without any periapical radiolucencies. The exclusion criteria were: teeth with restorations or prosthesis, incomplete root apex, presence of obvious root resorption or periapical radiolucency, dilacerated roots and presence of severe occlusal or incisal attrition.

A second set of data was obtained from matching periapical (PA) radiographs of the selected teeth by using IOPA grids superimposed over RVG sensors. Grid film of size 40mm x 30mm was used. The incorporated mesh line were stainless steel with fine grid placed 1mm apart running both lengthwise and crosswise. At every 5mm wide grid lines were positioned. Grid film was cut to fit the size of RVG sensor and was taped to it using transparent adhesive tape to prevent it from sliding over the sensor. The assembly was such that the grid lies between object and sensor during exposure so that grid pattern gets incorporated in the final radiographic image. RVG machine used for evaluation of tooth length was BIODENT -1070-D Wall Mounted Model with the following specifications; Power supply: 230V~50 Hz, X-Ray Tube : 70 KV,10Ma. Focal SPOT : 0.6mm x 0.6mm, Focus to skin distance : 20 cm, Filtration : 105 – Al, Exposure time : 0.01 sec to 5 sec. . Dentsply Sirona Sensor used was 31.2 × 43.9 x 6.3mm with an active surface of 25.6 x 36 mm. All periapical radiographs were obtained with bisecting angle technique and

measurements were made on the captured images using the Sidexis XG software supplied by the manufacturer. The patient was made to sit upright in chair with the head supported by headrest. Patient's occlusal plane was positioned parallel to the floor and the mid saggital plane perpendicular to the floor. For incisors and canine, long axis of the sensor was placed vertically whereas for the premolars and the molars the sensor axis was placed horizontally. The vertical angulations for maxillary arch were: incisor +40, canine +45, premolar +30 and for molar +20. For mandibular radiographs the angulations were : incisor -15, canine -20, premolar – 10 and molar - 5. Horizontal angulation was such that in the horizontal plane central ray was aimed through the interproximal contact area to avoid overlapping of teeth.

Data analysis: Two dentists pursuing masters in Prosthodontics were recruited as observers for this study. The observers were blinded to the demographic and biographic details of the patients. They were trained and calibrated to measure linear dimensions using grid markings and NNT software. The observers assessed CBCT images first and then periapical radiographs. All measurements were made by both the observers consensually. NNT software with the free viewer and sharing application version was used for CBCT. Image manipulation by changing contrast/brightness levels, sharpness filter and magnification was permitted to enhance visibility. Periapical radiographys were displayed using Sidexis XG software.

The following linear distances were measured for each tooth that had been obtained by two imaging modalities i.e CBCT and PA radiographs : 1. Distance from incisal edge to root apex for incisors. 2. Distance from cusp tip to root apex for canine and premolar. 3. Distance from disto buccal cusp tip to the distal root apex for molars.

For PA radiographs two points were marked, one on the incisal edge/cusp tip/distobuccal cusp tip and the other on the root apex. Wide and narrow grid lines were then used to measure the distance between the marked points (Figure 1). Measurements on CBCT were obtained by dragging the cursor between two points on the axial (Figure 2A) and panoramic view (Figure 2B) and calculating their average for each tooth.

Two measurements for each tooth (CBCT and grid) were hence determined and tabulated into a master table. The data was divided into two groups – maxillary and mandibular and further subdivided into anterior and posterior tooth length measurements.

Statistical analysis: The values thus obtained were tabulated and statistically analyzed using SPSS software version 21 (ibm). The mean and standard deviation was calculated for two groups; namely, Group A (grids) and Group B (CBCT) for both maxillary and mandibular measurements. Unpaired t-test was used to compare the individual mean between both the groups. The a priori level of significance was set at $p < 0.05$. Pearson correlation analysis was used to analyze the relationship between the data acquired using the two methods. The correlation coefficient (r) between the samples was calculated and was considered highly related if ' r ' was between 0.5 and 1.

Further the data acquired was subdivided into maxillary anterior and maxillary posterior groups. Similar mandibular data was subdivided into mandibular anterior and posterior groups. Means and standard deviation was calculated for all four groups. Unpaired t-test was used to compare the individual mean between all 4 groups. $P < 0.05$ was considered statistically significant. Pearson correlation analysis was used to analyze the relationship between the data acquired from maxillary anterior and posterior region and between mandibular anterior and

posterior region. The correlation coefficient (R) was calculated and was considered highly related if R was between 0.5 and 1.

RESULT

Total 56 samples were assessed. Out of which 22 were measurements of maxillary teeth and 34 were that of mandibular teeth. *Table 1* shows the mean and SD values for Group A maxilla and mandible, Group B maxilla and mandible. The overall mean and SD values for Group A are 20.67 and 23.83 respectively and group B the values are 19.17 and 2.66 respectively. Group A shows an average magnification of 2.71mm for the maxillary arch and 0.72mm for the mandibular arch calculated by the difference between means. The overall magnification of group A for both the arches was observed to be 1.50 mm. The 'p' value of significance for mandibular arch was calculated to be 0.296, indicating that there is no statistically significant difference between vertical measurements obtained using both imaging techniques.

Table 2 shows Pearson correlation test ' r ' value of 0.775 and 0.956 for maxilla and mandible respectively. P value of significance for correlation was calculated to be $p < 0.001$ for maxilla, mandible and overall; showing high statistically significant correlation between both grids and CBCT for measuring vertical dimensions.

Table 3 shows the comparative statistical analysis for anterior and posterior teeth measurement in the maxillary arch. Pearson correlation value ' r ' for maxillary anterior and posterior was 0.796 and 0.661 respectively. A statistically significant correlation was found between both imaging techniques for use in maxillary anterior ($p = 0.006$) and maxillary posterior ($p = 0.019$). Group A shows magnification of 3.33 mm and 2.2 mm for maxillary anterior and posterior region respectively.

Similarly, *Table 4* shows comparative statistics of linear measurements for mandibular. . Pearson correlation value 'r' for mandibular anterior and posterior was 0.960 and 0.981 respectively. A statistically significant correlation was found between grids and CBCT for

mandibular anterior and high statistically significant correlation for mandibular posteriors. Group A shows magnification of 1.27mm and 0.16mm for mandibular anterior and posterior region respectively.

Table 1: Comparative statistics of linear measurements between Grid (Group A) and CBCT (Group B) respectively

	Group A (Grid) Mean (SD)	Group B (CBCT) Mean (SD)	Difference Mean (SD)	Unpaired t test	p value, Significance
Maxilla	22.58 (4.42)	19.87 (2.41)	2.71 (1.68)	t = 2.524	p = 0.015*
Mandible	19.44 (2.83)	18.72 (2.73)	0.72 (0.89)	t =1.053	p =0.296
Overall	20.67 (2.83)	19.17 (2.66)	1.50(1.26)	t =2.403	p =0.018*

p >0.05 – no significant difference *p<0.05 – significant **p <0.001 – highly significant

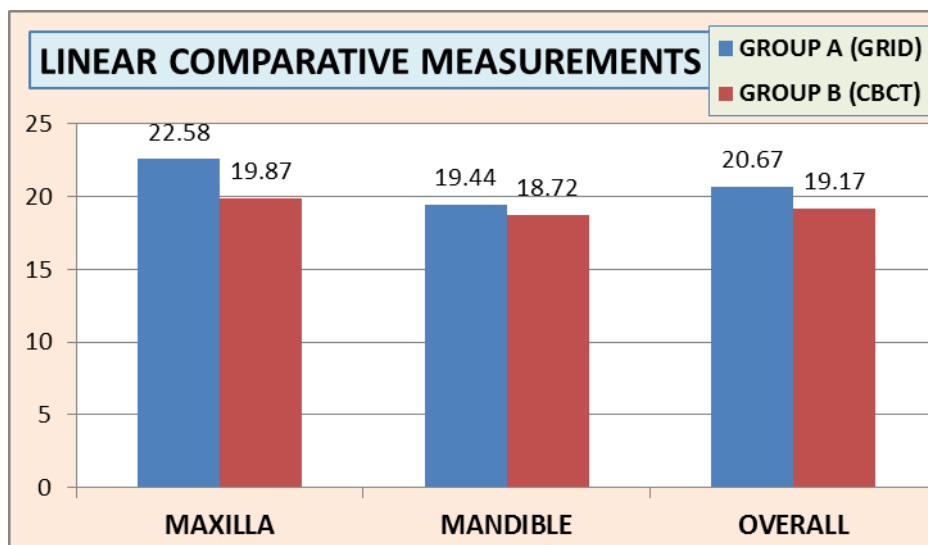


Table 2: Correlation of linear measurements between Grid (Group A) and CBCT (Group B) respectively

	Group A (Grid) Mean (SD)	Group B (CBCT) Mean (SD)	Pearson 'r' correlation test	p value, Significance
Maxilla	22.58 (4.42)	19.87 (2.41)	r = 0.775	p <0.001**
Mandible	19.44 (2.83)	18.72 (2.73)	r = 0.956	p <0.001**
Overall	20.67 (23.83)	19.17 (2.66)	r = 0.834	p <0.001**

p >0.05 – no significant correlation *p<0.05 – significant **p <0.001 – highly significant

Table 3: Comparative statistics of linear measurements in maxillary arch between Grid (Group A) and CBCT (Group B) respectively

Maxillary arch	Group A (GRID) Mean (SD)	Group B (CBCT) Mean (SD)	Difference Mean (SD)	Unpaired t test	p value, Significance
Anterior	24.01 (5.27)	20.68 (2.89)	3.33 (2.69)	t = 1.751	p = 0.097
	r = 0.796 , p = 0.006*				
Posterior	21.4 (3.36)	19.2 (1.77)	2.2 (1.42)	t = 2.003	p = 0.058
	r = 0.661, p = 0.019*				

p > 0.05 – no significant correlation *p < 0.05 – significant **p < 0.001 – highly significant

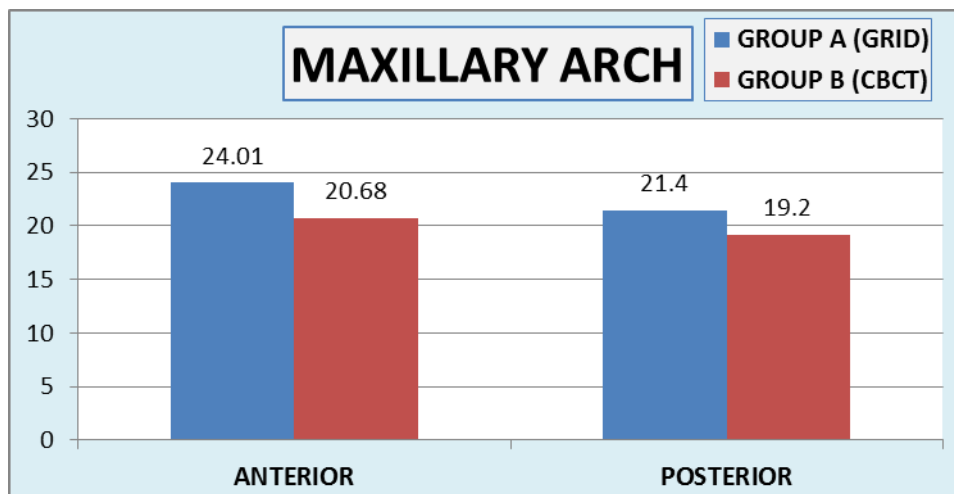
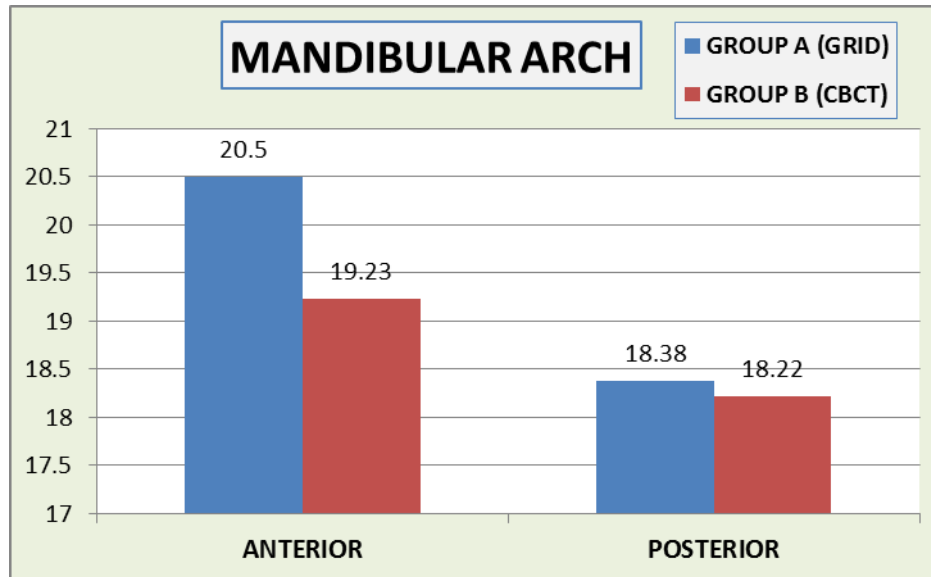


Table 4: Comparative statistics of linear measurements in mandibular arch between Grid (Group A) and CBCT (Group B) respectively

Mandibular arch	Group A (GRID) Mean (SD)	Group B (CBCT) Mean (SD)	Difference Mean (SD)	Unpaired t test	p value, Significance
Anterior	20.5 (2.07)	19.23 (2.18)	1.27 (1.09)	t = 1.741	p = 0.091
	r = 0.960 , p < 0.001*				
Posterior	18.38 (3.14)	18.22 (3.23)	0.16 (0.31)	t = 0.145	p = 0.885
	r = 0.981, p < 0.001**				

p > 0.05 – no significant correlation *p < 0.05 – significant **p < 0.001 – highly significant



DISCUSSION

RVG permit rapid acquisition of intraoral images, their storage, retrieval, and transmission to remote sites. It also allows operator to manipulate image density and contrast and to measure bone density at specific sites. The ease of availability, less radiation exposure and affordability make it a rather convenient option for preoperative, intra operative and post operative radiography.

CBCT was used in this study as a “gold standard” since it has helped to overcome the shortcomings and disadvantages of the various other imaging techniques. In combination with software modeling it has been proven instrumental in accurately measuring the linear dimensions.

The measurement algorithm of the various RVG softwares involves electronically overlaying an evenly spaced horizontal and vertical grid over the obtained image (RVG-S). Some systems use a mouse to position a cursor at points on the displayed image. Designation of two points in this mode results in a straight line being drawn between them followed by a numerical read-out to the nearest 0.1 mm on the screen (FlashDent). They also

allow cumulative measurements. However the variations in projection geometry will have an effect on the accuracy of these measurement functions.^[29]

The principles of image magnification through alterations in projection geometry were established early in the development of radiography.^[29] The electronically overlaying grid incorporated in the RVG software does not take into the account this magnification. On the other hand, overlaying a grid film over the sensor such that it lies between the object and the sensor and gets incorporated in the radiographic image can help to overcome this problem. In this case the grid lines will also encounter the same magnification due to alteration in projection geometry as the area it overlies.

The present investigation was conducted to assess the reliability of grid film overlaying RVG sensor for measuring liner dimension in the maxilla and the mandible. Also, to determine its accuracy for measurements in the anterior and posterior region of the jaws. The correlation results with CBCT measurements demonstrated high statistically significant strong positive correlation between both diagnostic methods in determining linear measurements in both maxillary and

mandibular archs irrespective of anterior or posterior regions.

According to comparative statistics of linear measurements between Grid (Group A) and CBCT (Group B) , Group A overestimated or have shown statistically significant larger linear dimensions as compared to Group B in maxillary region and overall (maxilla and mandible).Between the arches the accuracy of measurements was more for the mandibular arch as compared to the maxilla. Also grids gave more accurate measurements for the posterior region in comparison to the anterior region. For mandibular region, Group A overestimated and have shown larger linear dimensions as compared to Group B but the difference was not found to be of statistical significance irrespective of anterior or posterior region.

According to a study by Sanjana R et al, performed to assess the accuracy and reliability of linear measurements of CBCT, the author states that the CBCT measurements tends to slightly underestimate the anatomic truth.^[30] This can explain the overestimation found for group A samples in this study.

In conclusion, on basis of the results obtained in this study we can say that IOPA overlay grids can be effectively used for vertical linear measurements with minimal deviation in case of unavailability of modern imaging aids. They can prove to be instrumental in treating ideal implant cases at a reduced cost.

REFERENCE

1. Mah J, Hatcher D. Current status and future needs in craniofacial imaging. *Orthod Craniofac Res.* 2003; 6(Suppl 1):10-6.
2. Bhakinaronk A, Manson-Hing LR. Effects of radiographic technique upon prediction of tooth length in intraoral radiography. *Oral Surg Oral Med Oral Pathol.* 1981; 51:100-7.
3. San Marco PA, Montgomery S. Use of xeroradiography for length determination in endodontics. *Oral Surg Oral Med Oral Pathol.* 1984; 57:308-14.
4. Sanderink GC, Huiskens R, van der Steh PF, Welander US, Stheeman SE. Image quality of direct intraoral X-ray sensors in assessing root canal length. *Oral Surg Oral Med Oral Pathol.* 1994; 78:125-32.
5. Regan JE, Mitchell DF. Roentgenographic and dissection measurements of alveolar crest height. *J Am Dent Assoc.* 1963; 66:356-59.
6. Hausmann E, Allen K, Christersson L, Genco, RJ. Effect of x-ray beam vertical angulation on radiographic alveolar crest measurement. *J Periodontol Res.* 1989; 24:8-19.
7. Akesson L, Hakansson J, Rohlin M. Comparison of panoramic and intraoral radiography and pocket probing for measurement of marginal bone level. *J Clin Periodontol.* 1992; 19:326-32.
8. Akesson L. Panoramic radiography in the assessment of the marginal bone level. *Swed Dent J Suppl.* 1991; 78:1-129.
9. Tidmarsh BG. Radiographic interpretation of endodontic lesions - a shadow of reality. *Int. Dent J.* 1987; 37:10-5.
10. Benn DK. Estimating the validity of radiographic measurements of marginal bone height changes around osseointegrated implants. *Implant Dent.* 1992; 1:79-93.
11. Curry III, TS, Dowdey JE, Murry Jr., RC. Christensen's physics of diagnostic radiology. 4th edn. Philadelphia: Lea & Febiger. 1990, 220-1.
12. Goaz PW, White SC. Oral radiology: principles and practice. 3rd edn. St. Louis: Mosby. 1994, 113-5.

13. Mupparapu M, Singer SR. Implant imaging for the dentist. *J Can Dent Assoc.* 2004; 70:32
14. Shawkat AH. Intraoral radiographic examinations. In: Goaz PW, White SC, editor. *Oral radiology: principles and interpretation*, 2nd ed. St Louis (MO). 1987, 200-267.
15. Bhargava D, Deshpande A, Sreekumar K, Deshpande A. Relationship of mandibular canal to root apices of mandibular molars: accuracy of intraoral periapical radiographs. *J Stomat Occ Med.* 2011; 4:118-122
16. Sewerin IP. Errors in radiographic assessment of marginal bone height around osseointegrated implants. *Scand J Dent Res.* 1990; 98:428-33
17. Patterson WR. Radiographic incrementation. *Oral Surg Oral Med Oral Pathol.* 1956; 9:885-7.18.
18. Everett FG, Fixott HC. Use of an incorporated grid in the diagnosis of oral roentgenograms. *Oral Surg Oral Med Oral Pathol.* 1963; 16:1061-64.
19. Worthington P, Rubenstein J, Hatcher DC. The role of cone beam computed tomography in the planning and placement of implants. *J Am Dent Assoc.* 2010; 141:19S-24S.
20. Abrahams JJ. CT assessment of dental implant planning. *Oral Maxillofac Surg Clin North Am.* 1992; 4:1-18
21. Quirynen M, Naert I, van Steenberghe D, Terrlinck J, Dekeyser C, Theuniers G. Periodontal aspects of osseointegrated fixtures supporting an overdenture. A 4-year retrospective study. *J Clin Periodontol.* 1991; 18:719-28.
22. Jeffcoat M, Jeffcoat RL, Reddy MS, Berland L. Planning inter- active implant treatment with 3-D computed tomography. *J Am Dent Assoc.* 1991; 122:40-4.
23. Tal H, Moses O. A comparison of panoramic radiography and computed tomography in the planning of implant surgery. *Dentomaxillofac Radiol.* 1991; 20:40-2.
24. Wishan MS, Bahat O, Krane M. Computed tomography as an adjunct in dental implant surgery. *Int J Periodont Rest Dent.* 1988; 8:30-47.
25. Casselman JW, Quirynen M, Lemahieu SF, Baert AL, Bonte J. Computed tomography in the determination of anatomical landmarks in the perspective of endosseous implant installation. *J Head Neck Pathol.* 1988; 7:255-64.
26. Abrahams JJ, Levine BP. Expanded applications of DentaScan (multiplanar computerized tomography of the mandible and maxilla). *Int J Periodont Rest Dent.* 1990; 10:464-71.
27. Schwarz MS, Rothman SLG, Rhodes ML, Chafetz N. Computed tomography: Part 1. Preoperative assessment of the mandible for endosseous implant surgery. *Int J Oral Maxillofac Implants.* 1987; 2:137-41.
28. Schwarz MS, Rothman SLG, Rhodes ML, Chafetz N. Computed tomography: Part II. Preoperative assessment of the mandible for endosseous implant surgery. *Int J Ora Maxillofac Implants.* 1987; 2:137-41.
29. Scarfe W, Norton S, Farman A. Measurement accuracy: a comparison of two intra-oral digital radiographic systems, RadioVisiography-S and FlashDent, with analog film. *Dentomaxillofacial Radiology.* 1995; 24(4):21
30. Ravindra S. Assessment of Accuracy and Reliability of Linear Measurements of CBCT- An in vitro study. *Indian Journal of Applied Radiology.* 2017; 4(1):1.