

Case Report

Management of Maxillary Lateral Incisor With Palato-Radicular Groove and Periapical Cyst: A Case Report

Shyam bhamare ¹, Zinnie Nanda ², Kranthikumar Reddy³, Shrikant Pathak ⁴, Jasmit Kaur ⁵, Sachin Rakh ⁶

¹ Post Graduate student, Dept of Conservative Dentistry & Endodontics, ACPM Dental College, Dhule, Maharashtra, India

²Professor and HOD, Dept of Conservative Dentistry & Endodontics, ACPM Dental College, Dhule, India

³Reader, Dept. of Conservative Dentistry & Endodontics, ACPM Dental College, Dhule, India

^{4,5,6} Post Graduate student, Dept of Conservative Dentistry & Endodontics, ACPM Dental College, Dhule, India

ARTICLE INFO



Keywords:

Maxillary lateral incisor, palatoradicular groove, periapical cyst, biodentine

ABSTRACT

In recent studies it has been found that the Palatoradicular groove serves as a convenient pathway for nutrients to reach bacteria in the root canal and periapical tissues. The concurrence of a palatoradicular groove and periapical cyst in the same tooth is a common finding that poses both endodontic and periodontal challenges. This clinical report describes a planned sequence of successful multidisciplinary approaches for the management of a maxillary lateral incisor with a TYPE 3 palatoradicular groove and a periapical cyst. The Rationale behind the treatment modalities in the present case is discussed here.

INTRODUCTION

The maxillary incisors can show various morphologic and anatomic anomalies, including globulomaxillary cysts, cleft palate, congenital absence of tooth, supernumerary tooth, dens invaginatus, Eagle's talon, peg-shaped lateral incisor, gemination, fusion, accessory roots etc.⁽¹⁾

Palatogingival groove (PGG) is one such anomaly, usually present in the lateral incisors

with a prevalence rate of 2.8-8.5%⁽²⁾. It was first described by Black in 1908. Since then the PGG is recognized by various terminologies such as radicular lingual grooves, distolingual grooves, palatal gingival grooves, and radicular palatal grooves⁽³⁾. Kovacs (1971) called this anomaly 'syndesmocorono-radicular tooth'⁽⁴⁾. Black defined the PGG as a developmental anomaly that begins near the tooth cingulum

* Corresponding author: **Shyam bhamare**, Post Graduate Student, Dept of Conservative Dentistry & Endodontics, ACPM Dental College, Dhule, India.
Email: bhamare.shyam4390@gmail.com

and extends from the cemento-enamel junction (CEJ) in an apical direction along the root with a wide range of depths and lengths ⁽¹⁾. The depth of the groove and its apical extent determine the prognosis of its management ⁽⁵⁾. Although shallow grooves can be corrected using odontoplasty and periodontal therapy, the deeper ones are considered to have a very high failure rate due to both pulpal and periodontal involvement ^(4,6).

The groove represents an infolding of the enamel organ and Hertwig's root sheath, leading to an external defect adjacent to the gingival crevice ⁽⁷⁾. Atkinson (1943), suggested that an imbalance in growth between different areas of the maxilla would deprive the lateral incisor dental germ of adequate space in which to develop, thus the palato-gingival groove would be a consequence of dental germ folding⁽⁸⁾.

The management of such groove poses a challenge to both an endodontist as well as a periodontist ⁽⁵⁾.

There are several systems for the classification of PGG.

Depending on its location on the tooth, the groove could be distal, mesial or central (mid-palatal) ⁽⁹⁾.

According to **Kogon et al** -Depending on the degree of invagination of the groove towards the pulp cavity, a PGG could be

Type 1-Shallow/flat (< 1 mm),

Type 2-Deep (> 1 mm),

Type 3-Closed tube ⁽⁹⁾.

The present case report describes the management of a lateral incisor with a TYPE 3 palatao-radicular groove and a periapical cyst associated with the same, following a history of trauma. Although the tooth presented a questionable prognosis, it was managed successfully using surgical endodontic therapy and secondary periodontal therapy. The clinical features and the management of the problems encountered in the case are here reported.

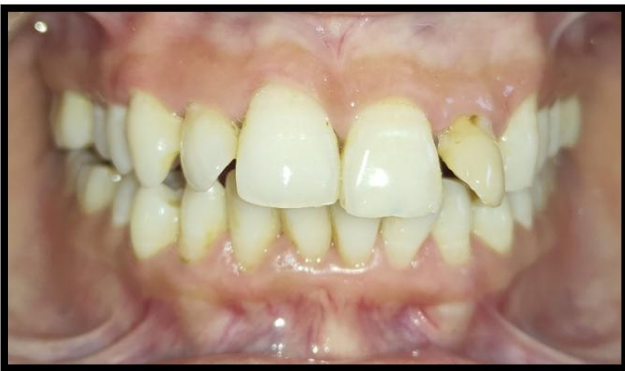CASE REPORT-

A 24-year-old female patient reported with the chief complaint of pain, discoloration, and mobility in relation to tooth 21, 22 and 23 since 4 months. Periodontal examination revealed a pocket depth of around 10mm associated with a deep palatoradicular groove in relation to the lingual surface of maxillary left lateral incisor **[figure-1b]**. The tooth also displayed significant displacement on the labial side. **[Figure-1a]**. On vitality test with the help of electronic pulp test (Gentle pulse) tooth 21, 22, 23 revealed negative response only 22 showed greyish black discoloration, confirming the diagnosis of a non-vital pulp. There was a history of trauma in relation to the concerned tooth 21, 22 and 23. Thus, it appeared likely that pulp necrosis had occurred secondary to the deep periodontal defect occurring as a result of the palatoradicular groove. An intraoral periapical radiograph revealed a large

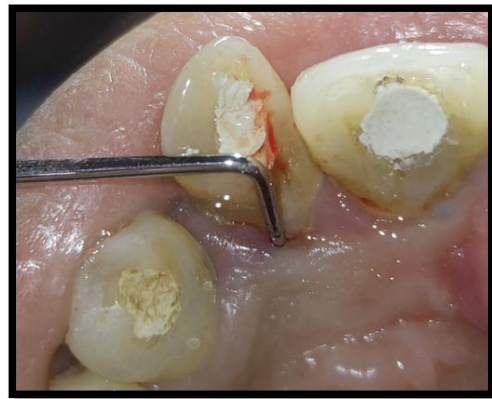periapical lesion invading roots of tooth 21, 22 and 23 **[Figure-2]**. Since bilateral occurrence of the palatoradicular groove is possible, tooth 12 was also examined, but no evidence of a palatoradicular groove was found after sulcular probing and radiography.

After taking the patient's consent, endodontic treatment followed by surgical approach was planned. Access opening was done with tooth 21, 22, and 23 in the usual manner and working length was taken. Pus discharge was seen with tooth 22 and the canals were cleaned and shaped by using K-files (Mani) for tooth 22 and rotary NiTi (protaper,dentsply) for tooth 21,23 and irrigation done by using 3% sodium hypochlorite, normal saline, 2% chlorhexidine, and after which calcium hydroxide (AvueCal+) was packed in canals for 1 week.

The patient was recalled after 1 week, obturation of tooth 21 and 23 was completed with cold lateral



(1a)



(1b)

FIGURE 1a-Preoperative clinical photograph

FIGURE 1b-Deep periodontal pocket present palatally with 22

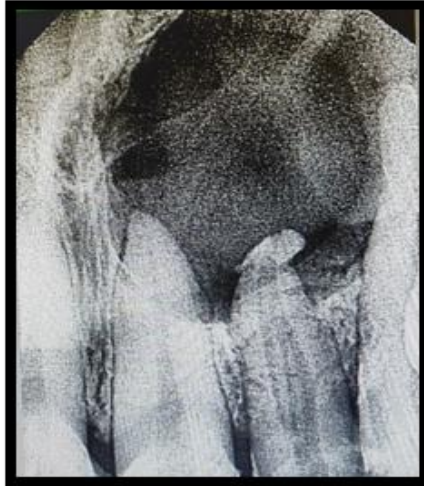


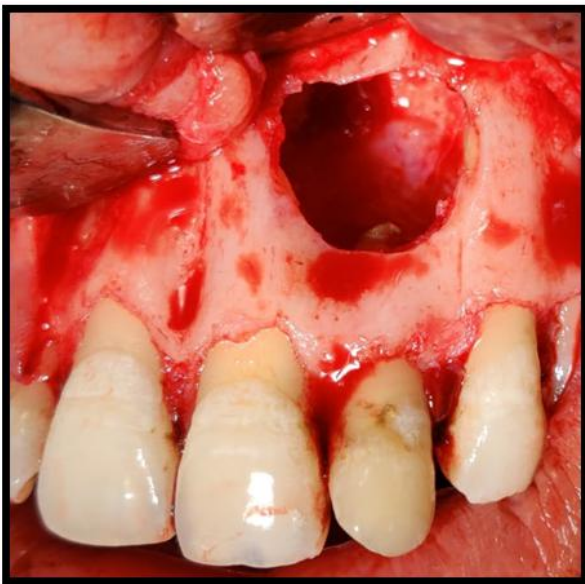
FIGURE 2-Large periapical radiolucency with tooth 21,22,23.

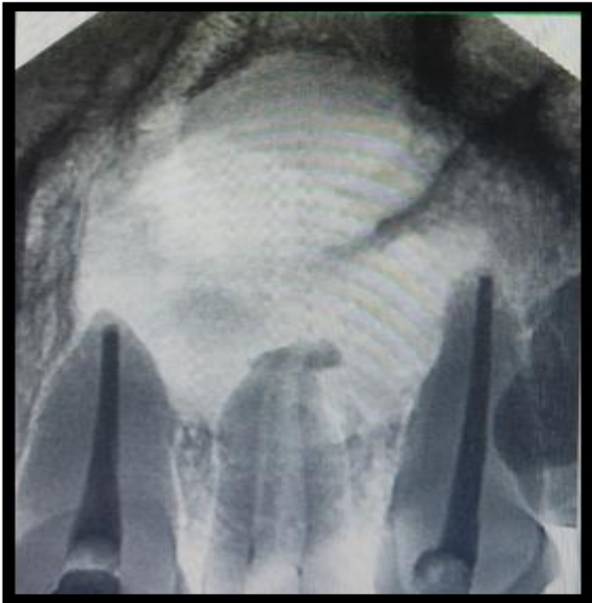

FIGURE 3-obturation with tooth 21 and 23.

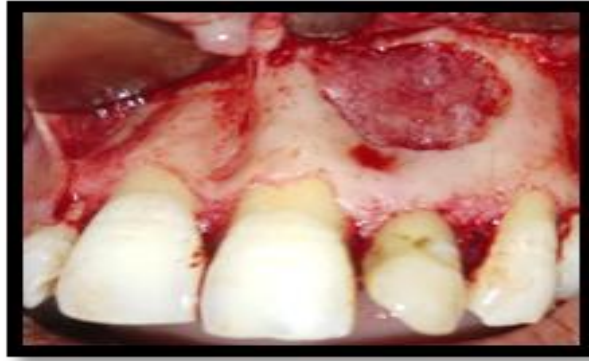

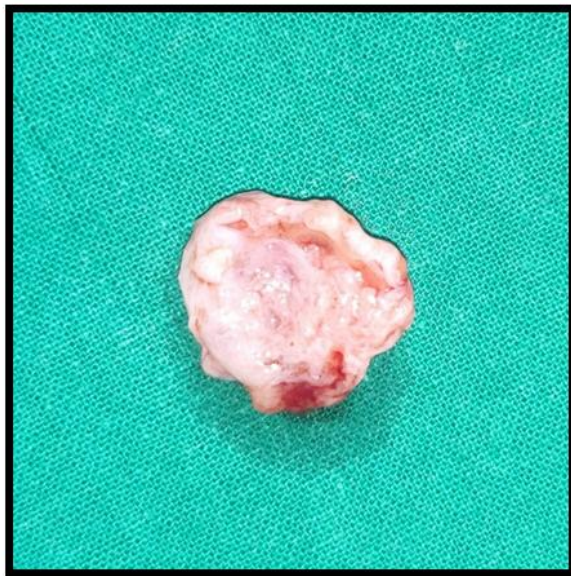FIGURE 4- full thickness rectangular mucoperiosteal flap was reflected and location of cyst

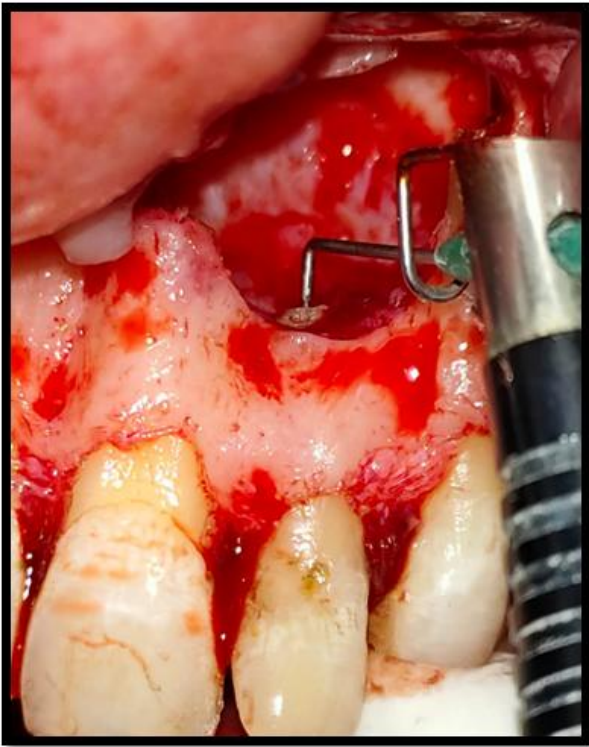

(5a)



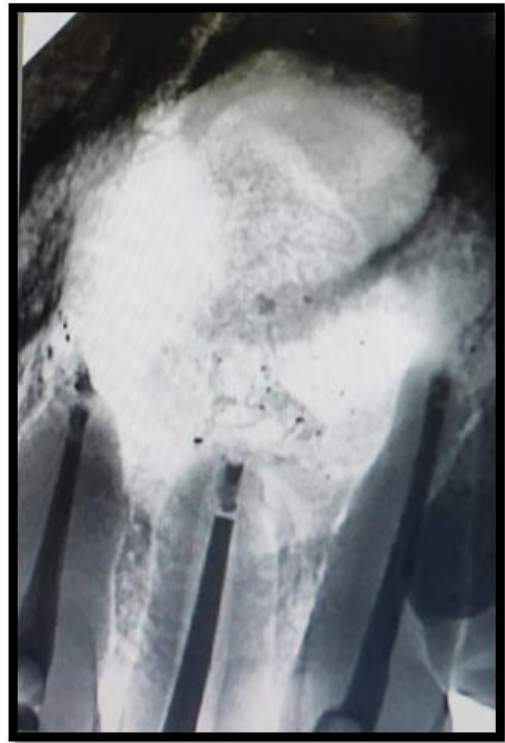(5b)

FIGURE 5a, 5b- cystic enucleation



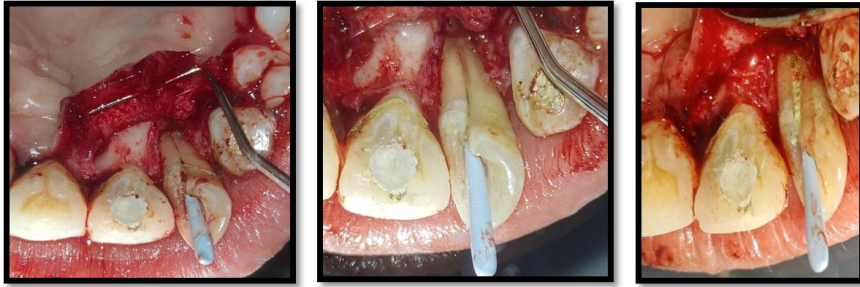(6a)

FIGURE 6a- Retrograde root end preparation with tooth 21, 22, 23



(6b)

FIGURE 6b- Retrograde root end filling was completed with Biodentine



(7a)

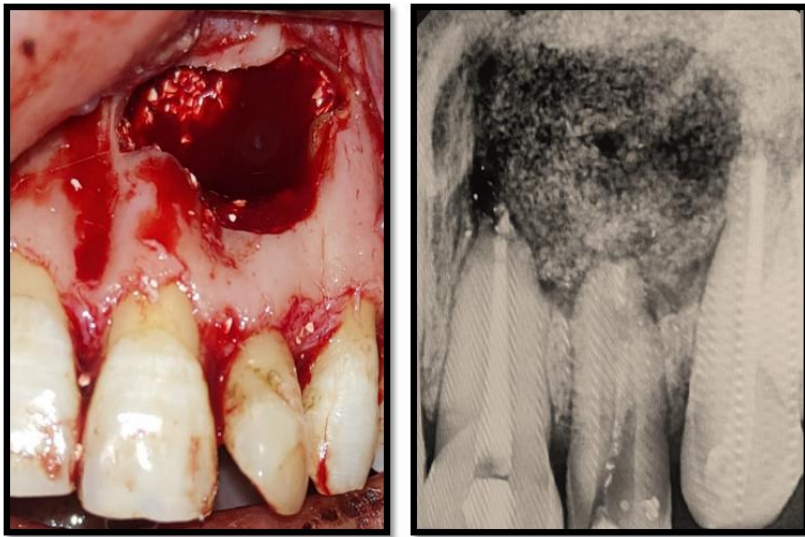
(7b)

(7c)

FIGURE 7a- flap was reflected on the palatal aspect and the palatoradicular groove was traced.

FIGURE 7b- Debridement of palatoradicular groove.

FIGURE 7c- Biodentine was placed within groove



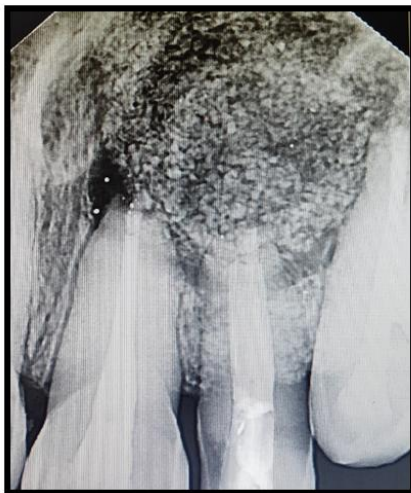
(8a)

(8b)

FIGURE -8a, 18b- BLEEDING INDUCED WITHIN CAVITY AND PALCEMENT OF BONE GRAFT

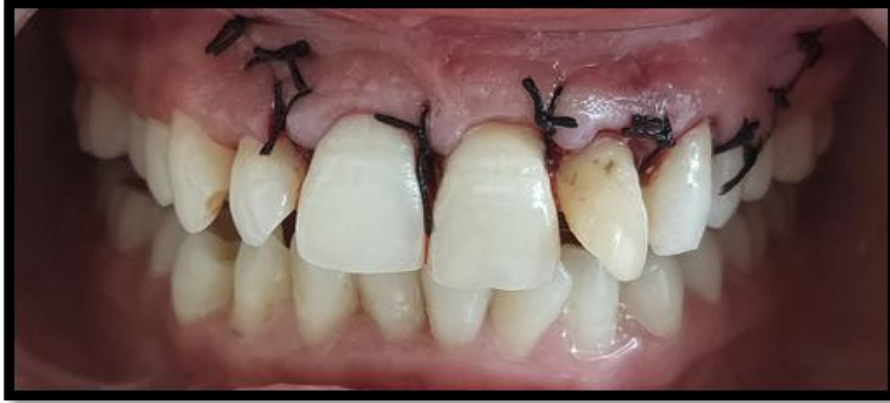

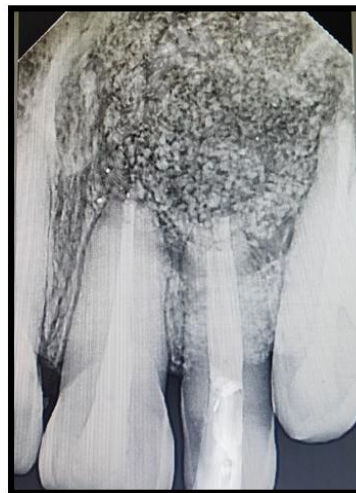FIGURE 9- suture given



(10a)



(10b)

FIGURE 10a- Thermoplasticized obturation with tooth 22 followed by post obturation restoration with tooth 21, 22 and 23.

FIGURE 10b- 6 months of follow up with good hard tissue healing.

compaction technique [figure-3]. Obturation of tooth 22 was not planned as there was continuous pus discharge seen. The access opening was sealed with ZOE temporary restorative material.

A full-thickness rectangular mucoperiosteal flap was reflected on the labial aspect of tooth 21, 22, and 23. On reflection, a large cyst with granulation tissue was found around roots of 21, 22 and 23 [figure-4]. Cystic enucleation and granulomatous tissue was removed [figure-5a, 5b]. Tissue specimen sent for histopathological analysis. Root end resection was performed with tooth 21, 22, and 23. Retrograde root end preparation [figure-6a] performed with endosonic hand piece (Sonic Air 1500, MicroMega). Retrograde root end filling was completed with Biodentine (Septodont).[figure-6b]

A full-thickness mucoperiosteal flap was reflected on the palatal aspect of tooth 21, 22, and 23. Granulomatous tissue was removed and

the palatoradicular groove was traced. Debridement of groove performed and root conditioning done by using 17% EDTA (AvuePrep) and biodentine was placed within groove [figure-7a, 7b]. Bleeding was induced in cystic bony cavity [figure-8a] and Bone graft (Sybograf +) was placed [figure-8b]. Both buccal and palatal flap was reunited and 4-0 mersilk suture was given [figure-9]. Patient was recalled after 7 days for suture removal and follow up. Postoperative recovery was normal and sutures removed after a week. Thermo- plasticized obturation (E and Q) performed with tooth 22 followed by post obturation restoration with tooth 21, 22 and 23. [Figure-10a]

The tooth remained asymptomatic and reviewed every month. The tooth was asymptomatic after a 1, 3, 6 months of follow up [figure-10b] with good soft and hard tissue healing.

DISCUSSION-

1. The presence of morphological defect such as Radicular lingual groove is considered to be a crucial contributing factor to the development of localized chronic periodontitis, as the groove provides a site or pathway for the accumulation and proliferation of bacterial plaque deep into the periodontium. Hence an early recognition of PRG is critical in order to carry out its timely management and prevent any further pathosis. This anomaly affects maxillary incisors, mostly the lateral incisors. The first large survey elaborating on the incidence of PGG in the extracted teeth was done by Everett and Kramer⁽¹⁰⁾.

2. If palatoradicular groove extends to the apical third of root, it results in a poor prognosis for retention of the tooth. The presence of this groove is associated with the displacement of cemento-enamel junction, extension of enamel in the groove and necrosis of adjacent pulpal tissue. In turn, all these factors favour the progression of localized periodontal disease⁽¹¹⁾.

3. Successful treatment of the Palatogingival groove depends mainly on its ability to eradicate the pathways of inflammatory irritants, by eliminating or sealing the groove. Procedures such as radiculoplasty have been recommended to eliminate the groove. Sealing the groove has been tried with various materials after preparation and conditioning of the groove⁽¹²⁾.

4. Bioactive dentin substitute (Biodentine) stimulates cell growth, induces hydroxyapatite formation on the surface of the material when exposed to the simulated body fluid. Biodentine supports periodontal ligament fibroblast cell adhesion and can be used as a root repair material⁽¹³⁾.

5. Prognosis of this defect depends on factors such as location of the groove, depth of the groove and its extension and the amount of destruction of periodontal attachment apparatus. These factors, determine the treatment protocol, such as for a shallow groove that is limited to the coronal structure

odontoplasty and periodontal therapy is done. The treatment of this defect is complex, in cases where the groove is deep enough with pulpal involvement⁽¹³⁾.

Conclusion –

Palatogingival groove is a rare aberration on the maxillary anterior teeth, which occasionally results in combined endodontic-periodontal involvement with extensive periodontal destruction of the tooth, which is associated with poor prognosis. In the past, a tooth with a complex form of PGG was regarded as hopeless, and immediate extraction was recommended. However, with the invention of new materials, diagnostic tools, and understanding of the characteristics and treatment principles, many recent cases have shown successful treatment outcomes on teeth with PGG. Clinicians need a detailed understanding in order to recognize the existence of PGG and manage it properly to ensure survival of the tooth.

REFERENCES-

- 1) Hee-Jin Kim et al. Recognition and management of palatogingival groove for tooth survival: a literature review. *Restor Dent Endod* 2017;42(2):77-86.
- 2) Karunakaran JV, Fenn SM, Jayaprakash N, Ragavendran N. Successful surgical management of palatogingival groove using platelet-rich fibrin and guided tissue regeneration: A novel approach. *J Pharm Bioall Sci* 2017;9:S268-73.
- 3) Hans MK, Srinivas RS, Shetty SB. Management of lateral incisor with palatal radicular groove. *Indian J Dent Res* 2010;21:306-8.
- 4) Salvaging a tooth with a deep palatogingival groove: an endo-perio treatment – a case report.
- 5) Friedman S, Goultsehin J. The radicular palatal groove – a therapeutic modality. *Endod Dent Traumatol* 1988; 4:282-286.
- 6) Sooratgar A, Tabrizzade M, Nourelahi M, Asadi Y, Sooratgar H. Management of an

- Endodontic-Periodontal Lesion in a Maxillary Lateral Incisor with Palatal Radicular Groove: A Case Report. Iran Endod J. 2016;11(2):142-5.
- 7) Rajput A, Talwar S, Chaudhary S, Khetarpal A. Successful management of pulpo-periodontal lesion in maxillary lateral incisor with palatogingival groove using CBCT scan. Indian J Dent Res 2012;23:415-8.
- 8) JP Ennes, VS Lara. Comparative morphological analysis of the root developmental groove with the palatogingival groove. Oral Diseases (2004) 10, 378–382.
- 9) Kogon SL. The prevalence, location and conformation of palato-radicular grooves in maxillary incisors. *J Periodontol* 1986;57:231-234.
- 10) Sawhney A, Thakur RK, Singh AK, Yadav BK, Ralli M. Palatogingival groove: A pathway to periodontal destruction. Medical Journal of Dr. DY Patil Vidyapeeth. 2019 Jan 1;12(1):55.
- 11) Gottlow J. Guided tissue regeneration using bioresorbable and non-resorbable devices: initial healing and long-term results. Journal of periodontology. 1993 Nov;64:1157-65.
- 12) Zucchelli G, Mele M, Checchi L. The papilla amplification flap for the treatment of a localized periodontal defect associated with a palatal groove. Journal of periodontology. 2006 Oct;77(10):1788-96.
- 13) Karunakaran JV, Fenn SM, Jayaprakash N, Ragavendran N. Successful surgical management of palatogingival groove using platelet-rich fibrin and guided tissue regeneration: A novel approach. Journal of pharmacy & bioallied sciences. 2017 Nov;9(Suppl 1):S268.