

Case Report

Fibrous Hyperplasia: A Case Report

Babita Pawar ¹, Hema Suryawansi ², Shyam Sunder Salavathi ³, Yugal Kishor ⁴, Trupti Wankhedhe ⁵, Shweta Sarate ⁶

¹ Professor and HOD, Department of Periodontology, Chattisgarh Dental College And Reaserch Institute, Rajnandgaon

² Professor and HOD Department of Oral Pathology, Chattisgarh Dental College And Reaserch Institute, Rajnandgaon

³ Reader, , Department of Periodontology, Chattisgarh Dental College And Reaserch Institute, Rajnandgaon

^{4,5,6}Post Graduate student, Department of Periodontology, Chattisgarh Dental College And Reaserch Institute, Rajnandgaon

ARTICLE INFO



Keywords:

Fibrous hyperplasia, surgical excision,
Non neoplastic lesion

ABSTRACT

Fibrous hyperplasia is a non-neoplastic lesion of fibrous connective tissue origin considered to be a histologic variant of fibroma that causes aesthetic and functional problems. It is a localized reactive progressive, proliferation of oral mucosa in response to injury or local irritation. The choice of treatment should always be founded on basic principles of pathology and sound surgical judgment. Treatment usually requires total excision and recurrence is rare. This case report describes a cases of focal fibrous hyperplasia, which was successfully treated by surgical excision.

INTRODUCTION

Focal fibrous hyperplasia (FFH), Also known as irritation or traumatic fibroma, is a reactive, inflammatory hyperplastic lesion of the connective tissue. It presents usually as a yellowish–white or mucosal coloured, sessile, smooth-surfaced, asymptomatic, soft nodule. The surface may be hyperkeratotic or ulcerated, owing to repeated trauma. The most common intraoral site is along the occlusal line of the buccal mucosa – an area subject to masticatory trauma – but it also affects the lower lip, tongue, hard palate and edentulous alveolar ridge(1)
On the basis of site involved reactive lesions can be classified under various headings as listed in Table 1.(2)

Table 1: Reactive Lesions affecting different sites of oral cavity

Lesions predominantly affecting gingiva

1. Peripheral fibroma (fibrous hyperplasia, fibrous epulis)
2. Pyogenic granuloma
3. Peripheral giant cell granuloma
4. Peripheral ossifying fibroma

Lesions affecting tongue

1. Hairy tongue
2. Hairy leucoplakia

Lesions affecting palate

* Corresponding author: **Sachin Rakh**, Post Graduate student, Dept of Conservative Dentistry & Endodontics, ACPM Dental College, Dhule, India.

1. Nicotine stomatitis

Lesions affecting buccal mucosa and vestibule

1. White lesions associated with smokeless tobacco
2. Dentifrice associated slough

Case Report

A 18 yr old boy come for evaluation of lesions in the posterior maxilla (Figure1).Dental history revealed that the growths first appeared 5 months ago, he first noticed swelling on maxillary posterior region during mastication and were slowly increasing in size. The boy was not in any pain, The lesion on the hard palate was about 2 centimetre in size, pink in colour, stippled and attached via a peduncle to the attached gingiva. The lesion blanched slightly with digital pressure, circular, pink in colour, stippled ,sessile, between tooth no. 16 and

tooth no.26.. A radiograph of the area revealed no bony involvement (Figure 2).

Perform excisional biopsy of lesions under local anaesthesia. The lesions were excised utilizing anumber11scalpel blade (Figure 3)

On one-week follow up of areas were healing well. (Figure 4).

On one month follow up no pain or discomfort and no difficulty in eating were reported. (Figure 5).

On four months follow up of areas were heal completely (Figure 6).

Differential Diagnosis.

Table 2 includes most of the lesions that should be considered in the differential diagnosis of lesions. An attempt is made to order the lesions ranging from the most likely to the least likely to occur in this specific patient.(3)

Table 2

Lesion	Age	Sex	Site	Surface	Presentation	Radiograph	Incidence	Size
Fibroma	20+	F	Gingiva/Buccalmucosa	Smooth Keratinized	Pedunculatedorsessile	None	Common	1cm
Pyogenic Granuloma	20+	F	Gingiva	Ulcerated	Pedunculated	None	Common	2-3 Cm
Papilloma	30+	F	Lips,Tongue	Papillary	Pedunculated	None	Uncommon	Small
Peripheral Ossifying fibroma	10+	F	Interdental Papilla	Smooth Keratinized	Pedunculatedor Sessile	None	Rare	1cm
Giantcell fibroma	20	M/	Mandibular	Papillary	Pedunculatedor	None	Rare	1cm

	+	F	Gingiva		Sessile			
Peripheral Odontogenic fibroma	30+	F	Attached Gingiva	Smooth	Pedunculated or Sessile	None	Sometimes Uncommon	1-2cm
Peripheral Adenomatoid odontogenic Tumor	10+	M/F	Anterior Maxilla	Smooth Keratinized	Nodular Swelling	None	Rare	0.5-1cm
Peripheral Giantcell Granuloma	30+	F	Gingiva/Alveolar Ridge	Ulcerated	Pedunculated or Sessile	None	Rare	0.5-1cm
Neurofibroma	45+	M/F	Gingiva/ tongue	Smooth	Pedunculated or sessile	None	Rare	1-3cm
Lipoma	40+	M	buccalmucosa	Smooth Keratinized	Sessile	None	Uncommon	0.5-3cm
Peripheralameloblastoma	50+	M	Posterior gingival	Smooth or pebbly	Sessile	Sometimes	Veryrare	0.5-1cm
Intraoral neurilemoma	Anny	M/F	Tongue	Smooth Keratinized	Sessile	None	Uncommon	0.5-1cm
Peripheral calcifying Odontogenic cyst	60+	M	Anterior mandible	Smooth	Sessile	Erosion of bone	Veryrare	0.5-1cm

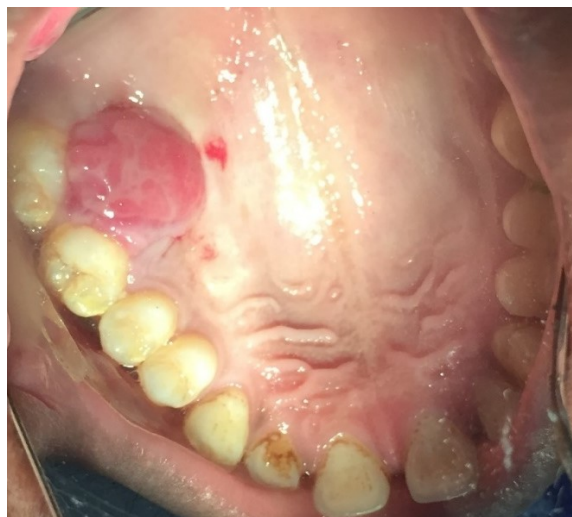

Figure 1

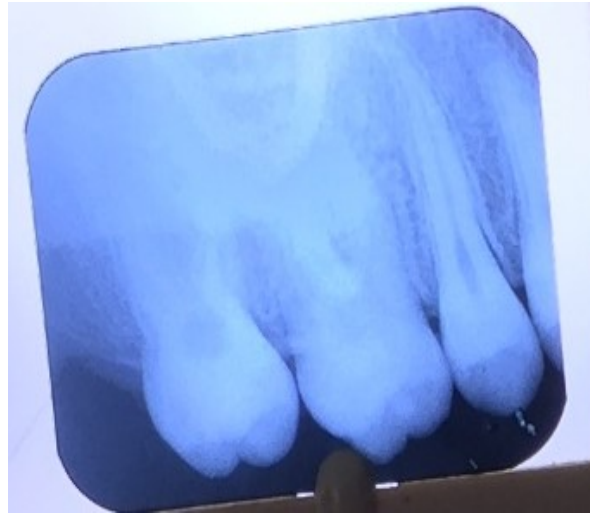

Figure 2

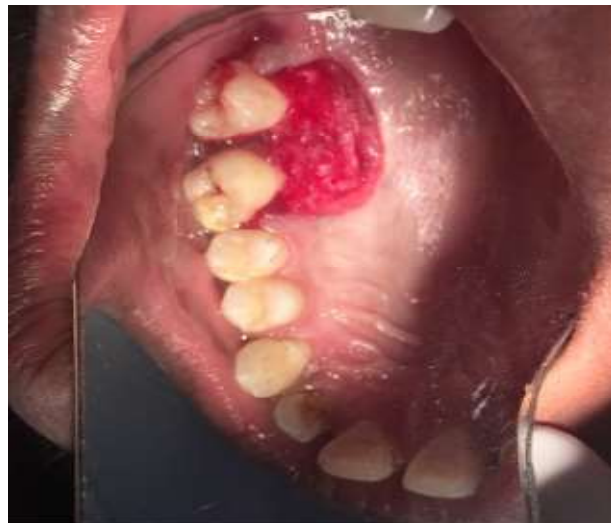

Figure 3

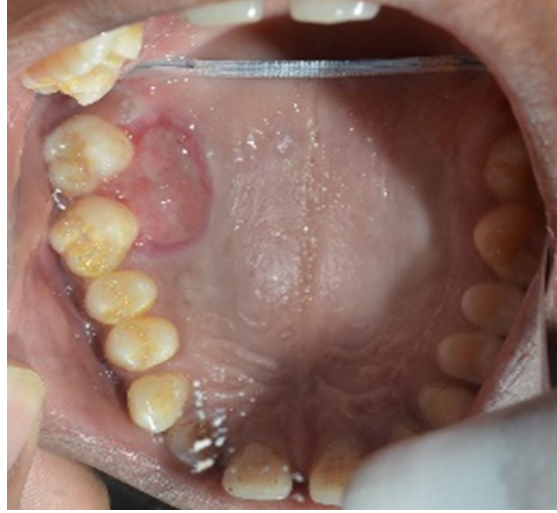

Figure 4

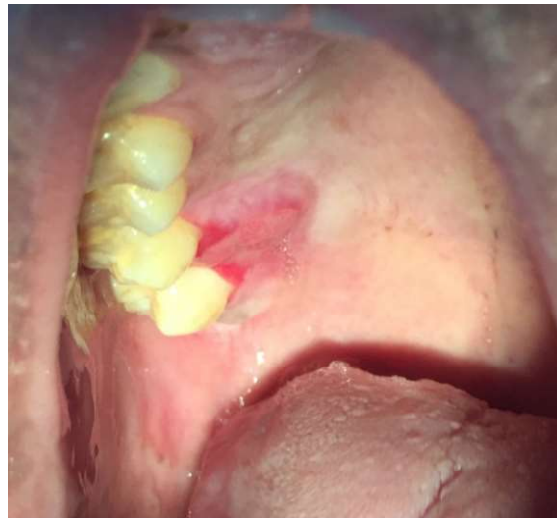

Figure 5

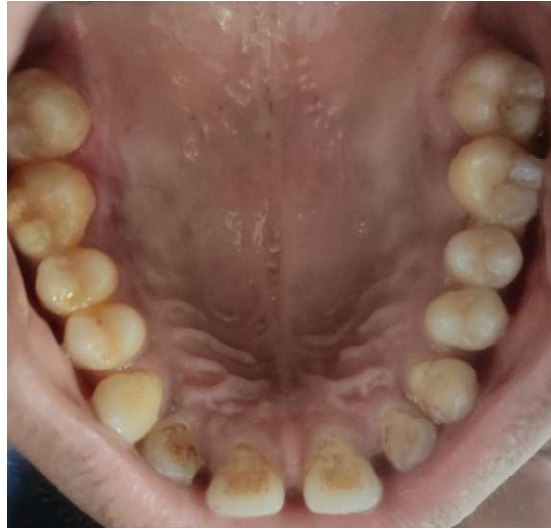

Figure 6

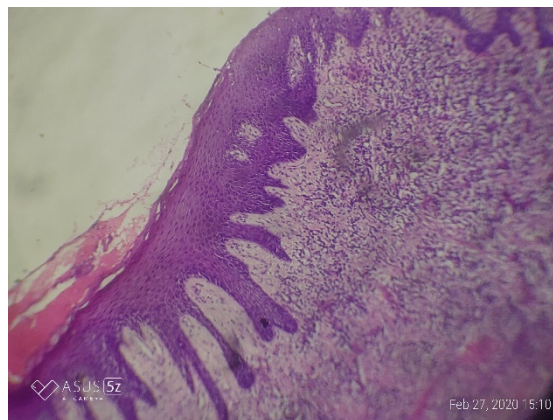


Figure 7

HISTOLOGY

The connective tissue stroma is fibrocellular which consist of haphazardly and densely arranged collagen fibres, numerous proliferating, plump fibroblast, numerous budding capillary, mild amount of chronic inflammatory cell infiltrate chiefly comprising of plasma cells, lymphocytes few blood vessels with intravasseted RBC are evident (figure 7)

DISCUSSION

The reactive lesions are commonly observed in the oral cavity due to the high frequency of tissue injuries and are clinically not easily distinguished. A review of 15,783 oral lesions during a 17.5-year period by Weir et al 1987 found that fibromas, periapical granulomas, mucocoeles, and radicular cysts were the most common reactive lesions observed in the oral cavity. It has been shown that 77% of lesions observed in the oral cavity are reactive in nature (4) Focal fibrous hyperplasia is also known as irritational fibroma, oral fibroma or as

fibromatosis fibroma.(5) Fibroma occurs as a result of a chronic repair process that includes granulation tissue and scar formation resulting in a submucosal fibrous mass. The size of these reactive hyperplastic masses may be greater or lesser depending on the degree to which one or more of the components of the inflammatory reaction and healing response are exaggerated in the particular lesion. Clinically, it is a sessile nodule of a few millimetres in diameter, soft and painless, that gradually gets hard and sometimes pedunculated. Colour may be similar to mucosa or vary depending on extent of inflammation. (4) It is generally isolated, round and is coincident with a gap in the dental arch. it is important to explain that FFH should be differentiated from an unusual non-neoplastic lesion of the oral cavity known as giant-cell fibroma(GCF). This lesion occurs most commonly on the tongue and gingiva, in the young patients, without sex predilection. Microscopically, CFG is composed of a non-inflamed fibrous connective tissue,with the presence of large stellate cells, usually with one or two nuclei, just beneath the epithelium. Multinucleated giant cells are seen occasionally(6) However, the giant cells are not exclusive of the CFG and can also be seen in other lesions, including FFH, looking to be part of the normal spectrum of tissue responses to injuries(7).Simple excision is the treatment of choice of FFH and recurrence is unlikely unless the inciting trauma continues or is repeated, as is observed in the present study. Of late, Trajtenberg and Adibi(8)have suggested that laser excision is an alternative for treating oral soft tissue lesions, including FFH, since it avoids the use of postoperative medications and accelerates the healing process

CONCLUSION

The fibrous hyperplasia is a very frequent type of benign connective tumor, usually easy to diagnose.Further studies are needed on the distribution of the lesions in different ethnic and geographical populations. The influence of sex hormones on the development of FFH must be clarified. The treatment modality of the gingival lesion is the removal of local irritants, and conservative complete excision of the lesion with regular follow-up to prevent recurrence.

REFERENCE

1. de Santana Santos T, Martins-Filho PR, Piva MR, de Souza Andrade ES. Focal fibrous hyperplasia: a review of 193 cases. *Journal of Oral and Maxillofacial Pathology: JOMFP*. 2014; 18(Suppl 1):S86.
2. Pardeshi KV, Mirchandani NM, Agrawal AA, Kale TM. Fibrous hyperplasia: Two case reports. *J Dent Lasers*. 2016; 10:23-7.
3. Vergotine RJ. A giant cell fibroma and focal fibrous hyperplasia in a young child: a case report. *Case reports in dentistry*. 2012; 2012.
4. Patil SR, Maheshwari S, Khandelwal S, Wadhawan R, Somashekar SB, Deoghare A. Prevalence of reactive hyperplastic lesions of the gingiva in the Western Indian population. *J Orofac Sci*. 2014; 6:41-5
5. Kale TA. Focal fibrous hyperplasia a reactive lesion. *Int. J. Dent. Clinics*. 2013; 5(3):29-30.
6. Kuo RC, Wang YP, Chen HM, Sun A, Liu BY, Kuo YS. Clinicopathological study of oral giant cell fibromas. *J Formos Med Assoc*. 2009; 108:725-9.
7. Odell E, Lock C, Lombardi T. Phenotypic characterisation of stellate and giant cells in giant cell fibroma by immunocytochemistry. *J Oral Pathol Med*. 1994; 23:284-7.

8. Trajtenberg C, Adibi S. Removal of an irritation fibroma using an Er. Cr: YSGG laser: A case report. Gen Dent. 2008; 56:648-51.