

## Dental Caries Detection: The State of the Art

Ghadah S. Aldossari<sup>1</sup>, Amerah A. Alasmari<sup>2</sup>, Mohammed S. Aldossary<sup>3</sup>

<sup>1</sup>Dental intern, Riyadh Elm University, Riyadh, Saudi Arabia

<sup>2</sup>Dental intern, Riyadh Elm University, Riyadh, Saudi Arabia

<sup>3</sup>Specialist in Pediatric Dentistry, Department of Dentistry, Ministry of Health, Riyadh, Saudi Arabia

### ARTICLE INFO



Keywords:

Dental caries; Caries detection;

Diagnostic methods; Clinical practice

### ABSTRACT

Dental caries detection is challenging for dental professionals, especially in early stages. Detection of incipient caries is important for prevention implementation, which will in turn make it possible to avoid the restoration of progressed caries. Various methods and techniques have been developed for caries detection and dental professionals must be familiar with such methods and diagnostic tools. This literature review provides an overview of current methods for caries detection.

### INTRODUCTION

Dental caries is a condition which results from a localized chemical dissolution of the tooth surface caused by acidic by-products from bacterial fermentation of dietary carbohydrates in the biofilm (dental plaque) covering the affected area. This destruction can affect enamel, dentin and cementum [1].

There are several caries classification criteria (Table 1). The simple standard American Dental Association

(ADA) caries classification system classified caries as initial (incipient), moderate and severe. The International Caries Detection and Assessment System (ICDAS) (Figure 1) was developed over years and has been found to be reliable and predictable, hence gaining international acceptance as the evolving caries diagnosis standard [2,3].

| ICDAS Lay Terms    | Sound              | Early Stage Decay             |                                  | Established Decay          |                           | Severe Decay                         |   |
|--------------------|--------------------|-------------------------------|----------------------------------|----------------------------|---------------------------|--------------------------------------|---|
| ICDAS Dental Terms | Sound              | First visual change in enamel | Distinct visual change in enamel | Localised enamel breakdown | Underlying dentine shadow | Distinct cavity with visible dentine | Extensive cavity within visible dentine |
| ICDAS Detection    | 0                  | 1                             | 2                                | 3                          | 4                         | 5                                    | 6                                       |
| ICDAS Activity     | ICDAS Activity +/- |                               |                                  |                            |                           |                                      |   |

**Fig 1: ICDAS caries assessment**

\* Corresponding author: Dr. Mohammed S. Aldossary, Specialist in Pediatric Dentistry, Department of Dentistry, Ministry of Health, Riyadh, Saudi Arabia

**Table 1:** Dental caries classification

| ICDAS System |  | ADA System             |   |
|--------------|--|------------------------|---|
| Code         | Description  | Stage                  | Extent  |
| 0            | Sound  | No caries              | Sound   |
| 1            | First visual change in enamel, only when surface is dried      | Initial Enamel Caries  | Visible non-cavitated lesion limited to enamel                  |
| 2            | Distinct visual change in enamel, observed when surface is wet | Moderate Dentin Caries | Enamel breakdown or moderate demineralized dentin               |
| 3            | Localized enamel breakdown with no visible dentin              | Severe Dentin Caries   | Enamel is fully cavitated with severe/deep demineralized dentin |
| 4            | Underlying dark shadow from dentin (+/- enamel breakdown)      |                        |   |
| 5            | Distinct cavity with visible dentin                            |                        |   |
| 6            | Extensive distinct cavity with visible dentin                  |                        |   |

Dental professionals should be familiar with several terminologies. Firstly, a white spot lesion is a carious lesion which has reached the stage where the net subsurface mineral loss has produced changes in the optical properties of enamel such that these are visibly detectable as a loss of translucency, thus resulting in a white appearance of the enamel surface. A cavitated lesion appears when the tooth surface is not macroscopically intact, with a distinct discontinuity or break in the surface integrity. An arrested or inactive caries lesion is a lesion which is not undergoing net mineral loss, i.e. the caries process in a specific lesion is no longer progressing [4–6].

The diagnosis of dental caries is extremely critical and challenging, especially in the very early stages or if it occurs on concealed surfaces. Early detection of caries is important in minimally invasive dentistry when it comes to implementing preventive measures to preserve the tooth structure so as to avoid the complications associated with the disease and/or the treatment [7]. Caries diagnosis is an important part of a dentist's daily work, and this three-step process comprises the detection

of the lesion, assessment of the severity of the lesion, and assessment of the activity of the lesion [8].

Various methods and equipment are available for the purposes of caries diagnosis and detection. Sensitivity and specificity are the most widely used statistics when it comes to describing a diagnostic test and quantifying the diagnostic ability of the test, including that used for dental caries. Sensitivity is the ability to detect a disease when it is present; the probability of a positive test among patients with a disease. In other words, sensitivity refers to the proportion of true positives that are correctly identified by the test [9]. Specificity is the ability to detect the absence of a disease when it is absent; the probability of a negative test among patients without a disease. Simply put, this pertains to the proportion of true negatives that are correctly identified by the test [10]. A false positive means that a test's result improperly indicates the presence of a condition, such as caries (the result is positive), when in reality it is not present. In contrast, a false negative means that a test's result improperly indicates no presence of the condition (the result is negative), when in reality it is present.

There are numerous different modalities for detecting caries, which will be discussed in this review.

### **1. 1. Visual and Tactile Detection**

This is the basic visual inspection of a tooth with good light and using a mirror. The tooth must be dry because minimally demineralized lesions (white spot lesions) will only become obvious once the tooth is dry. This is due to the fact that demineralized enamel is porous and the pores become water-logged, thus making early lesions less visible [8,11,12].

A probe can be run in the fissure pattern of the tooth to confirm the presence of cavitation. Neither enthusiastic probing of the fissure pattern of a tooth nor the use of a sharp explorer are recommended, as this can result in the possible transmission of cariogenic bacteria from one tooth to the other. This can also result in possible damage to the decalcified tooth tissue and increased demineralization [10,12–14]. For this reason, it is recommended that only ball-ended or blunt probes be used to assess the occlusal surface of the teeth to confirm the presence of cavitation [15].

The visual detection method is not effective for non-cavitated (hidden caries) and early lesions, with limited sensitivity but high specificity [16,17]; as such, this method should be used in conjunction with other detection methods [10,18]. Additionally, it is a subjective technique and provides less information on the severity of dental caries [19]. Occlusal surface morphology, anatomical fissure topography and stain or plaque presence would affect the visual caries detection [8,20].

The visual method is used for occlusal and smooth surface caries detection, although there is a limitation for proximal surfaces when contacts are present [10]. Proximal caries is particularly difficult to diagnose visually, and therefore radiographic examination is recommended when this is suspected. Alternatively, orthodontic separators placed in the contact surfaces

using floss or pliers may be used. This temporary tooth separation requires the patient to attend 5 to 7 days later for the removal of the separator and inspection of the proximal surface to assess for cavitation [21,22].

The visual exam can be aided by using magnification. When low powered magnification (3.25X) was compared to unaided vision on extracted teeth for occlusal and proximal caries, an increased sensitivity to detect caries with no difference in specificity was found [23]. Higher magnifications or the use of microscopic magnifications were also reported to increase the sensitivity of caries detection [7]. Intraoral camera is an alternative supportive tool for the visual examination, as it gives a 10X magnification with a larger viewing field [24].

### **2. Dental Radiographs**

Dental radiographs have disadvantages such as ionizing radiation and difficulty when being used with young children [16]. They are inadequate for detecting caries on the occlusal surfaces until the lesion is well advanced through the enamel and into the dentin [25]. Nonetheless, the bitewing radiograph offers excellent information about caries in the dentine under occlusal surfaces, especially for hidden caries, that is, radiographically visible dentin caries under a seemingly “sound” surface as judged from visual inspection [26,27]. Therefore, bitewing radiographs can be used to differentiate between demineralization that is confined to enamel, which is not usually visible in a radiograph, and caries, which extends into dentine.

The use of bitewing radiographs in addition to clinical visual examination increases the number of proximal lesions detected [28]. The broad contact points of the primary dentition make diagnosis of proximal caries difficult using clinical visual inspection alone; as such bitewings are an important adjunct to visual examination [29].

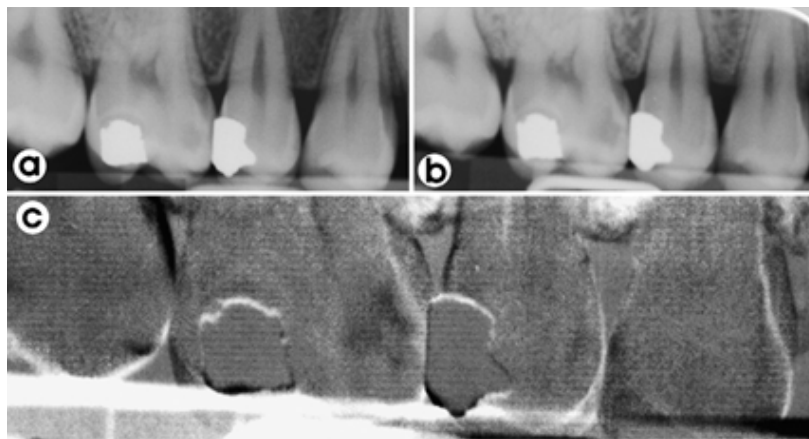
Extra-oral bitewing radiography is a new imaging technology used in dentistry. It generates fewer images of overlapping proximal surfaces, detecting more carious lesions (higher sensitivity) when compared to the conventional intra-oral bitewing radiographs. However, further research is needed as extra-oral bitewing has the disadvantage of more false-positive diagnoses (lower specificity) [30].

Dental panoramic radiographs (DPRs) can detect the presence of an occlusal dentine carious lesion when extended more in dentin, but are of much less value in the detection of proximal lesions [31]. Bimolar radiographs (lateral views) are not as useful as bitewings due to overlap of structures, but they can be of use in pre-cooperative children who do not tolerate bitewings and DPRs [32]. Periapical radiographs are as accurate as bitewings when it comes to caries diagnosis, although there is much less information available on any one film [31].

Digital radiographs have been found to give lower specificity and sensitivity than traditional radiographs, and thus their diagnostic yield is lower than that of

traditional radiographs [11]. However, with the advancement in technology, recent researches have reported that the detection capabilities of digital radiography are similar to those of film-based methods (especially E- and F-Speed films) [10,31]. Digital radiographs have the benefit of reduced radiation exposure as well as the ability to readily transfer the images [10]. In addition, with techniques such as enhancement, the diagnostic yield can be improved to match that of traditional radiographs, although such techniques are very time consuming [11].

The use of the subtraction radiographic method revealed an increase in accuracy and reproducibility compared to traditional visual assessment of the radiographs [10,33]. With this method, two radiographs of the same object must be perfectly aligned and the value of the pixels from the first object is subtracted from the second image [11]. The subtracted gray values indicate the progression of demineralization. However, this method has limited use in clinical practice due to the difficulty in producing two identical images (Figure 2) [7].



**Fig 2:** Example of subtraction radiographs. (a) proximal lesion on mesial surface of the first molar, (b) follow up radiograph (12 months later), (c) the areas of difference between the two images are shown as black (the proximal lesion has become more radiolucent, i.e. progressed) [11].

## **Review Article**

It is important to be aware that restorative material was found to have an influence on the diagnosis of secondary caries lesions by imaging. While the imaging system had no influence, materials with greater radiopacity, higher than enamel, were favorable for true-negative diagnosis [34,35].

It is recommended to use film holders to minimize incorrect film placement, bends in the film, and the loss of the relationship to the area of interest; indeed, this would help to further enhance the diagnostic validity of dental radiographs [32].

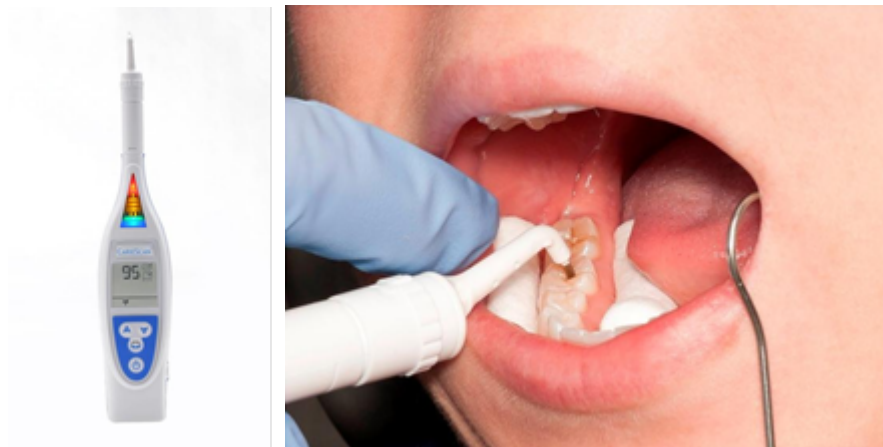### **3. Electronic Caries Monitor**

The electronic caries monitor, or electrical conductance measurement (ECM) can potentially detect caries through electrical resistance and conductance. The ECM

is used to screen the occlusal surface of posterior teeth for caries after applying a conducting medium [36].

The theory for the use of ECM holds that enamel is a good insulator but that during the carious process, porosities form in the tissue which fill with water and ions from saliva. These moisture-filled porosities act as conductive pathways causing resistance values to fall; the assumption is that carious enamel is more conductive than sound enamel [36].

The CarieScan PRO (CarieScan Ltd, Dundee, Scotland) (Figure 3) is an example device based on this theory; indeed due to its nature, it cannot be used on patients with a pacemaker, or when an amalgam filling is present [37].



**Fig 3:** The CarieScan PRO device (left) and its clinical application (right) (Source: <https://eclipse-dental.com>)

In the literature, it has been reported that ECM has high sensitivity in detecting occlusal caries, but with low specificity (high value of false-positive ratings), which may lead to overtreatment of sound molars [36,38]. Furthermore, the results from electronic devices can be confounded by the presence of moisture and hypoplastic areas [8,11]. Additionally, the thickness and structure of

tooth surfaces would affect the resistivity and conductivity of electrical signals. Therefore, substantial improvement of occlusal caries diagnosis might be achieved by combining this method with others [38].

### **4. Laser Fluorescence Technique**

\* Corresponding author: Dr. Mohammed S. Aldossary, Specialist in Pediatric Dentistry, Department of Dentistry, Ministry of Health, Riyadh, Saudi Arabia

Fluorescence is a process whereby light of a short wavelength is absorbed and is emitted back at a longer wavelength [39]. This amount of reflected light can be measured because light absorption is different for a carious tooth structure when compared to a sound tooth structure [40].

The most popular device is the DIAGNOdent device (KaVo, Biberach, Germany) (Figure 4), which is a caries detection system based on laser-stimulated fluorescence [41,42]. It measures the fluorescence of the tooth and bacterial by-products in the carious lesions, producing a digital reading as an outcome. The demineralized tooth structure exhibits elevated fluorescence, thus resulting in a higher scale reading [43]. The DIAGNOdent is suitable for use mainly on smooth surfaces and occlusal surfaces, and not routinely on proximal surfaces [17,44]. However, a recent study assessed the diagnostic accuracy of DIAGNOdent in comparison with bitewing radiographs and concluded that DIAGNOdent performed better in terms of diagnosing proximal caries [45]. A newer version of the product is the DIAGNOdent pen, which can be used for interproximal areas [46].



**Fig 4:** The Diagnodent device

False positive readings are generated by calculus, staining and hypoplasia [8,47]. This results in a positive reading interpreted as caries, while in actual fact caries is not present.

Although the DIAGNOdent showed higher validity, reproducibility and accuracy when compared to other methods, there were conflicting results regarding its sensitivity and specificity [48,49]. Overall, it tends to have better specificity than sensitivity for enamel lesions and better sensitivity than specificity for dentinal lesions [50,51].

The DIAGNOdent needs to be calibrated in the patient's mouth before it is used and has the disadvantage of high cost [43].

Consequently, it is recommended that the device not be relied on as the primary diagnostic method, and instead be used as a complementary method alongside other diagnostic methods to avoid false-positive diagnoses [17,44,52].

### 5. Fiber-Optic Transillumination

Fiber-optic transillumination (FOTI) is based on the principle that a sound tooth structure has a higher index of light transmission than that of a carious lesion, and so under a 0.5 mm visible light source on the tooth or in the embrasure [11,53], the photons are scattered when the tooth is demineralized; at the same time, the carious lesion shows up as a dark shadow (Figure 5) [10,54]. This procedure is more commonly used for proximal rather than occlusal caries [10,54].

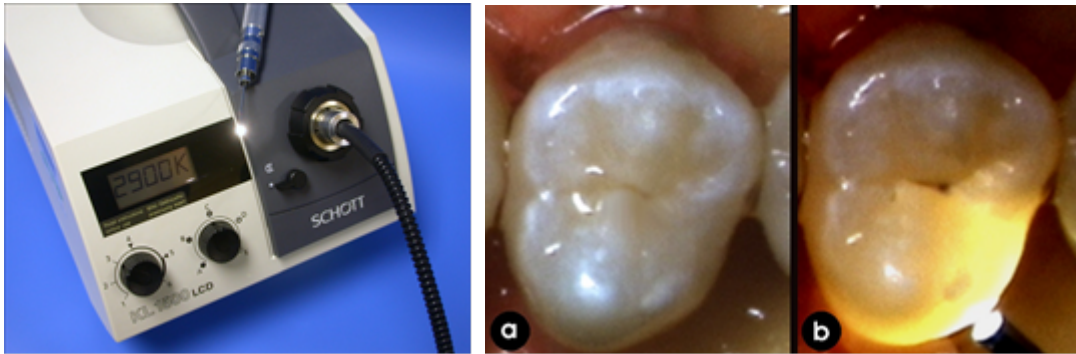


Fig 5: The FOTI device (left). An example of FOTI on a tooth. (a) Normal clinical vision, (b) with FOTI

Clinical results from studies evaluating the validity and effectiveness of FOTI are conflicting, with reports of low sensitivity [55,56], and comparable specificity [55], or higher specificity compared to radiographs [56]. In contrast, similar validity to visual inspection and higher sensitivity than radiography were also reported [57]. Digital FOTI (DiFOTI) has a built-in camera to enhance this concept further, thus increasing the sensitivity and enabling recording for documentation and monitoring purposes [9,58].

Recent evolution of the transillumination concept has led to the application of near-infrared (NIR) light to the field of caries detection as a further development of the DiFOTI. While the DiFOTI uses visible light, the NIR system uses invisible long-wave light [59]. It was reported that NIR has more advantages and produces a better contrast ratio, which significantly improves its diagnostic reliability [60–62]. The use of longer wave lengths is advantageous when it comes to decreasing light scattering, thus allowing for a deeper passage of the light through the tooth structure [63].

The CariVu (Dexis, Hatfield, PA, USA) uses the newer approach (NIR) to detect occlusal and interproximal carious lesions in addition to identifying cracks; moreover, it does not require a clean tooth surface or calibration [64].

Although promising results were reported, use of the CariVu may serve as an adjunct to other methods and further clinical studies are still needed [59,63].

#### 6. Quantitative Light-Induced Fluorescence (QLF)

Quantitative light-induced fluorescence (QLF) (Figure 6) is a visible light system that offers the opportunity to detect early caries and to then longitudinally monitor their progression or regression [25,65]. Fluorescence is a phenomenon whereby an object is excited by a particular wavelength of light and the reflected light is of a larger wavelength [50]. The resulting fluorescent image of a tooth is shown within the yellow-green spectrum of the visible light, quantifying the size of caries and the mineral loss [66].




Fig 6: The QLF unit light box, demonstrating the handpiece and liquid light guide (left); a close-up of the intra-oral camera featuring a disposable mirror tip (right).

Demineralization of enamel results in a reduction of this auto-fluorescence and appears darker than the sound tooth structure, which can be quantified and has been shown to correlate well with actual mineral loss (Figure 7). The source of the auto-fluorescence is thought to be the enamel dentinal junction (EDJ); as the excitation light passes through the transparent enamel it excites fluorophores contained within the EDJ. The QLF cannot be used interproximally [11].

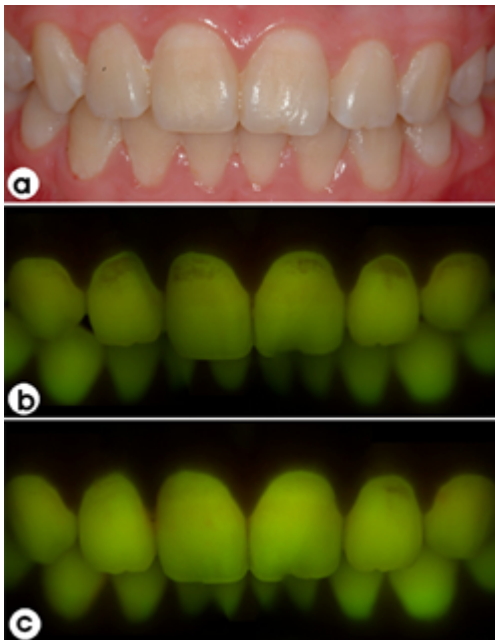


Fig 7: Analysis of lesion using QLF. (a) White buccal lesions effecting cervical of maxillary anterior teeth, (b)

QLF image taken at the same time as (a) showing the contrast, (c) 6 months after preventive practice showing the lesions have resolved [11].

### 7. Polarization-Sensitive Optical Coherence Tomography

Recently, the optical coherence tomography (OCT) dental imaging system has become a useful emerging technology for early caries detection and monitoring with qualitative and quantitative assessment.

The OCT uses differences in the reflectivity of the near infrared light when imaging teeth with confocal microscopy and low coherence interferometry, thus resulting in very high resolution images measuring approximately 10 to 20 microns. It enables the capturing of cross-sectional images, or tomographic slices, for imaging near-surface structures, up to 4 mm deep into dental tissue. The early mineral changes in teeth can be quantitatively assessed, and the volume and thickness of enamel residual can be calculated [67].

The OCT light is back-scattered by changes in the refractive index as the light encounters different tissue types or structures. To identify carious lesions, the increased light intensity of back-scattering near infrared light when compared to the sound structure indicates the lesion (i.e. reduction in enamel reflectivity due to mineral loss); moreover, the total intensity fluctuation in



depth direction evaluates the lesion's morphological depth [68].

The OCT has been shown to image early enamel caries lesions [68], and root lesions [67], by monitoring the development and progression of carious lesions and determining lesion depth, surface integrity and amount of mineral loss. Surface defects, cracks and fissures can be detected by the OCT device, which is also capable of detecting recurrent decay around restorations and examining the marginal integrity of restorations bonded to the tooth structure.

In addition, tooth staining and the presence of dental plaque and calculus do not appear to adversely affect the accuracy of OCT imaging [67].

When the OCT was combined with Raman spectroscopy, an increase in the accuracy and biochemical confirmation of incipient caries lesions was reported; this presented a new detection method with high sensitivity and specificity that would improve caries management and patient care [68].

## 8. Other New Methods

There are several other techniques and devices used for detecting early caries in their infancy and many are laboratory-based. Nonetheless, such technologies may prove useful in the future [7,9].

One particularly innovative technique is laser speckled imaging through coherent light scattering pattern speckle for the detection of incipient caries lesions based on changes in the microstructure of the surface of tooth enamel [69]. The use of ultrasound in caries detection has also been undertaken in a number of studies with contradictory results [70,71]. The properties of the sound waves reflected indicate the position of the reflecting interface and its structure [71]. Multiphoton imaging by microscopy is a powerful tool for assessing detailed morphological features, such as dentinal tubules and enamel rods; this imaging provides an important

potential and valuable application in caries diagnosis [72]. The use of photothermal radiometry and modulated luminescence (frequency-domain infrared light) for caries detection was investigated for occlusal surfaces [73], and interproximal surfaces [74]. This system detects changes and differences in luminescence and temperature to quantify the mineralization changes, and showed promising results, although further research is needed [75]. The Canary System (Quantum Dental Technologies Inc., Ontario, Canada) is an example of this technology.

Finally, instead of a laser, several studies have used a light emitting diode (LED) to measure the caries reflection signature [7]. The Spectra Caries Detection Aid System (Air Techniques, Inc., Melville, NY, USA) is another fluorescence-based caries detection system. The technology used is similar to that of the DIAGNOdent, but uses six LEDs to project a blue-violet light to detect and analyze caries. Spectra can detect recurrent caries around existing restorations [40].

Other new devices such as Soprolife (Acteon Imaging, La Ciotat, France), and the Midwest Caries ID (DENTSPLY Professional, York, PA, USA), are based on the LED technologies [76,77].

The advanced methods provide promising results in terms of the detection of both early caries as well as caries occurring on all surfaces of the tooth. Each caries detection tool has advantages and disadvantages, with some performing better on certain surfaces than others [38]. Newer diagnostic methods which are still being researched may prove to be very effective for the early detection of caries in the near future; indeed, this will improve the dentist's ability to detect caries at an earlier stage. It is anticipated that these enhancements will result in the establishment of improved protocols for caries intervention and treatment [9].

## 9. CONCLUSIONS

A major disadvantage of most of these techniques is the limitation of activity assessment, as they do not indicate whether the lesion is active or arrested. Devices with the ability to save images electronically would also have the ability to monitor caries and remineralization with follow up. When two or three methods are used in combination, there is a higher detection of caries with increased accuracy. More advancement in technologies and further research are needed to confirm validity and achieve cost-effective detection and quantification of dental caries.

Dental professionals can halt or reverse the caries process by detecting caries in its earliest stage, thereby avoiding invasive intervention and preserving the natural dentition. New caries diagnostic technologies aid in the support of minimally invasive dentistry and allow remineralization efforts to be employed. Dental professionals should become familiar with caries detection devices and help raise the standard of dental care.

**10. Acknowledgments:** None

**11. Conflicts of Interest:** The authors declare no conflict of interest.

## 12. REFERENCES

1. Fejerskov O. Concepts of dental caries and their consequences for understanding the disease. *Community Dent Oral Epidemiol.* 1997; 25:5-12.
2. Ismail AI, Sohn W, Tellez M, Amaya A, Sen A, Hasson H et al. The International Caries Detection and Assessment System (ICDAS): an integrated system for measuring dental caries. *Community Dent Oral Epidemiol.* 2007; 35:170-8.
3. Zero DT. Dental caries process. *Dent Clin North Am.* 1999; 43:635-64.
4. Fontana M, Zero DT. Assessing patients' caries risk. *J Am Dent Assoc.* 2006; 137:1231-9.
5. Petersen PE, Bourgeois D, Ogawa H, Estupinan-Day S, Ndiaye C. The global burden of oral diseases and risks to oral health. *Bull World Health Organ.* 2005; 83:661-9.
6. Baelum V, Heidmann J, Nyvad B. Dental caries paradigms in diagnosis and diagnostic research. *Eur J Oral Sci.* 2006; 114:263-77.
7. Mohanraj M, Prabhu VR, Senthil R, others. Diagnostic methods for early detection of dental caries-A review. *Int J Pedod Rehabil.* 2016; 1:29-36.
8. Ekstrand KR, Ricketts DN, Kidd EA. Occlusal caries: pathology, diagnosis and logical management. *Dent Update.* 2001; 28:380-7.
9. Gomez J. Detection and diagnosis of the early caries lesion. *BMC Oral Health.* 2015; 15:S3.
10. Manton D. Diagnosis of the early carious lesion. *Aust Dent J.* 2013; 58:35-9.
11. Pretty IA. Caries detection and diagnosis: novel technologies. *J Dent.* 2006; 34:727-39.
12. Zandoná AF, Zero DT. Diagnostic tools for early caries detection. *J Am Dent Assoc.* 2006; 137:1675-84; quiz 1730.
13. Yassin OM. In vitro studies of the effect of a dental explorer on the formation of an artificial carious lesion. *ASDC J Dent Child.* 1995; 62:111-7.
14. Stookey G. Should a dental explorer be used to probe suspected carious lesions? No-use of an explorer can lead to misdiagnosis and disrupt remineralization. *J Am Dent Assoc.* 2005; 136:1527, 1529, 1531.
15. Kühnisch J, Dietz W, Stösser L, Hickel R, Heinrich-Weltzien R. Effects of Dental Probing on Occlusal Surfaces – A Scanning Electron Microscopy Evaluation. *Caries Res.* 2007; 41:43-8.
16. Ashley P. Diagnosis of occlusal caries in primary teeth. *Int J Paediatr Dent.* 2000; 10:166-71.

17. Zaidi I, Somani R, Jaidka S, Nishad M, Singh S, Tomar D. Evaluation of different Diagnostic Modalities for Diagnosis of Dental Caries: An in vivo Study. *Int J Clin Pediatr Dent.* 2016; 9:320-5.
18. Yip K, Smales R. Oral diagnosis and treatment planning: part 2. Dental caries and assessment of risk. *BDJ.* 2012; 213:59-66.
19. Baelum V. What is an appropriate caries diagnosis? *Acta Odontol Scand.* 2010; 68:65-79.
20. Manton DJ, Messer LB. The effect of pit and fissure sealants on the detection of occlusal caries in vitro. *Eur Arch Paediatr Dent.* 2007; 8:43-8.
21. Pitts NB, Longbottom C. Temporary tooth separation with special reference to the diagnosis and preventive management of equivocal approximal carious lesions. *Quintessence Int.* 1987; 18:563-73.
22. Coutinho TC, daRocha Costa C. An in vivo comparison of radiographic and clinical examination with separation for assessment of approximal caries in primary teeth. *Eur J Paediatr Dent.* 2014; 15:371-4.
23. Forgie AH, Pine CM, Pitts NB. The use of magnification in a preventive approach to caries detection. *Quintessence Int.* 2002; 33:13-6.
24. Erten H, Uçtasli MB, Akarslan ZZ, Uzun O, Baspinar E. The assessment of unaided visual examination, intraoral camera and operating microscope for the detection of occlusal caries lesions. *Oper Dent.* 2005; 30:190-4.
25. Tranaeus S, Shi X-Q, Angmar-Mansson B. Caries risk assessment: methods available to clinicians for caries detection. *Community Dent Oral Epidemiol.* 2005; 33:265-73.
26. Espelid I, Mejåre I, Weerheijm K, EAPD. EAPD guidelines for use of radiographs in children. *Eur J Paediatr Dent.* 2003; 4:40-8.
27. Alwayli H, Alshiha S, Alfrah Y, Hattan M, Alamri A, Aldossary M. A survey of fissure sealants and dental caries prevalence in the first permanent molars among primary school girls in Riyadh, Saudi Arabia. *Eur J Dent.* 2017; 11:455.
28. Haak R, Wicht MJ. Grey-scale reversed radiographic display in the detection of approximal caries. *J Dent.* 2005; 33:65-71.
29. Kidd EA, Pitts NB. A reappraisal of the value of the bitewing radiograph in the diagnosis of posterior approximal caries. *Br Dent J.* 1990; 169:195-200.
30. Chan M, Dadul T, Langlais R, Russell D, Ahmad M. Accuracy of extraoral bite-wing radiography in detecting proximal caries and crestal bone loss. *J Am Dent Assoc.* 2017; 17:30788-2.
31. Alkurt MT, Peker I, Bala O, Altunkaynak B. In vitro comparison of four different dental X-ray films and direct digital radiography for proximal caries detection. *Oper Dent.* 2007; 32:504-9.
32. Pierro VS da S, Barcelos R, de Souza IPR, Raymundo RJ. Pediatric bitewing film holder: preschoolers' acceptance and radiographs' diagnostic quality. *Pediatr Dent.* 2008; 30:342-7.
33. Ricketts DNJ, Ekstrand KR, Martignon S, Ellwood R, Alatsaris M, Nugent Z. Accuracy and reproducibility of conventional radiographic assessment and subtraction radiography in detecting demineralization in occlusal surfaces. *Caries Res.* 2007; 41:121-8.
34. Pedrosa R, Brasileiro I, dos Anjos Pontual M, dos Anjos Pontual A, da Silveira M. Influence of materials radiopacity in the radiographic diagnosis of secondary caries: evaluation in film and two digital systems. *Dentomaxillofacial Radiol.* 2011; 40:344-50.
35. Cruz A, Esteves R, Poiate I, Portero P, Almeida S. Influence of Radiopacity of Dental Composites on the Diagnosis of Secondary Caries: The Correlation

- Between Objective and Subjective Analyses. *Oper Dent.* 2014; 39:90-7.
36. Ashley PF, Ellwood RP, Worthington H V, Davies RM. Predicting occlusal caries using the Electronic Caries Monitor. *Caries Res.* 2000; 34:201-3.
  37. Tassery H, Levallois B, Terrer E, Manton DJ, Otsuki M, Koubi S et al. Use of new minimum intervention dentistry technologies in caries management. *Aust Dent J.* 2013; 58(1):40-59.
  38. Twetman S, Axelsson S, Dahlén G, Espelid I, Mejåre I, Norlund A et al. Adjunct methods for caries detection: A systematic review of literature. *Acta Odontol Scand.* 2013; 71:388-97.
  39. Tam LE, McComb D. Diagnosis of occlusal caries: Part II. Recent diagnostic technologies. *J Can Dent Assoc.* 2001; 67:459-63.
  40. Graye M, Markowitz K, Strickland M, Guzy G, Burke M, Houpt M. In vitro evaluation of the Spectra early caries detection system. *J Clin Dent.* 2012; 23:1-6.
  41. Bader JD, Shugars DA. A systematic review of the performance of a laser fluorescence device for detecting caries. *J Am Dent Assoc.* 2004; 135:1413-26.
  42. Nassur C, Pomarico L, Maia LC. Reliability analysis of two methods for measuring active enamel demineralization: An in vitro study. *Eur J Dent.* 2013; 7:159-64.
  43. Aleksejuniene J, Tranaeus S, Skudutyte-Rysstad R. Diagnodent - An adjunctive diagnostic method for caries diagnosis in epidemiology. *Community Dent Health.* 2006; 23:217-21.
  44. Shwetha G, Chandra P, Anandakrishna L, Dhananjaya G, Shetty AK, Kamath PS. Validation of different diagnostic aids in detection of occlusal caries in primary molars: An in vitro study. *J Indian Soc Pedod Prev Dent.* 2017; 35:301-6.
  45. Menem R, Barnkggei I, Beiruti N, Al Haffar I, Joury E. The diagnostic accuracy of a laser fluorescence device and digital radiography in detecting approximal caries lesions in posterior permanent teeth: an in vivo study. *Lasers Med Sci.* 2017; 32:621-8.
  46. Kühnisch J, Bücher K, Hickel R. The intra/inter-examiner reproducibility of the new Diagnodent Pen on occlusal sites. *J Dent.* 2007; 35:509-12.
  47. Nokhbatolfoghahaie H, Alikhasi M, Chiniforush N, Khoei F, Safavi N, Yaghoub Zadeh B. Evaluation of Accuracy of DIAGNOdent in Diagnosis of Primary and Secondary Caries in Comparison to Conventional Methods. *J Lasers Med Sci.* 2013; 4:159-67.
  48. Shi X-Q, Welander U, Angmar-Månsson B. Occlusal Caries Detection with KaVo DIAGNOdent and Radiography: An in vitro Comparison. *Caries Res.* 2000; 34:151-8.
  49. Apostolopoulou D, Lagouvardos P, Kavvadia K, Papagiannoulis L. Histological validation of a laser fluorescence device for occlusal caries detection in primary molars. *Eur Arch Paediatr Dent.* 2009; 10:11-5.
  50. Attrill D, Ashley P. Occlusal caries detection in primary teeth: a comparison of DIAGNOdent with conventional methods. *Br Dent J.* 2001; 190:440-3.
  51. Goel A, Chawla H, Gauba K, Goyal A. Comparison of validity of DIAGNOdent with conventional methods for detection of occlusal caries in primary molars using the histological gold standard: An in vivo study. *J Indian Soc Pedod Prev Dent.* 2009; 27:227.
  52. Kavvadia K, Lagouvardos P, Apostolopoulou D. Combined validity of DIAGNOdent™ and visual examination for in vitro detection of occlusal caries in primary molars. *Lasers Med Sci.* 2012; 27:313-9.

53. Chawla N, Messer LB, Adams GG, Manton DJ. An in vitro comparison of detection methods for approximal carious lesions in primary molars. *Caries Res.* 2012; 46:161-9.
54. Bin-Shuwaish M, Yaman P, Dennison J, Neiva G. The correlation of DIFOTI to clinical and radiographic images in Class II carious lesions. *J Am Dent Assoc.* 2008; 139:1374-81.
55. Vaarkamp J, ten Bosch JJ, Verdonschot EH, Bronkhorst EM. The real performance of bitewing radiography and fiber-optic transillumination in approximal caries diagnosis. *J Dent Res.* 2000; 79:1747-51.
56. Bader JD, Shugars DA, Bonito AJ. A systematic review of the performance of methods for identifying carious lesions. *J Public Health Dent.* 2002; 62:201-13.
57. Côrtes DF, Ekstrand KR, Elias-Boneta AR, Ellwood RP. An in vitro comparison of the ability of fibre-optic transillumination, visual inspection and radiographs to detect occlusal caries and evaluate lesion depth. *Caries Res.* 2000; 34:443-7.
58. Astvaldsdóttir A, Ahlund K, Holbrook WP, de Verdier B, Tranæus S. Approximal Caries Detection by DIFOTI: In Vitro Comparison of Diagnostic Accuracy/Efficacy with Film and Digital Radiography. *Int J Dent.* 2012; 2012:326401.
59. Baltacioglu IH, Orhan K. Comparison of diagnostic methods for early interproximal caries detection with near-infrared light transillumination: an in vivo study. *BMC Oral Health.* 2017; 17:130-6.
60. Simon JC, Lucas S, Lee R, Darling CL, Staninec M, Vanderhobli R et al. In-vitro near-infrared imaging of natural secondary caries. In: Rechmann P, Fried D, editors. *Proc. SPIE--the Int. Soc. Opt. Eng.* 2015; 9306:93060F.
61. Maia AMA, Karlsson L, Margulis W, Gomes ASL. Evaluation of two imaging techniques: near-infrared transillumination and dental radiographs for the detection of early approximal enamel caries. *Dentomaxillofacial Radiol.* 2011; 40:429-33.
62. Usenik P, Bürmen M, Fidler A, Pernuš F, Likar B. Near-infrared hyperspectral imaging of water evaporation dynamics for early detection of incipient caries. *J Dent.* 2014; 42:1242-7.
63. Kühnisch J, Söchtig F, Pitchika V, Laubender R, Neuhaus KW, Lussi A et al. In vivo validation of near-infrared light transillumination for interproximal dentin caries detection. *Clin Oral Investig.* 2016; 20:821-9.
64. Karlsson L. Caries Detection Methods Based on Changes in Optical Properties between Healthy and Carious Tissue. *Int J Dent.* 2010; 2010:1-9.
65. Angmar-Månsson B, Ten Bosch JJ. Quantitative light-induced fluorescence (QLF): a method for assessment of incipient caries lesions. *Dentomaxillofac Radiol.* 2001; 30:298-307.
66. Stookey GK. Quantitative Light Fluorescence: A Technology for Early Monitoring of the Caries Process. *Dent Clin North Am.* 2005; 49:753-70.
67. Amaechi BT, Podoleanu AG, Komarov G, Higham SM, Jackson DA. Quantification of root caries using optical coherence tomography and microradiography: a correlational study. *Oral Health Prev Dent.* 2004; 2:377-82.
68. Ngaotheppitak P, Darling CL, Fried D. Measurement of the severity of natural smooth surface (interproximal) caries lesions with polarization sensitive optical coherence tomography. *Lasers Surg Med.* 2005; 37:78-88.
69. Oliván SRG, Deana AM, Pinto MM, Sfalcin RA, Fernandes KPS, Mesquita-Ferrari RA, et al. Diagnosis of occlusal caries lesions in deciduous molars by coherent light scattering pattern speckle. *Photodiagnosis Photodyn Ther.* 2017; 18:221-5.

70. Wenzel A. Radiographic display of carious lesions and cavitation in approximal surfaces: Advantages and drawbacks of conventional and advanced modalities. *Acta Odontol Scand.* 2014; 72:251-64.
71. Hall A, Girkin JM. A review of potential new diagnostic modalities for caries lesions. *J Dent Res.* 2004; 83:C89-94.
72. Lin P-Y, Lyu H-C, Hsu C-YS, Chang C-S, Kao F-J. Imaging carious dental tissues with multiphoton fluorescence lifetime imaging microscopy. *Biomed Opt Express.* 2010; 2:149-58.
73. Jeon RJ, Han C, Mandelis A, Sanchez V, Abrams SH. Diagnosis of pit and fissure caries using frequency-domain infrared photothermal radiometry and modulated laser luminescence. *Caries Res.* 2004; 38:497-513.
74. Jeon RJ, Matvienko A, Mandelis A, Abrams SH, Amaechi BT, Kulkarni G. Interproximal dental caries detection using Photothermal Radiometry (PTR) and Modulated Luminescence (LUM). *Eur Phys J Spec Top.* 2008; 153:467-9.
75. Hellen A, Mandelis A, Finer Y, Amaechi BT. Quantitative evaluation of the kinetics of human enamel simulated caries using photothermal radiometry and modulated luminescence. *J Biomed Opt.* 2011; 16:071406.
76. Rechmann P, Rechmann BMT, Featherstone JDB. Caries detection using light-based diagnostic tools. *Compend Contin Educ Dent.* 2012; 33:582-4, 586, 588-93; quiz 594, 596.
77. Rodrigues JA, Hug I, Neuhaus KW, Lussi A. Light-emitting diode and laser fluorescence-based devices in detecting occlusal caries. *J Biomed Opt.* 2011; 16:107003.