

Case Report

Modified Impression Techniques for Management of Flabby Ridges – A Series of Case Reports

Syeda A Haseeba¹, Vinaya KC², Naveen YG³, Puttaraj Tukaram Kttimani⁴, Roshini V Nair⁵

¹Senior lecturer, Dept of Prosthodontics, Sharavathi Dental College and Hospital

²Private practitioner, Tirthalli

³Professor, Dept of Prosthodontics, Sharavathi Dental College and Hospital

⁴Professor, Dept of Prosthodontics, Sharavathi Dental College and Hospital

⁵Private practitioner, Trivendruml

ARTICLE INFO



Keywords:

Flabby tissue, impression techniques, impression plaster, ZOË impression paste

ABSTRACT

A flabby ridge is a superficial area of mobile soft tissue affecting the maxillary or mandibular alveolar ridges. It is a condition, where alveolar bone is replaced by hyperplastic soft tissue and is a common finding, particularly in the upper anterior region of long term denture wearers. Recording hyperplastic soft tissue with conventional impression techniques will lead to inflammation of soft tissues and instability of dentures. So a careful and special management of flabby tissue is required to have a denture with good support, retention and stability. The purpose of this article is to describe four different modified impression techniques used in patients with flabby alveolar ridges.

INTRODUCTION

The success of complete denture therapy lies in the precise execution of treatment plan inferred by evaluation of complete history and thorough clinical examination. Always precise treatment plan must be based on Devan's principle that "preservation of what already exists than the mere replacement of what is missing". A flabby ridge is common condition which poses a clinical challenge towards the fabrication of successful prosthesis. It is found in patients who wear a complete dentures for long period of time and also in patients where edentulous arch either maxillary or mandibular arch opposing a dentulous arch. It can develop when hyperplastic soft tissue replaces the alveolar bone. Flabby ridge is believed to occur with a

condition called Combination syndrome.^[1-2] Kelly, in 1972, first described 'combination syndrome' based on the observations of six patients followed up over a period of three years. Each patient wore a complete maxillary denture opposed by mandibular teeth and a distal extension removable partial denture. His observations included alveolar bone resorption in the anterior maxilla, enlargement of the tuberosities and bone resorption underneath the mandibular denture bases³. In literature it is observed that occurrence of flabby ridge up to 24% of edentulous maxillae, and in 5% of edentulous mandible, and in both jaws most frequently in the anterior region⁴. Historically it was thought that flabby ridges found in anterior maxilla were a feature of combination syndrome and occur as a result of maxillary complete

* Corresponding author: Dr. Syeda Amtul Haseeba, Senior Lecturer, Dept of Prosthodontics, Sharavathi Dental College & Hospital, Shivamogga, Karnataka

denture opposing a mandibular anterior natural teeth without proper posterior occlusal support. It might also occur due to unplanned and uncontrolled dental extractions.⁵ Conventional impression techniques displace the flabby tissues and get compressed during impression making. These compressed flabby tissues tend to get recoil and cause dislodgement of overlying denture. The lesser resilient tissues can displace the dentures under masticatory load leading to loss of peripheral seal causing poor retention of the denture. Unless managed appropriately, such 'flabby ridges' adversely affect the support, retention and stability of complete dentures¹. The three main approaches to manage flabby ridge are:

1. Surgical removal of fibrous tissue prior to conventional prosthodontics
2. Implant retained prosthesis – Fixed or Removable
3. Conventional prosthodontics without surgical intervention.

Each management technique has its advantages and disadvantages. Surgical technique provides a firm denture bearing area but there are chances of decrease in vestibular height requiring an additional surgery of vestibuloplasty. Besides patients may not be willing to undergo a surgical treatment. Implant supported prosthesis can be a other good option, but cost factor and surgical intervention for placing implants and duration of treatment may limit to choose this mode of treatment for managing flabby tissue¹.

Conventional prosthetic management includes a multitude of impression techniques to record denture-bearing areas. To record flabby areas a special technique is required which will compress the nonflabby tissues to obtain optimal support, at the same time, will not displace the flabby tissues⁵. In this article a series of case

reports is presented which describes the various modified impression techniques, used to treat the patients with flabby ridges who reported to department of Prosthodontics, Sharavathi Dental college & Hospital, Shivamogga

CASE REPORT 1

A male patient named Subhash Chandra shetty, aged 66 years reported to the department of Prosthodontics with a chief complaint of ill fitting denture. The patient was a denture wearer from past 10 years and described the existing dentures as "loose" with difficulty in speech. On examination the patient was completely edentulous with flabby tissues on the lower anterior region [Fig.1]. All possible treatment options were explained to the patient. As he opted for nonsurgical procedure, new set of complete dentures fabricated, paying special attention towards impression technique. It was decided to use One part impression Technique (Selective perforation tray technique) for this patient. This technique will be adopted when the degree of displacement of flabby tissues is minimum. In this technique preliminary impression was made with mucostatic impression material, irreversible hydrocolloid alginate material. [Fig. 2]. Special tray was fabricated after applying spacers. After border moulding, perforations made around the flabby areas which helps to minimize displacement of soft tissues [Fig. 3& 4]. Final impression was made with low viscosity polyvinylsiloxane impression material [Fig.5].

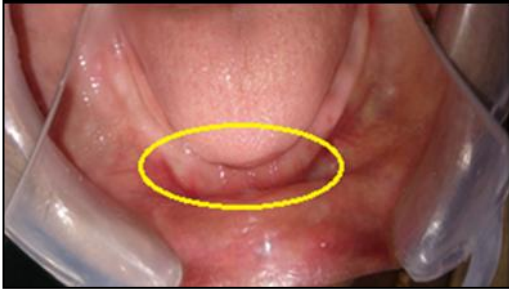

Fig. 1: Intra oral view

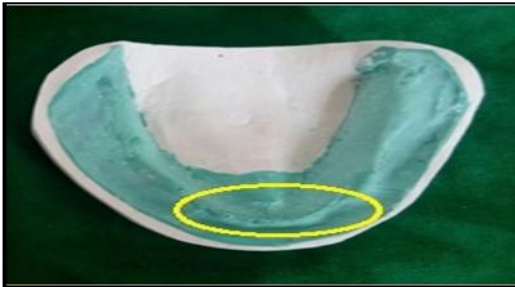


Fig. 2: Primary cast

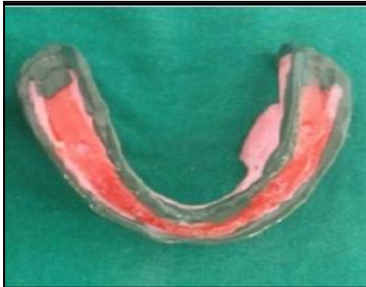

Fig. 3: Border molding done

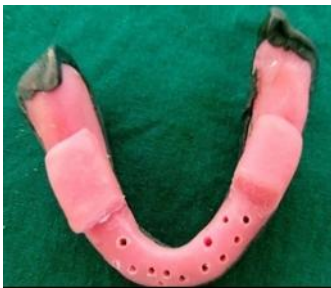

Fig. 4: Perforations done on special tray which covers flabby areas

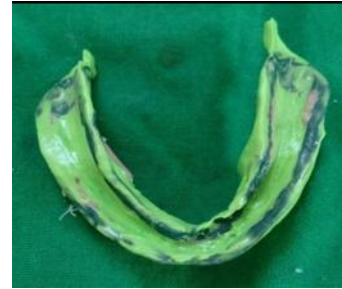

Fig. 5: Final impression with PVS light body

CASE REPORT 2

A male patient named Eshwarappa, aged 80yrs, reported to the department of Prosthodontics with a chief complaint of loose dentures and difficulty in speech with the dentures. On examination, patient was completely edentulous with flabby tissue in anterior region of maxillary arch. After recording the complete history and thorough clinical examination, it was planned for recording the flabby ridges with palatal splinting with two part tray system. In this technique two overlaying trays are used for recording displaceable tissues [Fig: 6, 7]. The trays are fabricated with a wax spacer to record palatal area. A small locating rod is placed over the first tray and a hole is placed on the second tray [Fig: 8]. This helps for orientation of trays in the mouth. Border molding is done to record posterior non flabby areas and secondary impression made with zinc oxide eugenol material. The second part of the tray is now placed so that it passes through the orientation rod and borders are recorded. Final impression of flabby area is recorded using addition silicone so that flabby areas are recorded with minimum displacement [Fig: 9].

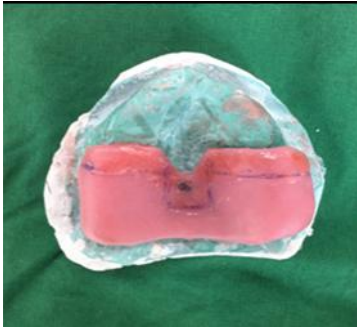


Fig. 6: Custom tray

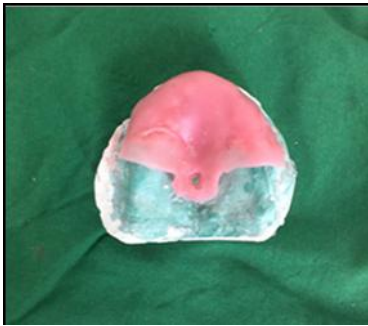


Fig. 7: Pickup tray

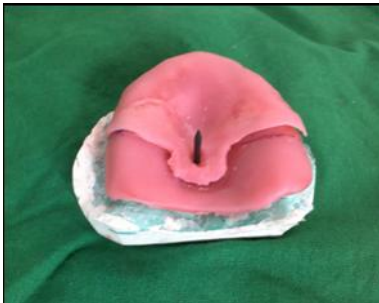

Fig. 8: Locating rod placed during fabrication




Fig. 9: Final impression made with ZOE and PVS light body

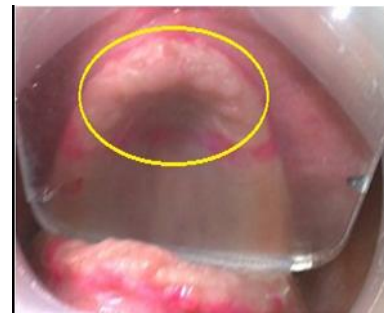

Fig. 10: Intra oral picture with marked flabby

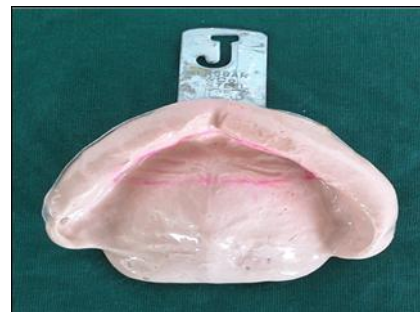

Fig. 11: Mucostatic Alginate impression

CASE REPORT 3

A female patient named Parvathamma aged 65yrs, reported to the department of prosthodontics with a chief complaint of loose upper denture which was fabricated 12yrs back. On examination patient was completely edentulous with flabby tissue in anterior maxillary arch [Fig-10]. Treatment plan was to fabricate conventional complete denture with selective impression compound flammung technique. Primary impression was made with irreversible hydrocolloid impression material[Fig-11]. A spacer of 3-4mm width is adapted over the primary cast and custom tray was fabricated [Fig-12]. Secondary impression is made over primary cast using impression compound [Fig-13]. Borders were refined by careful softening and functional trimming of the impression compound so that flabby areas recorded in pressure less method and master cast was obtained [Fig-14].




Fig. 12: Primary cast with special tray

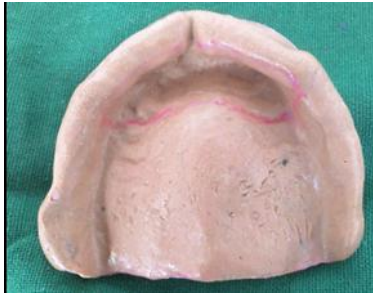

Fig. 13: Impression made over primary cast




Fig. 14: Master Cast obtained after Refining the Borders

CASE REPORT 4

A female patient by name Vasanta aged 60 years reported to the department of Prosthodontics with a chief complaint of missing teeth in upper and lower arches. The patient was a denture wearer for the last 15 years and described the existing dentures as “loose.” On examination the patient was completely edentulous with flabby tissues in both maxillary and mandibular anterior region [Fig-15]. After recording the complete history and thorough examination, it was planned for recording the flabby ridges with Two part impression technique:

Mucostatic and mucodisplacive combination or window technique. In this technique primary impression is made with irreversible hydrocolloid impression material. Flabby areas are marked in the oral cavity and transferred it to the primary cast. Custom tray is fabricated by creating a window opening over the flabby areas [Fig-16]. Border molding and secondary impression are made using zinc oxide eugenol impression material keeping the flabby areas left unrecorded. Now the tray is placed back over the maxillary arch and flabby areas are recorded using plaster supported with gauze [Fig-17].

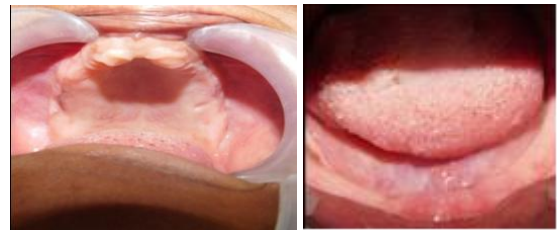

Fig. 15: Intro oral pictures showing flabby areas

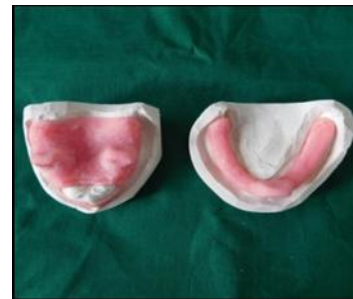

Fig. 16: Custom trays with windows

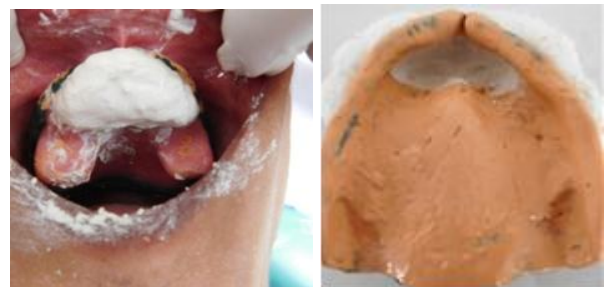

Fig. 17: Flabby areas recorded with plaster

DISCUSSION

Flabby ridges are composed of mucosal hyperplasia and loosely arranged fibrous connective tissue as well as denser collagenised connective tissue. In the soft tissue, varying amounts of metaplastic cartilage and/or bone have been reported¹. If complete denture is fabricated without considering special impression techniques to avoid compressing the flabby tissues, then the patient presents back with complain of looseness of the dentures.

The techniques described in this article are aimed at recording the flabby areas with mucostatic impression materials which does not displace the flabby tissues and the remaining areas are recorded in mucocompressive impression material thereby achieving the adequate retention and stability of the dentures.

One part impression tray technique is suggested when the degree of mucosal displacement is minimal⁶. In this technique the flabby tissues are recorded with pressureless method and remaining areas with conventional technique. The advantage of this technique is flabby tissues are recorded in mucostatic condition. But it is time consuming technique and Tissues cannot be visible while making impression.

Palatal splinting with two part tray system was described by Osborne in 1964 where two overlying impression trays are used for recording maxillary arches with displaceable anterior ridges⁷. The aim of this technique is to record the denture bearing areas properly while maintaining the contour of easily displaceable tissues. This technique is modified by Devlin in 1985, he positioned a locating rod in the centre of the palatal tray⁸. This rod guides the placement of the second tray thereby allowing even thickness of the impression material.

In selective impression compound flammig technique, flabby tissues are recorded in mucostatic condition using

alginate material while the rest of the denture bearing areas are recorded in mucocompressive method along with functional border moulding of the tissues using impression compound. By performing the impression methods in this way the original undistorted shape of the fibrous tissues is retained while the tissues more capable of functional denture support are recorded in displaced state⁶.

Two part impression technique or Mucostatic and mucodisplacive combination or window technique was first described by Osborne in 1964. In this technique the pressure exerted by the tray does not cause distortion of the mobile tissues. This design of modified special tray can vary from a completely uncovered section of the arch to a window overlying the unsupported mucosa. In case of anterior flabby areas, modification of the position of the handle is required. A modified rim handle design prevents unset impression material falling to the back of the mouth when the patient is supine. The advantage of window design is that the sulcus areas are properly recorded before the second stage of impression is completed.

CONCLUSION

Flabby tissues pose a challenge for the clinician to achieve a stable prosthesis. A thorough knowledge of science of various impression materials and special impression procedures to manage flabby ridges to achieve proper retention and stability of the dentures is required. In this paper some of the modified conventional techniques are described. These techniques does not need specialized equipments and uses materials that are easily available in contemporary general dental practice and does not require additional dental visits for the patient compared to the fabrication of conventional complete denture.

REFERENCES

1. Crawford RW, Walmsley AD. A review of prosthodontic management of fibrous Ridges, *Br Dent J* 2005; 199:715-719.
2. Prasad DK, Mehra D, Prasad AD. Prosthodontic management of compromised ridges and situations. *NUJHS*. 2014; 4:141-148.
3. Kelly E. Changes caused by a mandibular removable partial denture opposing a maxillary complete denture. *J Prosthet Dent*. 1972; 27:140-150.
4. Carlsson G. Clinical morbidity and sequelae of treatment with complete dentures. *J Prosthet Dent*, 1998; 79:17-23.
5. Lynch CD, Allen PF. Management of the flabby ridge: using contemporary materials to solve an old problem, *Br Dent J*. 2006; 200:258-261.
6. Lamb DJ. Problems and solutions in complete denture prosthodontics. pp 57-60. London: Quintessence, 1993.
7. Osborne J. Two impression methods for mobile fibrous ridges. *Br Dent J*. 1964; 117:392-394.
8. Devlin H. A method for recording an impression for a patient with a fibrous maxillary alveolar ridge. *Quint Int*. 1985; 6:395-397