

## Case Report

# Immediate implant placement in mandibular premolar site with allogenic bone graft augmentation with delayed loading concept: A Case Report

Surender Kumar <sup>1</sup>, Manish Goutam <sup>2</sup>

<sup>1</sup>Assistant Professor, Department of Prosthodontics, Crown Bridge, Aesthetic Dentistry and Oral Implantology, Dental Institute, Rajendra Institute of Medical Sciences (RIMS), Ranchi, Jharkhand, India

<sup>2</sup>Tutor, Department of Prosthodontics, Crown Bridge, Aesthetic Dentistry and Oral Implantology, Dental Institute, Rajendra Institute of Medical Sciences (RIMS), Ranchi, Jharkhand, India

### ARTICLE INFO



Keywords:

Immediate implant placement, dfdb bone graft, delayed implant loading.

### ABSTRACT

Recent advancements in oral implantology includes reducing the treatment time interval by placing implants in fresh extraction sockets. Reducing a surgical step and overall cost has remarkably improved patients comfort and willingness to opt for this rehabilitation procedure. In this case report, we underwent an immediate implant placement in a fresh extraction socket of a mandibular right premolar with simultaneous bone augmentation using DFDB bone graft material. Delayed loading protocol was performed followed by ceramco-metal prosthesis. Treatment outcome demonstrated a stable peri-implant situation and confirmed a satisfactory treatment result.

### INTRODUCTION

The posterior teeth are very important for the maintenance of the arch form, mastication, digestion, facial esthetics and for proper occlusal form.[1] Tooth loss is one of the major problems to seek prosthodontic therapy mainly caused mainly by caries, periodontitis, trauma, endodontic failures and congenital absence. Systemic diseases also play a role in tooth loss like diabetes mellitus, osteoporosis[2], cardiovascular disease[3] and cancer[4], hence it is important to maintain oral and general health for wellbeing.

Tooth loss can lead to improper mastication, indigestion, poor esthetics, speech, derranged occlusion and psychological distress. Therefore it is mandatory to

replace the edentulous region as soon as possible. Alternatives for replacement include fixed partial prosthesis, removable prosthesis and dental implants. Keeping in mind all the pros and cons of these replacement alternatives careful treatment plan should be executed.

Dental implants are the recent advancements in prosthodontic rehabilitation designed to simulate natural tooth root and crown form. They also prevent alveolar bone resorption and preserve gingival tissue form from recession. The advantages include prevention from adjacent tooth (abutment) cutting as in fixed partial dentures, fixed restoration, improved esthetics, longer

\* Corresponding author: *Dr. Surender Kumar, Assistant Professor, Department of Prosthodontics, Crown Bridge, Aesthetic Dentistry and Oral Implantology, Dental Institute, Rajendra Institute of Medical Sciences (RIMS), Ranchi, Jharkhand, India*  
Email: [drsurrender\\_kum@yahoo.co.in](mailto:drsurrender_kum@yahoo.co.in), Contact number: 08285081688

restoration life and sense of natural teeth psychologically.

Traditionally, dental implants were inserted after completion of the post-extraction socket healing phase between several months to 1 year for bone maturation[5]. Approximate 45% of residual alveolar bone resorption post extraction is evident over time led to insufficient bone for routine implant placement.[6] Therefore, a technique which reduced the time interval between tooth extraction and implant placement came into existence known as an immediate implant protocol.

An immediate implant is one that is placed into a freshly extraction socket when a tooth/root is extracted. The advantages of this protocol over delayed implant placement are prevention of alveolar bone resorption post extraction site, waiting period for socket healing is eliminated, surgical steps and total treatment cost are reduced, less tissue damage and more patient comfort as edentulous period is also decreased.[7]

Present case reports the immediate implant rehabilitation of mandibular right premolar tooth following extraction with preservation of soft and hard tissue architecture with bone graft augmentation and delayed prosthetic loading.

### Case Report

A 35-year-old male patient reported to our department of Prosthodontics with the chief complaint of difficulty in chewing from lower right back region of the jaw since 1yrs. Past dental history revealed trauma to the jaw resulting in crown fracture followed by slow degradation till the present status with almost no coronal tooth. He was interested in getting his root replaced with best treatment option and had high esthetic demand. Medical history was not significant. Clinical examination revealed decayed root stump of 2nd premolar of right

mandibular arch #45 with adequate band of attached gingiva and normal probing depth. [Fig.1] Periodontal status was satisfactory, adequate mouth opening, absence of any TMJ dysfunction, class I molar relation, canine guided occlusion bilaterally with sufficient overjet and overbite. Radiographic examination with Orthopantomograph (OPG) & Intra Oral Periapical (IOPA) x-rays revealed slight peri apical radiolucency at the apex of 2nd premolar mandibular region.[Fig.2] All the treatment options were discussed with the patient and explained with possible drawbacks of each. Hence, he opted for Immediate Implant insertion following tooth/root extraction along with allograft augmentation procedure and Implant supported prosthesis. Treatment plan includes oral prophylaxis, extraction of root stump 45 and immediate placement of implant with demineralized freeze dried allogenic bone graft (DFDB) followed by conventional metal ceramic fixed partial prosthesis.

Bone mapping procedure was performed after taking patients written consent under 2% local anaesthesia (infiltration) to measure the bone width at the crest which was mesio-distally 5.0mm and bucco-lingually 2.0mm below the crest of the ridge was 6.0mm and radiographs were used to assess the bone height from the superior margin of mental foramen to the crest of mandibular right 2nd premolar which was 14.0mm. Crown height space was recorded as 10mm (minimum 8mm required for fpd). As determined by ridge mapping the implant is planned to emerge beneath the incisal edges of the proposed crown & surgical guide template was fabricated along that proposed angulation in clear acrylic (Pyrax Polymers, Roorkee, India).[Fig.3] Comparing the available bone in this case and minimum bone required for the implant, a dental implant (EZ Hi-Tec, Life Care Dental Implant System, Herzilia, Israel) of 3.75mm diameter and 10mm length was selected for

insertion under local anesthesia following an Atraumatic extraction of mandibular right 2nd premolar root and thorough curettage of the socket.

Patient was given antibiotic prophylaxis (2gm Amoxicillin) 1hr prior to surgical procedure. 2% lignocaine local anaesthetic was administered for Inferior dental nerve block and Lingual nerve block followed by conservative crestal flap incision (papilla preservation)[Fig.4] and flap reflection. Atraumatic extraction of #45 root with periostomes and elevators was performed [Fig.5]. Socket curettage was done thoroughly to remove any granulation tissues and inspected with periodontal probe to evaluate any signs of defect or cortical plate perforation. All the socket walls were intact. Osteotomy site was prepared with recommended drilling sequence by the manufacturer.(Fig.6) Surgical template and paralleling tool guided the proposed angulation of the drills (Fig.7). Implant was inserted at the osteotomy site 3-4mm apical to the root apex with the insertion torque of 35Ncm and cover screw was placed. Allogenic DFDB bone graft (Tata Memorial Hospital, Tissue bank, Mumbai, India) mixed with patient's Platelet Rich Plasma (Fig.8) was insertion around the exposed implant flutes to fill the socket entirely to the crest.(Fig.9). Black braided silk nonresorbable suture was placed to approximate the flap coronally. Post-operative radiograph was taken to evaluate the accuracy of the implant position.(Fig.10) post-operative medications (antibiotic and analgesic) and standard instructions was given to patient and recalled after 7days for follow up and suture removal.

After 3 months radiograph was taken to assess the bone regeneration status and the osseo integration surrounding the implant, which showed favourable results and no sign of any radiolucency was evident. Implant uncover was done, cover screw removed and implant abutment

was screwed. (Fig.11) Impression was made with closed tray technique using light body and putty polyvinyl siloxane rubber base material (Aquasil, Dentsply, Surrey, UK). Impression was sent to the laboratory for fabrication of porcelain fused to metal (PFM) crown. PFM crown was fabricated and cemented to the abutments [Fig.12]. Follow-up was done after 3, 6, and 12 month's interval. Recall visits were done after one month and six months.

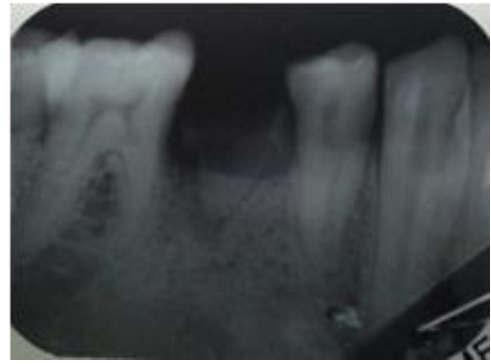
### Discussion

Recently immediate implant placement concept has been on top priority due to multiple benefits. Evidence has shown that immediate implant placement presents more advantages as compared to delayed implant insertion, which are implants in fresh extraction sites can be placed in the same location as the extracted tooth thereby minimizing the need for angled abutments, osseo integration is more favorable, the bony receptors are preserved by preventing atrophy of the alveolar ridge thereby preventing recession of the mucosal and gingival tissues, immediate placement of implants keeps contaminants away from the extraction socket, waiting times for primary healing of the soft tissues, and regeneration of the osseous structure are eliminated.[8] Krump and Barnett reported high success rates with dental implants placed at the time of extraction.[9]According to Nkenke E et al. delayed imant loading (after 4 or 5 months of implant placement) results in lesser failures (1 out of 18) compared to immediate implant loading(6 out of 12) in case of implant stability.[10]

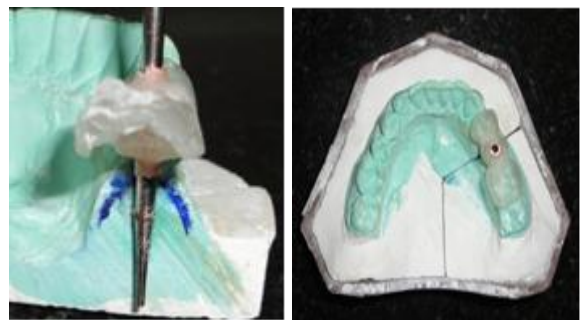
According to Attard and Zarb immediate implant loading may be successful in freshly extracted sockets as long as marginal periodontitis is absent[11] whereas Quirynen et al. stated that combining immediate implant placement

with immediate loading results in greater implant failure incidence [12] while Ferrara et al. combined immediate implant placement and early loading of 33 implants and observed satisfactory esthetic and functional results from patient's overview. [13] It has been reported that implant should be placed minimum of 3mm apical to the apex of the socket into healthy bone for achieving intitial stability of implant in immediate implant placement technique.[14-16]

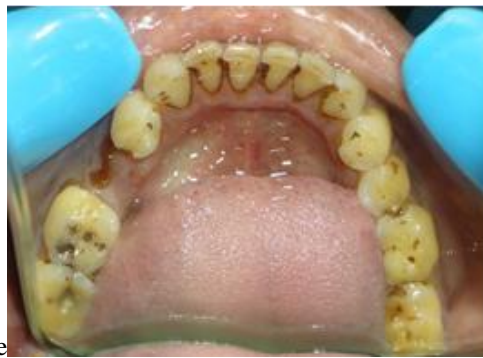In this case we went for delayed loading to minimize the implant micro-movement during function within the freshly extracted socket which possibly result in failure of osseo integration. Treatment outcome revealed excellent esthetic and fuctional rehabilitation which gave the patient a feel of immense satisfaction and confidence. [Fig.13]



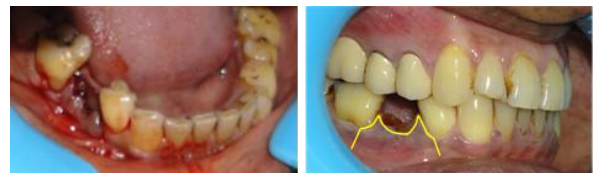**Figure 2**



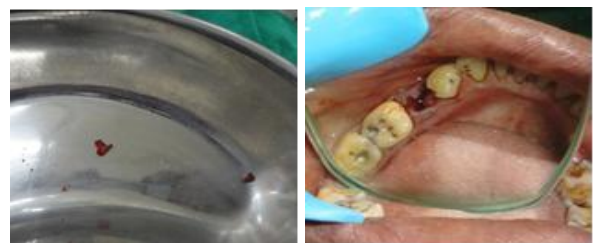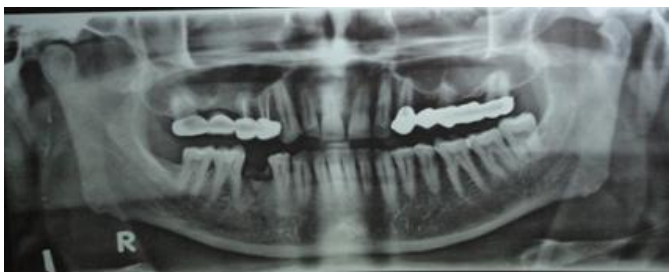**Figure 3**



**Figure 1**



**Figure 4**



**Figure 5**

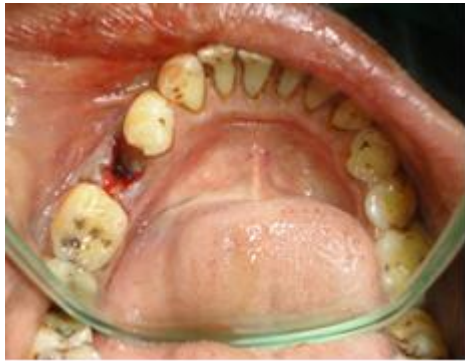

Figure 6

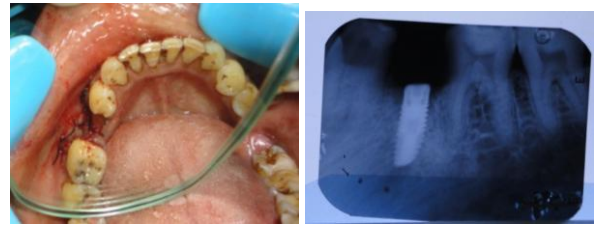


Figure 10

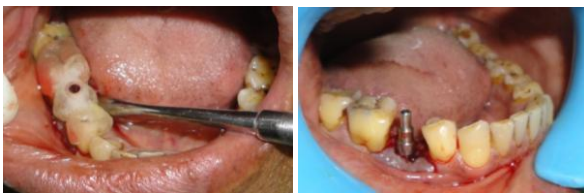

Figure 7

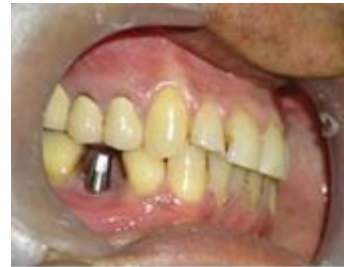

Figure 11



Figure 8

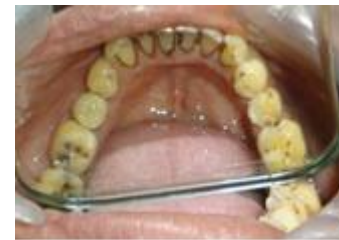

Figure 12

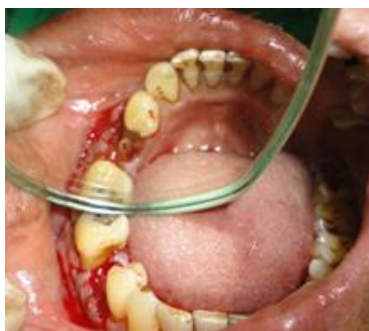

Figure 9

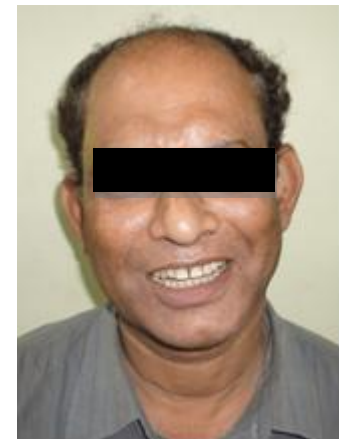

Figure 13

## Conclusions

Immediate implant placement with dfdb bone graft followed by delayed implant loading protocol showed promising results. This approach is considered to be highly technique sensitive and requires careful case selection, proper treatment plan and follow-up of surgical and prosthetic protocols for positive outcomes. Patients motivation for proper oral hygiene maintainence is also an utmost important factor for long term success.

## References

- Misch CE. Endosteal implants for posterior single tooth replacement: alternatives, indications, contraindications, and limitations. *Journal of Oral Implantology*.1999; 25(2): 80-94.
- Anil S, Preethanath RS, AlMoharib HS, Kamath KP, Anand PS. Impact of osteoporosis and its treatment on oral health. *Am J Med Sci*. 2013; 346:396–401.
- Desvarieux M, Demmer RT, Rundek T, Boden-Albala B, Jacobs DR, Jr, Papapanou PN, et al. Relationship between periodontal disease, tooth loss, and carotid artery plaque: The oral infections and vascular disease epidemiology study (INVEST) Stroke. 2003; 34:2120–5.
- Meyer MS, Joshipura K, Giovannucci E, Michaud DS. A review of the relationship between tooth loss, periodontal disease, and cancer. *Cancer Causes Control*. 2008; 19:895–907.
- Palmer RM, Palmer PJ, Baker P. Immediate and early replacement implants and restorations. *Dent update* 2006; 33:262-268.
- Lekovic V, Camargo PM, kokkevold PR, et al. preservation of alveolar bone in extraction socketrs using bioadsorbable membranes. *J Periodontol*. 1998; 69(9):1044-1049.
- Singh S, Gupta H, Kumar D, Agarwal R, Natu SS, Gupta N. Immediate Implant placement along with bone graft and delayed implant placement in a grafted socket: a comparative study. *Int J Oral Implantol Clin Res*. 2015; 6(2):40-47.
- Singh M, Kumar L, Anwar M, Chand P. Immediate dental implant placement with immediate loading following extraction of natural teeth. *Natl J Maxillofac Surg*. 2015 Jul-Dec; 6(2):252–255,
- Krump JL, Barnett BG. The immediate implant: A treatment alternative. *Int J Oral Maxillofac Implants*. 1991; 6:19–23.
- Nkenke E, et al. Immediate versus delayed loading of dental implants in the maxillae of minipigs: follow-up of implant stability and implant failures. *Int J Oral Maxillofac Implants*. 2005 Jan-Feb; 20(1):39-47.
- Attard NJ, Zarb GA. Immediate and early implant loading protocols: A literature review of clinical studies. *J Prosthet Dent*. 2005; 94:242–58.
- Quirynen M, Van Assche N, Botticelli D, Berglundh T. How does the timing of implant placement to extraction affect outcome? *Int J Oral Maxillofac Implants*. 2007; 22(Suppl 1):203–23.
- Ferrara A, Galli C, Mauro G, Macaluso GM. Immediate provisional restoration of postextraction implants for maxillary single-tooth replacement. *Int J Periodontics Restorative Dent*. 2006; 26:371–7.
- Schwartz-Arad D, Chaushu G. The ways and wherefores of immediate placement of implants into fresh extraction sites: a literature review. *J Periodontol*. 1997; 68:915–923.

15. Werbitt MJ, Goldberg PV. The immediate implant: bone preservation and bone regeneration. *Int J Periodontics Restorative Dent.* 1992;12:207–217.
16. Cochran DL, Schenk RK, Lussi A, et al. Bone response to unloaded titanium implants with sandblasted and acid etched surface: a histometric study in the canine mandible. *J Biomed Mater Res.* 1998;40:1–11.