

Original Article**PREVALENCE OF ELONGATED STYLOID PROCESS IN CENTRAL INDIA POPULATION- A PANORAMIC RADIOGRAPHIC STUDY****Rishi Thukral¹, Animesh Barodiya², Shitij Bhargava³, Naman Awasthi⁴**¹ MDS, Oral and Maxillofacial Surgery, Assistant professor, Department of dentistry, Government medical college Vidisha (MP), India² MDS, Oral and Maxillofacial Surgery, Barodiya Dental Clinic And Maxillofacial Centre, Itarsi (MP) India³ MDS, Oral medicine and radiology, Cure one dental clinic, Bhopal (MP), India⁴ MDS, Oral and maxillofacial surgery, Assistant professor, Department of dentistry, Government medical college Shahdol (MP), India

ARTICLE INFO



Keywords:

Styloid process elongation, Eagle's syndrome, Panoramic radiography

ABSTRACT

Objectives: The aim of this study is to determine the prevalence of styloid process elongation (SPE) in Central India population and to investigate the SPE incidences in relation to the age subgroups, gender, types of calcification, unilateral or bilateral occurrence and symptomatic presentation. **Methods:** 407 PRs with their clinical record were randomly retrieved from the archival records at Oral Diagnosis Department of People's University Bhopal, India. The subjects were divided into 4 age subgroups: 30–39, 40–49, 50–59 and 60 years and older. Kodak 8000C Digital Panoramic system was used to make the radiographs.. The length of the styloid process and/or ossification of stylohyoid ligament which were longer than 30 mm were considered as elongated. **Results.** Out of 407, 65 OPGs (15.97%) showed styloid complex ossification, 36 OPGs of male patients and 29 OPGs of female patient showed styloid process elongation (SPE). Only 5 OPGs showed pseudo articulated styloid process, 8 OPGs showed segmented styloid process and rest 52 OPGs showed elongated type of ossification. In 53.8% cases elongation was bilaterally and in 46.2% cases elongation was unilaterally present. The highest prevalence of SPE was seen in age group of 30-39 years. Only 3 Patients had cervicopharyngeal symptoms and were diagnosed to have Eagle's syndrome. **Conclusion:** This study gives a preliminary data regarding SPE for this geographic region. Results suggests that there is considerable variation for the prevalence of SPE when compared to other populations Panoramic radiographs may be used for investigating the ESP in the patients presenting with complaints suggesting of SPE.

INTRODUCTION

The styloid process arises from the temporal bone immediately in front of the stylomastoid foramen.¹ Its shape is cylindrical, tapering gradually toward the apex like a pinnacle. The apex of the styloid process is clinically important, because it is located between internal and external carotid arteries, just lateral to the tonsillar fossa within the lateral pharyngeal wall. The tip of the styloid process is continuous with the stylohyoid ligament, which extends to the lesser cornu of the hyoid bone. Muscular and ligamentous

structures are attached at various locations of the process.²

The stylohyoid process and ligament are derived from the first and second branchial arches, in addition to Reichert's cartilage. It has been demonstrated that during fetal development Reichert's cartilage links the styloid bone to the hyoid bone. In the adults the stylohyoid ligament, which is normally composed of dense fibrous connective tissue, may retain some of its embryonic cartilage and thus have the potential to become partially or completely ossified. If these structures solidify they may develop inflammatory

* Corresponding author: Animesh Barodiya, MDS, Oral And Maxillofacial Surgery, Barodiya Dental Clinic And Maxillofacial Centre, Itarsi (MP) India. Phone no.9993652003, Email- anim4391@gmail.com.

changes or impinge on the adjacent arteries or sensory nerve endings and can cause pain and suffering present in symptomatic cases^{3,4}.

The frequency of ossification of the styloid complex has been found to vary from 4% to 30%⁵. This complex, also called stylohyoid chain, is composed of the styloid process, stylohyoid ligament and the stylomandibular ligament.^{6,7} The normal SP length is approximately 20-30 mm and if it is beyond 30mm it is considered to be elongated.³

Radiographic classification system of SPE includes three types of radiographic appearances. The Type I pattern represents an uninterrupted, elongated styloid process; Type II is characterized by the styloid process apparently being joined to the stylohyoid ligament by a single pseudoarticulation. This gives the appearance of an articulated elongated styloid process and Type III consists of interrupted segments of the mineralized ligament, creating the appearance of multiple pseudoarticulations within the ligament.⁸

MATERIALS AND METHODS

The study is based on 407 PRs randomly retrieved from the archival records. All the PRs were retrieved from the Oral Diagnosis Department at People's University. The PRs of the 407 patients had originally been taken for routine examination and diagnostic purposes. The PRs were excluded where radiograph quality was not good enough; stylohyoid complex was not clearly identified and superimposed on the temporal bone. The subjects were divided into 4 age subgroups: 30-39, 40-49, 50-59 and 60 years and above. All the PRs were done and evaluated in the same fashion. Kodak 8000C Digital Panoramic and cephalometric system was used to make the radiographs. Digital ruler inbuilt in the Kodak digital

imaging software 6.12.10.0 was used to analyze the length of styloid process. The apparent lengths of styloid process were measured, from the point of emergence of the process to their tips, regardless of whether or not the styloid process was segmented. The length of the styloid process and/or ossification of stylohyoid ligament which are longer than 30 mm were considered as elongated.

RESULTS

A total of 407 patient's OPG were examined from the database of college records (2009-2012). 242 OPGs were of male patients and 165 OPGs were of females. Out of 407, 65 OPG (15.97%) showed styloid complex ossification, 36 OPGs of male patients and 29 OPGs of female patient showed styloid process elongation (SPE). The percentage of SPE was 55.3% in males and in females it was 44.2% .

There were three patterns seen of styloid complex ossification. These were elongated, pseudo articulated and segmented. Only 5 OPGs showed pseudo articulated styloid process, 8 OPGs showed segmented styloid process and rest 52 OPGs showed elongated type of ossification. In 53.8% cases elongation was bilaterally and in 46.2% cases elongation was unilaterally present.

The patients were divided into 4 age groups. In group I with the patients of age group 30 – 39, 18.8% OPG showed SPE out of which 25 OPG showed elongated SP, 3 showed pseudo articulated and 5 showed segmented SP. Group II (40 – 49 years), III (50 - 59) and IV (60 years and above) only showed elongated type of SPE with prevalence of 13.33%, 13.2% and 15.9% respectively. When archival case records were analyzed, two out of 407 (0.49%) patients who previously had undergone tonsillectomies and had

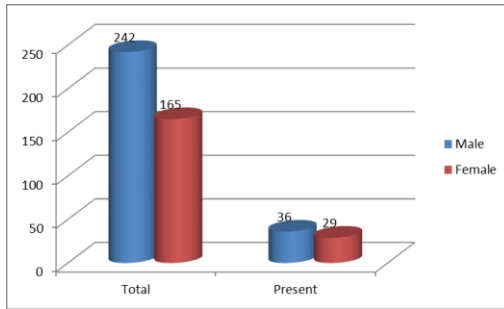


Fig. 1

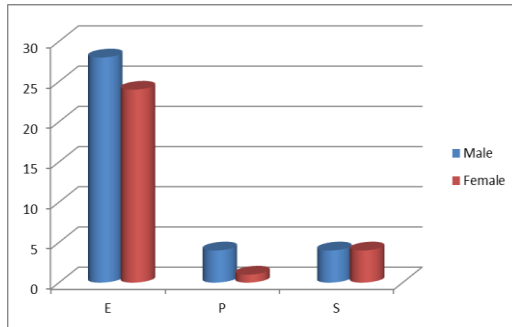


Fig. 2

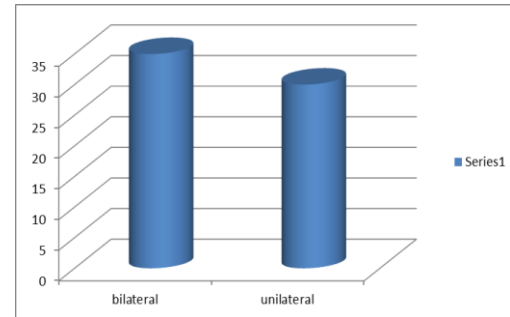


Fig.3

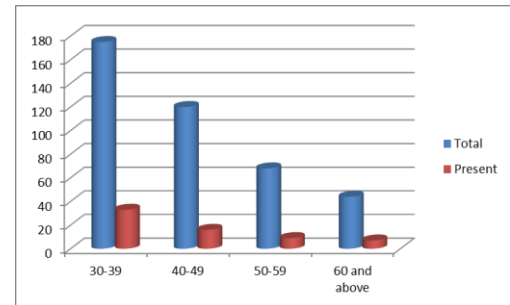


Fig. 4

presented with cervicopharyngeal symptoms along with SPE which were finally diagnosed as Eagle's syndrome. One patient (0.24%) had no history of trauma or surgery but presented with cervicopharyngeal symptoms with SPE which was diagnosed as Stylohyoid syndrome.

DISCUSSION

Steinmann proposed various theories to explain ossification of stylohyoid complex. These were: (a) "Theory of reactive hyperplasia" – trauma can cause ossification at the end of the styloid process down the length of the styloid ligament, since the styloid ligament contains remnants of its connective tissue and fibrocartilaginous origins, the potential for ossification remains; (b) "Theory of reactive metaplasia" – an abnormal post-traumatic healing response initiates the calcification of stylohyoid ligament; and (c) "Theory of anatomic variance" – the early elongation of the styloid process and ossification of the styloid ligament

are anatomical variations that occur without recognizable trauma.⁹ Data on the osteometric values of the styloid process are scanty. Thot et al reported that the length of the left side styloid ranged from 0.7 to 1.6 cm, and on the right side, from 0.8 to 2.4 cm. The average lengths for the left and right styloids were 1.52 cm and 1.59 cm, respectively, in Indian subjects.¹⁰ Keur et al stated that, if the length of the process or the mineralized part of ligaments which appeared in radiography was 30 mm or more, could be considered as an elongated styloid process.²

Eagle's syndrome, named after Eagle who first described the elongation of the SP and structural changes in the styloid ligament with the accompanying clinical signs and symptoms. The diagnosis of Eagle's syndrome can usually be made on physical examination by digital palpation of the styloid process in the tonsillar fosse, which exacerbates the pain and with radiographical work-up. In addition, relief of symptoms with injection of an anesthetic solution into

the tonsillar fossae is highly suggestive of Eagle's syndrome.¹¹ The normal radiographic length of the styloid process as reported in the literature is 20 – 30 mm. In the present study the radiographic length of styloid process exceeding 30 mm was considered as elongated styloid process. In our study we found prevalence of ESPs was 15.97 %. In studies by various authors the prevalence rate varied between 1% to 28%.^{3,4,6,7,10,12,13,17,14,15,16} Keur, et al² in a sample of edentulous patients, reported a prevalence of 30.0%. The difference in prevalence when compared to other studies could be due to the difference in methodology, sample size and racial aspect of sample.

We noticed that there was no gross difference in occurrence of ESP between two genders, which was consistent with others studies^{2,17,18} but it differs from a study by O Carroll et al who reported a slight predilection of ESP for females.¹⁹ In present study bilateral SPE were more than unilateral which was in accordance with other studies,^{15,17} but study by Gulnara et al found majority of ESP to be unilateral.²⁰ We noticed that age and the prevalence of ESP was not significant but majority of the authors^{2,17,18,19} found a positive relationship between the presence and/or increasing length of ESP and age. In this study significant number (4.6%) of ESPs were symptomatic which is comparable with other studies which were reported symptomatic cases in the range of 4–10.3%.⁵

CONCLUSION

This study gives a preliminary data regarding SPE for this geographic region. Results suggests that there is considerable variation for the prevalence of SPE when compared to other populations Panoramic radiographs may be used for investigating the ESP in the patients presenting with complaints suggesting of SPE, also

anatomical regions of the stylohyoid ligament should not be overlooked in the panoramic radiographs.

REFERENCES

1. Eagle WW. Elongated styloid process. Arch Otolaryngol 1948; 47: 630-40.
2. Keur JJ, Campbell JPS, Mc Carthy JF, Ralph W.J. The clinical significance of the elongated styloid process. Oral Surg Oral Med Oral Pathol 1986; 61: 399-404.
3. Monsour PA, Yougn WG. Variability of the styloid process and stylohyoid ligament in panoramic radiographs. Oral Surg Oral Med Oral Pathol 1986; 61: 522-6.
4. Winkler S, Sammartino FJ, Monari JH. Stylohyoid Syndrome. Oral Surg Oral Med Oral Pathol 1981; 51: 215-7.
5. Shahoon H, Kianbakht . Symptomatic Elongated Styloid Process or Eagle's Syndrome: A Case Report. JODDD. 2008; 2(3):102-5.
6. Langlais R.P., miles D.A., Van Dis M.L. Elongated and mineralized stylohyoid ligament complex: A proposed classification and report of a case of Eagle's syndrome. Oral Surg Oral Med Oral Pathol 1986; 61: 527-32.
7. Kawai T., Shimimoto K., Ochiai S.. Elongated styloid process as a cause of difficult intubation. J Oral Maxillofac Surg 1990; 48: 1225-8.
8. Langlais RP, Langland OE, Nortje CJ. Soft tissue radiopacities. In Langlais RP, Langland OE(edi) Diagnostic imaging of the jaws. Philadelphia : A Lea and Febiger.1995. p.617-21.
9. Steinmann EP. Styloid syndrome in absence of an elongated process. Acta Otolaryngol 1968; 66:347-56.
10. Thot B, Revel S, Mohandas R, Rao AV, Kumar A. Eagle' syndrome. Anatomy of the styloid process. Indian J Dent Res 2000; 11:65-70.
11. Balbuena L Jr, Hayes D, Ramirez SG, Johnson R. Eagle's syndrome (elongated styloid process). South Med J 1997; 90:331-4. Comment in: South Med J 1998; 91:43.
12. Eagle WW. Elongated styloid process report of two cases. Arch Otolaryngol 1937;25: 584-7.
13. Cumali Gokcea Yildiray Sismanb Elif Tarim Ertasc Faruk Akgunlu, Ahmet Ozturk. Prevalence of Styloid Process Elongation on Panoramic Radiography in the Turkey Population from Cappadocia Region. European Journal of Dentistry 2008; 2:18-22
14. Bozkır MG, Boğa H, Dere F. The evaluation of elongated styloid process in panoramic radiographs in edentulous patients. Tr. J. of Medical Science 1999; 29:481-5.
15. Correll RW, Jensen JL, Taylor JB, Rhyne RR. Mineralization of the stylohyoid - stylomandibular ligament complex. A radiographic incidence study. Oral Surg Oral Med Oral Patho 1979; 48:286-91.
16. MacDonald-Jankowski DS. Calcification of the stylohyoid complex in Londoners and Hong Kong Chinese. Dentomaxillofac Radiol 2001; 30:35-9.
17. Ferrario VF, Sigurta D, Daddona A, Dalloca L, Miani A, Tafuro F, Sforza C. Calcification of the stylohyoid ligament: Incidence and morphoquantitative evaluations. Oral Surg Oral Med Oral Pathol 1990; 69:524-9.
18. Omnell KAH, Gandhi C, Omnell ML. Ossification of the human stylohyoid ligament.

- A longitudinal study. *Oral Surg Oral Med Oral Pathol Oral Radiol Endod* 1998; 85: 226-32.
19. Carrol MK. Calcification in the stylohyoid ligament. *Oral Surg Oral Med Oral Pathol* 1984; 58:617-21.
 20. Gulnara Scaf, Deborah Queiroz de Freitas, Leonor de Castro Monteiro Loffredo. Diagnostic reproducibility of the elongated styloid process. *J. Appl. Oral Sci.* 2003; 11(2):120-4.