

## Case Report

# SCREW RETAINED HYBRID TOOTH AND TISSUE SUPPORTED OVERDENTURE

Vishnu Manohar<sup>1</sup>, Rohan Grover<sup>2</sup>, Thirumurthy VR<sup>3</sup>, Bindhoo YA<sup>4</sup>, Anjana Kurien<sup>5</sup>

<sup>1</sup> Senior Lecturer, Ultra's Best Dental College, Madurai

<sup>2</sup> Private Practitioner, Grover Dental and Implant Care, New Delhi

<sup>3</sup> Professor and HOD, Sri Ramakrishna Dental College, Coimbatore

<sup>4</sup> Reader, Sri Ramakrishna Dental College, Coimbatore

<sup>5</sup> Professor, Sri Ramakrishna Dental College, Coimbatore

## ARTICLE INFO



### Keywords:

Screw retained overdenture, Geriatrics, Hybrid overdenture, Telescopic prosthesis

## ABSTRACT

Prosthodontic rehabilitation of the elderly calls for special considerations due to physiological tissue changes and medical disorders intensified by age. It often is difficult to delineate where the normal aging process culminates and where the disease process begins. Uncontrolled diabetes can impede successful implant supported restoration of such patients. Remaining natural teeth can be effectively used to retain the denture. The full protocol of a new method by which implant components can be salvaged to create a cost effective attachment assembly in screw retaining a full arch prosthesis to endodontically treated teeth, is proposed in this article.

## INTRODUCTION

The WHO had outlined criteria that classify edentulism as a form of physical impairment. The population at the end of 1950s over seventy years of age was predominantly edentulous. The mean number of retained teeth had increased to 14 by 2010 and this number is constantly on the rise. This new group of partially dentate elderly, who carry the burden of chronic disease and are on multiple medications, presents a new set of problem areas to the clinician. Successful rehabilitation with dental implants may be contraindicated in such medically compromised cases. In such individuals, the remaining natural teeth if periodontally sound, can serve as valuable abutments

in fixed prosthodontics and even successfully reconstructing entire arches, as the functional demands on such prostheses would be limited in the elderly. The objective of prosthodontic therapy in such cases would be to provide a good oral comfort, good phonetics<sup>1</sup> and a financially acceptable treatment plan. Also the psychological benefit of the teeth 'not being extracted' and the prospect of a fixed prosthesis would significantly improve their quality of life<sup>2</sup>.

In light of these, this article outlines the full protocol of how previously endodontically treated teeth could be used to fabricate a screw-retained, tooth and tissue supported hybrid overdenture in a geriatric individual.

\* Corresponding author: Vishnu Manohar Dental Clinic, 16/A, Alagappa Nagar, Mengles Road, Nagal Nagar, Dindigul, Tamilnadu -624003  
Phone: 9952729312, 9791545815

## CLINICAL REPORT

An 82-year-old male patient reported to the clinic with complaints of an ill-fitting denture and difficulty to adjust with the palatal plate of the maxillary denture leading to difficulty in speech and chewing food. History revealed that he had multiple teeth extracted 25 years ago following dental caries and endodontic treatment done 15 years back, fixed partial dentures were fabricated which failed over time and were lost along with parts of the prepared teeth. Medical history revealed that he was an uncontrolled diabetic for past 30 years and hypertensive.

Extraoral examination revealed that there was no facial asymmetry or mandibular deviations upon opening and closing. Mouth opening was 45mm. Intraoral examination revealed a maxillary arch with root stumps in relation to 16,13, 22,23,24,25,28 of which 13,16, 23,24,25 were endodontically treated (Fig. 1); and a mandibular arch with a fixed partial denture in relation to 33-42. The posterior teeth presented severe attrition bilaterally.

The patient expressed unwillingness to be rehabilitated with a removable prosthesis. On the other hand, medical history precluded the success of an implant supported fixed prosthesis. The proposal of attachment retained removable overdenture was also rejected by the patient due to its removable nature.

The periodontal evaluation of the remaining root stumps was normal and radiographic examination revealed satisfactory endodontic treatment with no periapical pathology. Considering the unique situation of the clinical demands, the only option of a fixed prosthesis was a tooth retained hybrid denture. It was necessary that this prosthesis would splint all the roots together to reinforce them, and contact the alveolar ridge for support. The denture would have to be

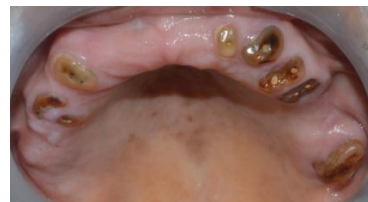

Fig.1: Pre-operative condition of maxillary arch showing endodontically treated root stumps

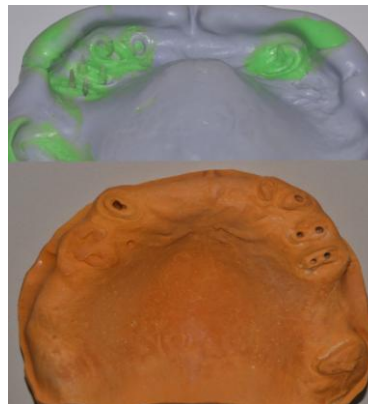


Fig.2: Impression of the post spaces and the maxillary arch and master cast

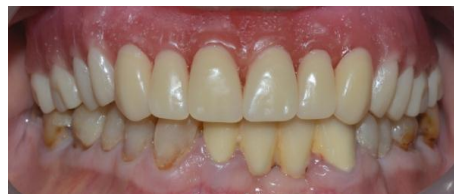

Fig.3: Teeth arrangement done and wax try in of the maxillary arch done with a self-cure denture base over the maxillary cast

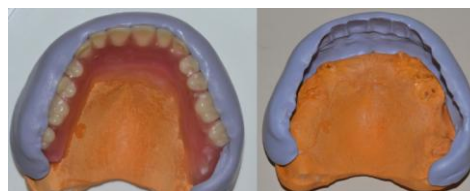


Fig.4: Putty index obtained after seating the trial denture over the master cast to form the Final Prosthetic Index (FPI)



Fig.5: Implant replicas and impression copings salvaged for the female portion attached with cover screws

roofless and minimally extended over the palatal vault. The metal framework for this hybrid denture was planned as follows.



Fig.6: a) Male portion (cover screw) b) Female portion (threading)



Fig.7: Wax cores made with spaces for cementing the female portions of the attachments and designed within the FPI

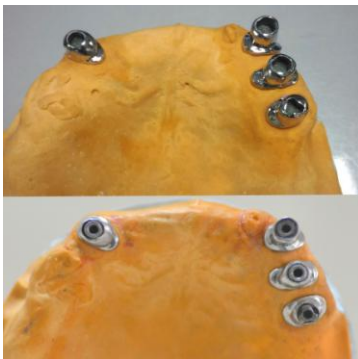


Fig.8: Female portions luted into the cast post and cores (first stage)



Fig.9: a) First Stage: Single unit castings of the cast posts and cores with finish lines b) Second Stage: Thimble copings fabricated with platforms to act as stoppers for the cover screws c) Third Stage: Metal framework fabricated connecting the thimble copings

A three staged framework was planned over the remaining endodontically treated teeth. The first stage involved cast post and cores; the second stage involved thimble copings seating on the cast cores; the third stage consisting a metal framework connecting the thimble copings.

The metal framework was cemented over the thimble copings intraorally to compensate for any casting shrinkage or parallelism errors that would compromise the passivity of fit. The attachment decided upon, was that of an implant cover screw (male part) and the corresponding threading present in implant impression copings, replicas (female part) and the final prosthesis was planned as a screw-retained hybrid overdenture much akin to screw-retained prostheses with implant multi-unit abutments, only with natural teeth roots in this case.

The female part of the attachment assembly was incorporated into the cast cores (first stage). The thimble copings (second stage) had access holes and platforms on the occlusal aspect as stoppers for the male part.

Preliminary impressions were made with an irreversible hydrocolloid material (Tropicalgin, Zhermack, Italy). Maxillary and mandibular casts were mounted following tentative jaw relation. The mandibular arch was restored with light cured composite with the help of an index obtained from a diagnostic wax up. Following rehabilitation of the mandibular arch, post space preparation was done in relation to 13,23,24,25 and impression was made. The post spaces were recorded with impression posts coated with light bodied addition silicone impression material (Variotime, Heraeus Kulzer, Romania) which were picked up by the maxillary arch impression (Fig.

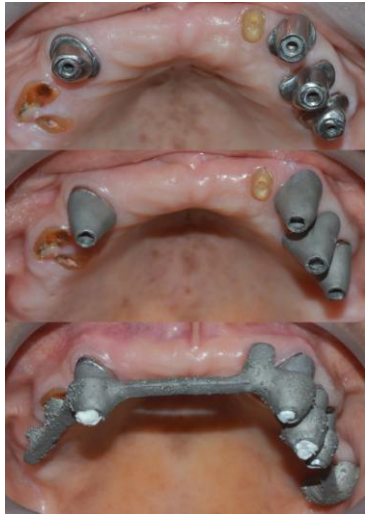


Fig.10: a) Seating of the cast post and cores intraorally. The female portion of the assembly is cemented into the cast cores b) Thimble copings seated over the cast cores c) Metal framework cemented with the thimble copings with resin cement intraorally to pick them up

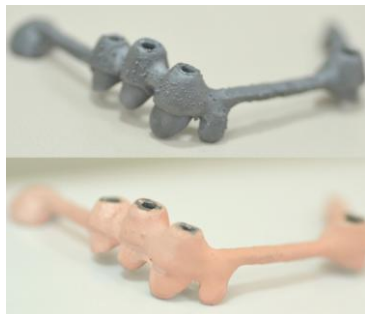


Fig.11: Pink opaquer applied over the metal framework to hide the metallic color of the superstructure

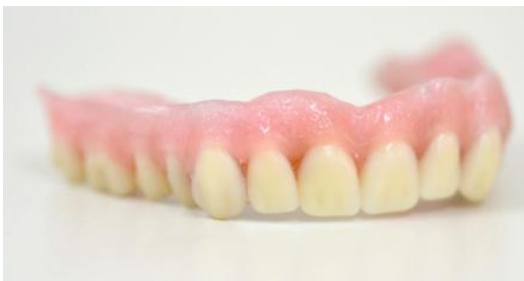

Fig.12: Teeth arrangement done over the metal superstructure with hard setup wax

2) with putty addition silicone impression material (Variotime, Heraeus Kulzer, Romania).

The impression was poured with Die stone type IV (Pearlstone, Asian Chemicals, India) to obtain the master cast. A denture base was constructed for the maxillary arch like an overlay denture and teeth

arrangement was done. The waxed maxillary denture was tried in, to verify esthetics and speech (Fig. 3). The final contour of the maxillary hybrid prosthesis was determined at this stage. The trial denture was then transferred to the master cast and a putty index of the final denture contour was obtained (Fig. 4). This would be referred to as Final Prosthetic Index (FPI) hereafter in this article.

Four implant cover screws (male part) and two implant impression copings and two implant replicas were obtained. The portion of the implant impression copings and replicas that contained the threading that would engage the cover screws were sectioned (Fig. 5) (female part). The attachment system planned, thus consisted of a male portion (Fig. 6.a) consisting of the cover screw and a female portion (Fig. 6.b) consisting of the threading from implant impression copings and replicas.

The waxed maxillary denture was seated over the cast used to remount it on the articulator. Wax patterns were fabricated, that started from within the post space and had a core portion. The final prosthetic index was used to ensure adequate clearance for the planned metal framework and acrylic / denture teeth over the wax cores (Fig. 7). Finish lines were milled with a dental surveyor onto the wax cores for the thimble copings. The axial surfaces were also milled parallel to each other to obtain a single path of insertion of the metal framework overlay. The female part (threading portion of the implant impression copings, replicas) was incorporated into the waxed cores to obtain an impression of them and provide a cavity within the core in which the female part would be cemented. The wax patterns of the cast post and cores were cast with Co-Cr alloy (Wironium, Bego, USA). The internal threading of the female parts were blocked out with

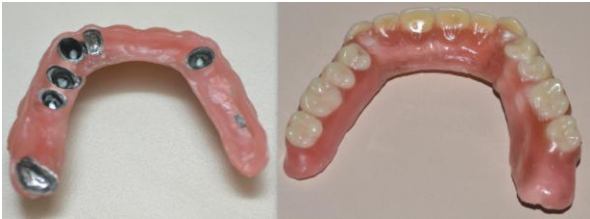

Fig.13: Occlusal and intaglio aspects of the final waxed up denture.

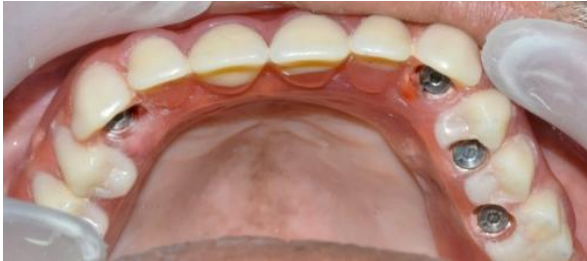

Fig.14: Processed hybrid denture connected with cover screws into the threadings of the cast post and cores

wax and luted into the respective cavities of the cast cores of 13,23,24,25 (Fig. 8) with dual curing self-adhesive resin cement (Bifix SE, Voco, Germany).

Thimble copings were next fabricated over the cast cores (Fig. 9.a) to fit at the finish lines. The male component (cover screw) was screwed into the threading now inside the cast cores during the waxup of these copings. A platform to act as stopper for the cover screws was thus obtained on each of the wax patterns. They were cast in Co-Cr alloy (Fig. 9.b) (Wironium, Bego, USA).

A cast framework was then fabricated from a wax pattern carefully designed so that it was well within the final prosthetic index, with the same alloy, overlying the thimble copings to connect them and splint them into a single unit. It also acted as a base for the planned hybrid denture and had rests on the remaining teeth 16, 22, 28 with access holes for the cover screws in relation to 13,23,24,25 regions (Fig. 9.c).

At metal try-in stage, the fit of the cast post and cores was verified (Fig. 10.a). The respective thimble copings were placed over them intra-orally (Fig. 10.b).

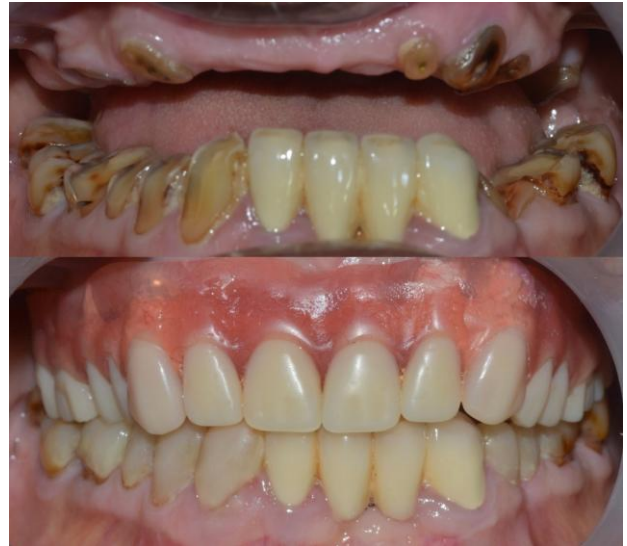

Fig.15: Rehabilitated maxillary and mandibular arches

The cast framework was verified for passivity of fit. Now the internal aspect of the third stage of the metal framework (the cast framework) of the denture, was coated with dual curing self-adhesive resin cement (Bifix SE, Voco, Germany) to cement it with the thimble copings intra-orally (Fig. 10.c). Once the cement was set, the entire framework now was removed from the mouth.

At this point, the second and third stages were cemented to each other and the entire metal framework was passively seating over the cast cores. This cemented base formed the final metal framework. This acted as the superstructure for the final prosthesis which was intended to be screw retained over the cast post and core bases. The final metal framework was coated with a layer of pink opaquer to mask the underlying metallic colour (Fig. 11).

Denture teeth were now set over this pink coated metal frame with hard setup wax (Fig. 12,13) (Cavex Setup Hard, Holland). The alveolar process waxup was completed and tried in for final corrections and esthetic changes. Then the denture was processed with

Heat cure acrylic resin (Veracril, Surana Enterprises, Mangalore) and the screw access holes were relieved. The cast post and cores were cemented into place with Type I glass ionomer cement (Luting & Lining Cement, GC, Tokyo). The denture was then placed over the cast cores and screwed with cover screws (Fig. 14) and a small piece of PTFE tape (PTFE thread seal tape, M-seal, India) was placed over the screw to avoid the filling material sealing the screw head. The access holes were then sealed with Glass ionomer cement (Ketac Molar, 3M ESPE, Germany). The prosthetic rehabilitation of the maxillary arch was thus completed with a screw retained tooth and tissue supported hybrid overdenture (Fig. 15).

## DISCUSSION

This article presents a novel approach of utilizing endodontically treated teeth in supporting a screw retained full arch fixed prosthesis. This technique of providing screw retained fixed prosthesis is common in contemporary dentistry with implants. The additional advantage of this technique is that even if one tooth fails (the incidence of which was found to be 7-16% in tooth supported telescopic overdentures after 4-10 years<sup>3</sup>), the screws can be removed to unseat the prosthesis and the tooth extracted and the prosthesis adjusted easily. The periodontal ligament again provides a good proprioception which reduces the impact force unlike implant supported dentures. Crum and Rooney<sup>4</sup> conducted a study that concluded “preserving teeth led to only 0.6mm of alveolar bone loss versus provision of a complete denture that resulted in 5.2mm of bone loss; providing an overdenture can preserve bone not only local to the teeth, but also in adjacent areas”.

The design of the prosthesis in three steps was done to ensure passivity of fit and provided opportunity for clinical adjustments. The thimble copings were connected with the metal framework intraorally with resin cement to eliminate any errors due to root stump positions, casting shrinkage or minute deviations in path of insertion because of the inability to temporize in this particular case in-between post space preparation and insertion. Notwithstanding the risk factors of caries, periodontal disease of abutments, and over contoured denture flanges<sup>5</sup> that are inherent disadvantages of such hybrid overdenture prostheses, a progressive solution was achieved with this new method.

## SUMMARY

Fixed prosthodontics in elderly provides a confidence and comfort that is unparalleled. The use of a screw retained attachment by salvaging components that are routinely available to us, can provide an economical alternative to the cost of attachment overdenture systems commercially available. By virtue of this new method, endodontically treated root stumps can be commendably employed as supports for a full arch restoration with a hybrid overdenture. Also, the elimination of the palatal plate and alveolar contour wax up that can be provided simulates the patient's lost dentition, and restores a near-normal function, in comparison to conventional complete dentures or other varieties of removable overdentures<sup>6</sup>.

## Acknowledgement

The authors thank Mr. Tarek Frank Feissali, CDT (Germany), General Manager, Quality Assessment, DentCare Dental Lab, Muvattupuzha, Ernakulam, Kerala and his team of technicians for their lab support

in making of the cast post and cores and metal framework design.

#### References

1. Giddon D, Hittleman E. Psychological Aspects of Prosthodontic Treatment for Geriatric Patients. *J Prosthet Dent* 1980;43:374-379.
2. Budtz-Jørgensen E. Prosthodontics for the elderly: diagnosis and treatment. Quintessence; 1999.
3. Widbom T, Löfquist L, Widbom C, Söderfeldt B, Kronström M. Tooth-Supported Telescopic Crown--Retained Dentures: An up to 9-Year Retrospective Clinical Follow-up Study. *International Journal of Prosthodontics* 2004; 17(1).
4. Crum RJ, Rooney GE. Alveolar bone loss in overdentures: a 5-year study. *J Prosthet Dent* 1978;40(6):610-613.
5. Preiskel HW. Overdentures made easy: a guide to implant and root supported prostheses. Quintessence; 1996.
6. Morrow RM, Powell JM, Jameson WS, Jewson CG, Rudd KD. Tooth supported complete dentures: an approach to preventive prosthodontics. *J Prosthet Dent* 1969;21:513-522.