

Original Article**THE SHAPE AND SIZE OF THE SELLA TURCICA IN SKELETAL CLASS I, II & III PATIENTS OF CENTRAL INDIA POPULATION****Pankaj Akhare¹, Pooja Wajekar², Usha Shenoy³, Sujoy Banerjee⁴, Ananya Hazare⁵, Himija Karia⁶, Sangeeta Bhattacharya⁷**^{1,4} Associate Professor, Department of Orthodontics, VSPM Dental College and Research Centre, Nagpur.² PG Student, Department of Orthodontics, VSPM Dental College and Research Centre, Nagpur.³ Professor and HOD, Department of Orthodontics, VSPM Dental College and Research Centre, Nagpur.^{5,6,7} Senior Lecturer, Department of Orthodontics VSPM Dental College and Research Centre, Nagpur.

ARTICLE INFO



Keywords:

Sella Turcica, Class I, class II, class III skeletal type, sella size, sella morphology

ABSTRACT

The purpose of this study was to evaluate the shape and size of sella turcica with different skeletal types in Central India population. 120 lateral cephalograms of the subjects having Class I, Class II and Class III skeletal base were selected and grouped according to gender and skeletal type. The length, depth and diameter of sella turcica was measured, also the shape of sella turcica were evaluated and the mean values were analysed. The statistical comparison of linear dimensions of sella turcica in males and females was performed using student's t- test. One way ANOVA test was done to determine if there was any difference in linear dimensions among the skeletal types.

The results show that when skeletal type was compared with sella size, a significant difference was found in the length of sella between the Class II and Class III subjects. Significant differences in linear dimensions between gender was found, with the length of sella being more in males than the females. Sella turcica presented with a normal morphology in the majority of subjects (69 per cent) regardless of gender, skeletal type and age. Thus, variation in linear dimensions and morphology of sella was found in this study, which can be used as standard for further investigations involving sella turcica in Indian population.

INTRODUCTION

The sella turcica is a saddle-shaped depression in the body of the sphenoid bone of the human skull. The seat of saddle holds the pituitary gland. It belongs to the middle cranial fossa and serves as an important cephalometric landmark in orthodontics. The centre of the sella turcica was defined as the s-point by Bjork (1947). Sella turcica is used as a reference point with nasion to establish the base of the skull in cephalometric analysis. It not only helps when evaluating cranial morphology, but also when growth changes and orthodontic treatment results are

evaluated. This line marks the important landmark to evaluate the relative position of jaws with respect to cranium^{1, 2}.

The anatomy of sella shows variations in shape as the round, flat and oval. The morphological variation depends upon contours of the sella floor, the angles formed by the contours of anterior and posterior clinoid processes and tuberculum sellae. The structures that seem to exhibit the greatest variation in connection with sella turcica are the anterior and

* Corresponding author: Pooja Wajekar, B G- 02, Vindiyachal Hostel, VSPM dental college, Lata Mangeshkar Hospital, Hingna road, Dighod hill, Nagpur – 440019, Maharashtra. pooja.wajekar@gmail.com, mobile no – 9773440977.

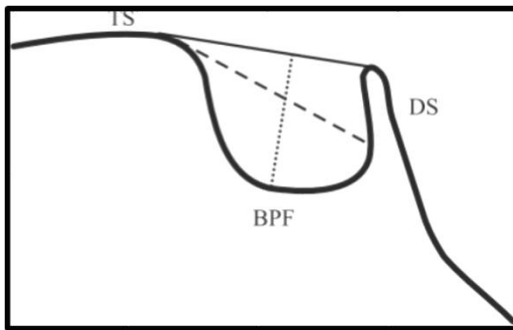


Figure 1 – Reference lines for evaluating size of sella.

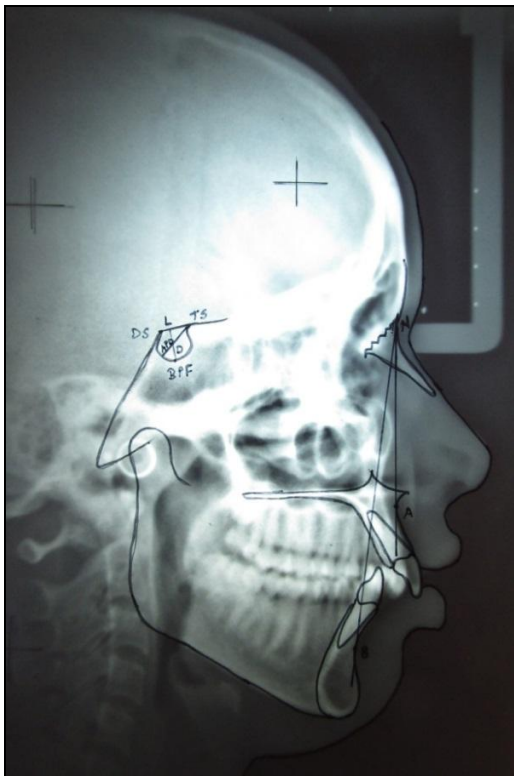


Figure 2 – Tracing showing evaluation of skeletal pattern and size of sella

posterior clinoid processes, fusion of which result as sella turcica bridge. Carstens (1949) investigated for sella turcica bridge in 461 young healthy men and found its incidence in 4.6% of subjects. Also J.P Becktor investigated and demonstrated an increased occurrence of sella turcica bridge in individuals with craniofacial deviations³.

The size of sella turcica was seen to be increased radiographically due to adenomas,

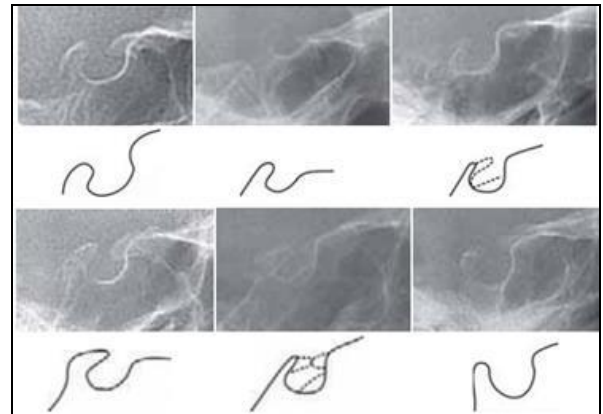


Figure 3 - Different morphological shapes of sella turcica

meningioma, primary hypothyroidism, prolactinoma, gigantism, acromegaly, empty Sella syndrome, and Nelson syndrome. Also reduction in the size of sella turcica has been found associated with decreased pituitary function causing symptoms such as short stature and retarded skeletal growth⁴.

Variation in size and morphology of sella turcica from individual to individual has been reported and hence establishment of normal standards will help in process of eliminating any abnormality in such an important region⁵.

Therefore, the purpose of the study is to analyse the morphological shape and measure the linear dimensions of the sella turcica to determine if any differences exist due to gender or if in subjects with different skeletal patterns among the central India population.

MATERIAL AND METHOD

The lateral cephalograms of the subjects having Class I, Class II and Class III skeletal base were selected from the existing records of the patients in the Department of Orthodontics, V.S.P.M Dental College, Nagpur. A detailed demographic data was collected from each patient and the subjects belonging to central

India population originally were selected as samples for the study.

Cephalometric radiographs of 120 (60 males and 60 females) subjects were distributed according to the skeletal class and gender; 40 Class I, 40 Class II and 40 Class III with an equal distribution between males and females in each class (20 males and 20 females).

INCLUSION CRITERIA

Subjects are in the age group of 18-25 years.

Only radiographs that have clearest reproduction of the sella turcica area are selected.

Classification of skeletal type was based on the ANB angle (SNA and SNB). The ANB angle indicates the magnitude of the skeletal jaw discrepancy, regardless of which jaw is at fault.

Skeletal base Class will be categorised as follows:

ANB angle 0 - 4 degrees – Class I skeletal base

ANB angle more than 4 degrees – Class II skeletal base

ANB angle less than 0 degrees – Class III skeletal base

METHOD

Sella turcica on each cephalometric radiograph was traced on a thin acetate paper under optimal illumination and it was superimposed on a graph paper marked in square millimetres to calculate the sella area.

The linear dimension of the sella turcica was measured using the method of Silverman (1957)⁶ and Kisling (1966)⁷.

Size of Sella Turcica was determined with following landmarks (Figure 1, 2) –

Length – the distance between the tuberculum sella to the tip of dorsum sella.

Depth – a line perpendicular to the line drawn above to the deepest point on the floor.

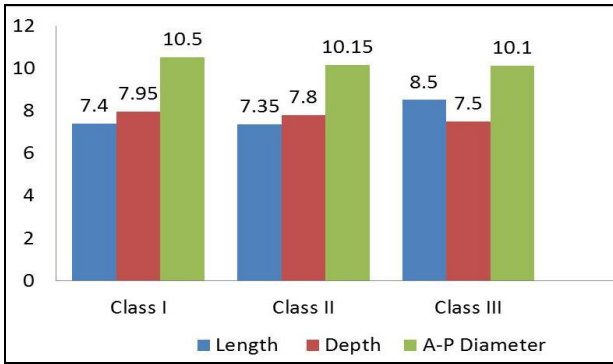
Antero-posterior diameter – line drawn from the tuberculum sella to the most posterior point on the posterior inner wall of the fossa.

To determine the variation in shapes of the sella turcica, the different morphological appearances of sella (Axelsson 2004) (Figure 3) was used and compared with the current study. These variations are oblique anterior wall, double contour of floor, sella turcica bridging, irregularity in posterior part of dorsum sellae, pyramidal shape of the dorsum and double contour of the floor.

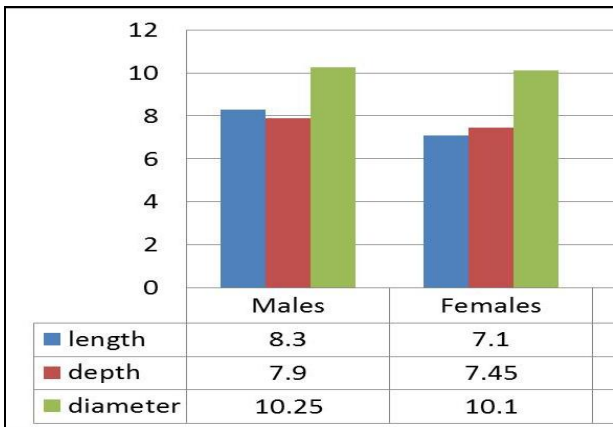
STATISTICAL ANALYSIS – Data on shape and morphology of sella turcica was obtained for skeletal class I, class II and class III subjects. Data were entered in Microsoft excel and analyzed using SPSS ver 20.0 (IBM Corp.) software and the statistical significance was tested at 5% level. The statistical comparison of linear dimensions of sella turcica in males and females was performed using student's t-test. One way ANOVA test was done to determine if there was any difference in linear dimensions among the skeletal types. A multiple comparison test was used to further distinguish which skeletal Class showed the most significant difference in diameter size.

RESULTS

Size of sella turcica- One-way ANOVA was performed to determine if there was any difference in linear dimensions among different skeletal patterns, irrespective of any age and gender (graph 1). A significant difference was noted between skeletal class and length of sella turcica. Length of sella turcica was



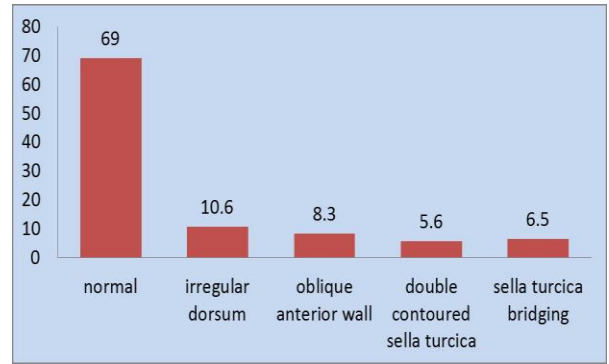
Graph 1 – comparison of sella turcica size in different skeletal types.



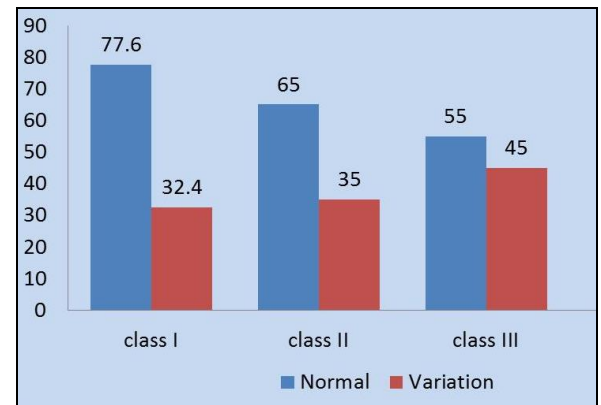
Graph 2 – Linear dimensions of sella turcica for Males and Females.

noted to be more in skeletal class III when compared to skeletal class II subjects ($P < 0.004$). When comparing linear dimensions of sella turcica between genders, statistical difference was found in size of sella turcica (graph 2). Length was more in males ($P < 0.002$) when compared with females.

Shape of sella turcica- The morphology of the sella turcica appeared to be normal in shape in the majority of subjects (69 %), regardless of gender, age, or skeletal type (graph 3). Variation in morphological appearance was present in 31 % of the individuals. An irregular dorsum sella was found in 10.6 %, while an oblique anterior wall was found in 8.3 %, a double-contoured sella turcica were present in 5.6 % and sella turcica bridging was found in 6.5% subjects. The most common variation seen was irregular dorsum.



Graph 3 - Shape of Sella Turcica regardless of skeletal type and Gender



Graph 4 - Morphology of Sella Turcica for different skeletal bases

Morphology of sella turcica for each of the skeletal type was found as- 77.6 % of class I subjects had normal morphology of sella turcica while 32.4 % subjects showed variations. In class II subjects, 65% had normal morphology while 36% had variations. Similarly class III subjects, 55% had normal morphology while 45% subjects exhibited variations (graph 4).

DISCUSSION

This study describes the shape and size of sella turcica in three different skeletal types and in both the genders.

Size of sella turcica –

Skeletal and craniofacial growth show great variation due to sexual dimorphism and regional growth difference which occur under the influence of

hormones which are in turn under the control of pituitary gland and its related structures. Numerous studies are conducted to investigate the effect of diseases on size and shape of sella turcica, and have found no influence with regards to mongolism, anterior pituitary deficiency, mental retardation, and hyper- and hypothyroidism⁵.

Charles B. Preston⁵, in 1979 studied pituitary fossa size and facial types and found no significant differences. In this study the size (length, depth, A-P diameter) of sella turcica was compared with the skeletal types – class I, class II and class III. There was significant difference seen with length of sella turcica and the skeletal types. The depth and A-P diameter did not show any statistically significant difference in all the three skeletal types. The length of sella was found to be significantly larger in skeletal class III subjects. These results are consistent with the observation of Satyanarayan⁹ et al, 2015 who found a significant increase in the size of sella in skeletal class III subjects. Also Alkofide⁸ et al 2007, compared the size of sella in three skeletal patterns and found that the size was smaller in class II subjects and larger in skeletal class III subjects. In contrast to these results, Ahsan Mahmood Shah¹⁰ in 2011, found no significant difference in any of the three dimensions as in length, depth or diameter when compared to the skeletal types. Also Yassir A¹¹ 2010, studied size of sella in three skeletal types in Iraqi population and found no significant difference.

When linear dimensions of sella were compared in males and females, it was found to be statistically significant. The length of sella was found to be more in males than in females. The depth and A-P diameter did not show any significant difference between the gender. These results are in accordance with those

found by Satyanarayan⁹ et al, who noted significant increase in length in males than in females. Also Axelsson² et al in 2004 compared size of sella turcica in Norwegian samples and found no differences in diameter and depth between males and females while the length was larger in males. On contrary to these results various authors have reported no sexual dimorphism for the linear dimensions of sella. Studies done by Yassir et al¹¹. 2010 in Iraq population, Shah et al¹⁰. 2011 in Pakistan population, Filipovic et al¹². 2011 in Nisi subjects, Chavan et al¹³. 2012 in Maharashtra population, Osunwoke et al¹⁴. 2014 in Nigerian population, where between genders no significant difference was found in terms of linear dimensions of sella.

Shape of sella turcica –

The morphological variations in sella turcica have been reported by many researchers through time. Gordon and Bell¹⁵ studied the sellae of 104 normal children and divided the sellae in these children into three general groups according to shape, namely, circular, oval, and flat. The oval sellae were the most common and were seen in 67 percent of the children, while the flat type was the rarest and was always found in small heads. Later different other shapes of sellae were studied and introduced. Davidoff and Epstein¹⁶ in 1950 used the term J shaped sella while omega sella, another shape was introduced by Pournier and Denizet in 1965¹⁷. Tetradis and Kantor¹⁸ in 1999 studied the normal variations of sella turcica morphology seen on lateral cephalometric radiographs and divided them as - shallow, J-shaped, double floor, and middle clinoid process. In the present study the morphological variation of sella was studied by comparing them with the morphological types as described by Axelsson² in 2004. The normal variation

of sella turcica was seen in 2/3rd of the subjects while the remaining subjects showed dysmorphological appearance. Five different morphological aberrations were identified and described – oblique anterior wall, sella turcica bridging, double contour of the floor, irregularity (notching) in the posterior part of the dorsum sellae, and pyramidal shape of the dorsum sellae.

In this study the morphology of the sella turcica appeared to be normal in shape in the majority of subjects (69 %), regardless of gender, age, or skeletal type with 31% of subjects showing variation. These findings are in accordance to those of Alkofide⁸ et al who found normal morphology of sella turcica in 67% subjects while 33% presented with different aberrations. Sathyanarayan⁹ et al also found normal morphology in majority of subjects (61%) and morphological variation was seen in 39% subjects. In the study conducted by Shah AM¹⁰ in Pakistani population normal variation was observed in 66% of the subjects whereas 36 % with different variation. Yassir et al¹¹. studied the morphological variation in Iraq population and found 71.15% subjects with normal morphology. In contrast to the above findings, in the study done by Nagaraj T⁴. morphology of sella turcica appeared to be normal shape in 46.5% of the study population and morphological variations in shape were seen in 53.5% of study population. Also in a study done by Chauhan et al¹³, 2014 only 28% of the subjects appeared to have a normal shaped sella turcica, while 72% presented with different shapes.

The morphologic variations presented by sella were seen in following frequency - An irregular dorsum sella was found in 10.6 %, while an oblique anterior wall was found in 8.3 %, a double-contoured sella turcica were present in 5.6 % and sella turcica bridging

was found in 6.5% subjects. Thus, irregular dorsum was commonly seen variation. This was in agreement with finding of Axelsson² et al with irregular notching of dorsum sella in 11% of subjects.

When morphology of sella was compared with the skeletal types, maximum variation was seen in skeletal class III subjects (45%) as compared to skeletal class I and class II subjects. This is in accordance in to the findings by Sathyanarayan et al⁹, who found variation in 52% subjects. In contrast to the above findings, Shah AM¹⁰, found minimal variations in class III subjects with 72% of subjects with normal morphology. Busch²⁰ and Platzner²¹ reported the prevalence of sella turcica bridge with a frequency of 1.75 to 6 % in the 'normal' population. Becktor³ et al and Jones²² et al studied patients with severe craniofacial deviations who required combined surgical orthodontic treatment and found sella turcica bridging in 18.6% and 16.7% of subjects respectively. In the present study 6.5% of subjects had sella turcica bridging.

The variation in the linear dimensions and morphology of sella turcica with respect to other studies can be attributable to ethnicity and geographic variation.

CONCLUSION

When size of sella turcica was compared with skeletal types, there were significant differences between class II and class III subjects. Length was larger in class III subjects.

There was a significant difference in size of sella turcica between two genders with males showing longer dimension of sella than the females.

Shape of sella turcica was normal in 69% of subjects among the central India population.

REFERENCES

1. Kjær I. Sella turcica morphology and the pituitary gland—a new contribution to craniofacial diagnostics based on histology and neuroradiology. *Eur J Orthod* 2012 Nov 16;37(1):28-36.
2. Axelsson S, Storhaug K, Kjaer I. Post natal size and morphology of the sella turcica . Longitudinal cephalometric standards for Norwegians between 6 and 21 years of age. *Eur J Orthod* 2004;26:597-604.
3. Becktor JP, Einersen S, Kjær I. A sella turcica bridge in subjects with severe craniofacial deviations. *Eur J Orthod* 2000 Feb 1;22(1):69-74.
4. Tejavathi Nagaraj R, James L, Keerthi I, Balraj L, Goswami RD. The size and morphology of sella turcica: A lateral cephalometric study.
5. Preston CB. Pituitary fossa size and facial type. *Am J Orthod*. 1979 Mar 1;75(3):259-63.
6. Silverman FN. Roentgen standards for size of the pituitary fossa from infancy through adolescence. *Am J Roentgenol Radium Ther Nucl Med* 1957;78:451-60.
7. Kisling E 1966 Cranial morphology in Down's syndrome. A comparative
8. roentgencephalometric study in adult males Thesis, Munksgaard ,
9. Copenhagen
10. Alkofide EA. The shape and size of the sella turcica in skeletal Class I, Class II, and Class III Saudi subjects. *Eur J Orthod* 2007 Aug 9;29(5):457-63.
11. Sathyanarayana HP, KV CA. The Size and Morphology of SellaTurcica in Different Skeletal Patterns among South Indian Population: A Lateral Cephalometric Study. *Journal of Indian Orthodontic Society*. 2013 Jan 1;47(4):266-71.
12. Shah AM, Bashir U, Ilyas T. The shape and size of the sella turcica in skeletal Class I, II and III in patients presenting at Islamic International Dental Hospital, Islamabad. *Pak. Oral Dental J* 2011 Jun 1;31(1).
13. Yassir AY, Nahidh M, Yousif HA. Size and morphology of sella turcica in Iraqi adults. *Mustansiria Dent J*. 2010;7:23-30.
14. Filipović G, Burić M, Janošević M, Stošić M. Radiological measuring of sella turcica's size in different malocclusions. *Acta stomatologica Naissi*. 2011;27(63):1035-41.
15. Chavan SR, Kathole MA, Katti AS, Herekar NG. Radiological analysis of sella turcica. *Int J Recent Trends Sci Technol* 2012;4:36-40.
16. Osunwoke EA, Mokwe CR, Amah-Tariah FS. Radiologic measurements of the sella turcica in an adult Nigerian population. *Int J Pharm Res* 2014;4:115-7
17. Gordon, M. B., and Bell, A. L. L.: The roentgenographic findings of sella turcica in 104 normal children, *N. Y. State J. Med.* 22: 54, 1922.
18. Davidoff L M , Epstein B S 1950 The abnormal pneumoencephalogram. Lea and Febiger , Philadelphia.
19. Fournier A M , Denizet D 1965 Omega shaped sella turcica . *Marseille Medical* 102 : 503 – 509.
20. Tetradis S, Kantor ML. Prevalence of skeletal and dental anomalies and normal variants seen in cephalometric and other radiographs of

- orthodontic patients. *Am J Orthod Dentofacial Orthop* 1999;116:572-77.
21. Chauhan P, Kalra S, Mongia SM, Ali S, Anurag A. Morphometric analysis of sella turcica in North Indian population: a radiological study. *International Journal of Research in Medical Sciences*. 2017 Jan 23;2(2):521-6.
 22. Busch W. The morphology of sella turcica and its relationship to the pituitary gland. *Virchow's archive*. 1951 Sep 1; 320 (5): 437-58.
 23. Platzer W. On the anatomy of the "Sella Bridge" and its relation to the internal carotid artery. *InRöFo Advances in X-ray and Imaging* 1957 Nov (Vol 87, No. 11, pp. 613-616). © Georg Thieme Verlag KG Stuttgart · New York.
 24. Jones RM, Faqir A, Millett DT, Moos KF, McHugh S. Bridging and dimensions of sella turcica in subjects treated by surgical-orthodontic means or orthodontics only. *Angle Orthod*. 2005 Sep;75(5):714-8.