

Case Report

A Case Report of Intramucosal Nevus on Hard palate

Neha Pruthi¹, Geetpriya Kaur²

¹ Consultant Oral and maxillofacial pathologist, Paradise Diagnostics, New Delhi

² Director, Paradise Diagnostics, New Delhi

ARTICLE INFO



Keywords:

melanocytes, nevus, palate

ABSTRACT

Oral melanotic nevi are uncommon oral lesions causing focal pigmentation. Melanotic nevi are benign melanocytic tumors originating from defective melanoblasts of the neural crest. Clinically, it is an asymptomatic, flat or slightly elevated lesion of brown or brown-black color. In present study, we reported a case of intramucosal nevus in 23 years old male patient on hard palate.

Introduction

Oral pigmentation may be exogenous or endogenous in origin. Exogenous pigmentation is commonly due to foreignbody implantation in the oral mucosa. Endogenous pigments include melanin, hemoglobin, hemosiderin and carotene. Pigmented lesions caused by increased melanin deposition may be brown, blue, grey or black; depending on the amount and location of melanin in the tissues.¹

Melanin is produced by melanocytes in the basal layer of the epithelium and is transferred to adjacent keratinocytes via membrane-bound organelles called melanosomes. Melanin is also synthesized by nevus cells, which are derived from the neural crest and are found in the skin and mucosa. Pigmented nevi are rare causes of focal oral pigmentation. They present as either brown or blue lesions.²

Although nevi are common lesions that are seen on the skin in the large majority of the population, they are rare intraorally. They can be seen in persons of all ages and are usually less than 5 mm in diameter. When seen intraorally, they are most commonly observed on the hard palate. Clinically, pigmented nevus is an asymptomatic, flat or slightly elevated spot or plaque of brown or brown-black color.³ In this article we have described a rare case report of nevus present on hard palate.

CASE REPORT

A 23 years old male patient reported to the department with chief complaint of black discoloration on right side of palate (Fig- 1). History revealed that black discoloration was present since childhood. There was no other discoloration elsewhere intraorally or extra

* Corresponding author: Neha Pruthi, Consultant Oral and maxillofacial pathologist, Paradise Diagnostics, New Delhi

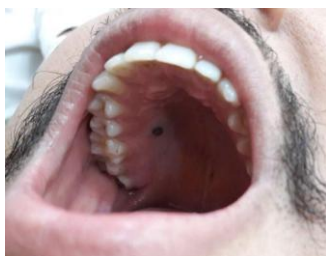

Fig- 1 Black discoloration on hard palate.

orally. There was no associated history of pain and any discharge.

On examination, an oval shaped, well defined black discolored lesion was present on right side of hard palate 1 cm lateral to the first molar. It was flat, firm and measures approximately 5mm in maximum dimension. Based upon the history and clinical examination a provisional diagnosis of melanotic nevus was given with the differential diagnosis of melanoma, oral melanocytic macule, amalgam tattoo and peripheral metastasis.

Excisional biopsy was done and the lesion was sent for histopathological analysis which showed hyperplastic parakeratinized stratified squamous epithelium with areas of atrophy in between. The underlying connective tissue stroma contained collections of nevus cells in the form of islands and sheets. Of these superficial nevus cells were large and contained melanin pigment. At areas nevus cells also showed cellular atypia. The intervening scanty connective tissue stroma was delicately collagenous with mild chronic inflammatory infiltrate (Fig- 2). Features were suggestive of intramucosal nevus.

DISCUSSION

Oral melanocytic nevi are benign tumors of melanocytes, the pigment producing cells found in the skin and in juxta cutaneous mucous membranes,

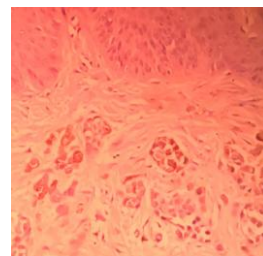


Fig- 2 Histopathological examination shows connective tissue stroma with collections of nevus cells in the form of islands and sheets.

including the oral mucosa. Oral melanocytic nevi are rare, and their etiology and pathogenesis are poorly understood.⁴

Field and Ackermann⁵ in 1943 first documented case of intraoral nevus. The term intralamina propria nevus was first proposed by Comerford. Later King et al⁶ adopted the term, intramucosal nevus. It most frequently occurs in female patients and in the third and fourth decades of life. The mean ages of patients with oral nevi are between 30 and 38 years. The common site for occurrence is hard palate, followed by the buccal mucosa and least seen on vermillion border. Or die H. et al⁷ in 1967 reported that pigmented nevi of the oral cavity had been found in 0.1 per cent of the Negro patients examined at his medical Center. They also found in their study that pigmented nevus of the oral cavity was a relatively common lesion which was usually overlooked because of its small size and innocuous behavior.

In present study, we reported nevus on hard palate in male patient. Differential diagnosis of melanoma was considered because of the presence of black discoloration. Amalgam tattoo can be excluded since there was no associated drug history and moreover, there was no adjacent restoration (amalgam) in the tooth which may cause the lesion. Peripheral metastasis was excluded since there was no other malignant lesion in the body.

Nevi may also be classified as congenital or acquired. The etiology and pathogenesis of Oral melanocytic nevi are poorly understood even though, as for their cutaneous counterpart, oncogenic mutations of genes coding for components of the RAS signaling pathways may play a role. Based on location of the nevus cells, cutaneous nevi can be classified into 3 groups. The first group, junctional nevus, is when nevus cells are limited to the basal cell layer of the epithelium. The second group, compound nevus, is used if the cells are in the epidermis and dermis. The third group, intradermal nevus, is when nests of nevus cells are entirely in the dermis. In oral nevi intradermal nevus is replaced by the term intramucosal nevus. In our study there was intramucosal nevus histopathologically.⁸

Buchner A. et al⁹ analyzed 773 cases of solitary pigmented melanocytic lesions in the oral mucosa and revealed that oral melanocytic nevi comprised 11.8% of the entire melanocytic group with mean age at diagnosis being 30.5 years and palate the most common site. Diagnosis of pigmented lesions of the oral cavity and perioral tissues is challenging. Clinicians should evaluate and diagnose all alterations in pigment. But definitive diagnosis usually requires histopathological evaluation.

Conclusion

Pigmented lesions of oral cavity are not uncommon. Oral melanocytic nevus is quite common on hard palate which was present in present study. Careful examination is required followed by histopathological examination to reach the diagnosis.

REFERENCES

1. Eisen D. Disorders of pigmentation in the oral cavity. *Clin Dermatol* 2000; 18(5):579–87.
2. MacKie RM, English J, Aitchinson TC, Fitzsimons CP, Wilson P. The number and distribution of benign pigmented moles (melanocytic nevi) in healthy British population. *Br J Dermatol* 1985;113(2):167–74.
3. Laskaris G, Kittas C, Triantafyllou A. Unpigmented nevus of the palate: An unusual clinical presentation. *Int J Oral Maxillofac Surg* 1994; 23:39–4.
4. Craig L. Hatch. Pigmented lesions of the oral cavity. *Dental Clinics of North America* 2005; 49(1):185-20.
5. Field HJ, Ackerman AA. Non-pigmented nevus on labial mucosa. *Am J Orthodontics Oral Surg.* 1943;29:180-1.
6. King OH, Blankenship JP, King WA, Coleman SA. The frequency of pigmented nevi in the oral cavity. Report of five cases. *Oral Surg Oral Med Oral Pathol* 1967;23(1):82-90.
7. Ordie H, King Jr., Jimmy P. Blankenship, William A, Sidney A. Coleman. The frequency of pigmented nevi in the oral cavity: Report of five cases. *Oral Surg, Oral Med, Oral Pathol* 1967; 23(1): 82-90.
8. Meleti M, Mooi WJ, Casparie M, van derWaal I. Melanocytic nevi of the oral mucosa: No evidence of increased risk for oral malignant melanoma: an analysis of 119 cases. *Oral Oncology* 2007; 43:976–981.
9. Buchner A, Hansen LS. Pigmented nevi of the oral mucosa: A clinicopathologic study of 32 new cases and review of 75 cases from the literature: Part I. A clinicopathologic study of 32 new cases. *Oral Surgery, Oral Medicine, Oral Pathology* 1979; 48(2):131-142.