

Case Report

Surgical repositioning of an aberrant attachment of buccinator muscle: A novel approach to a rare occurrence

Neil De Souza¹, Paul Chalakkal², Godwin Clovis Da Costa³, Saurabh Kamat⁴, Sergio Martires⁵, Renita Soares⁶

¹ Lecturer, Department of Pedodontics and Preventive Dentistry, Government Dental College and Hospital, Bambolim, Goa

² Assistant Professor, Department of Pedodontics and Preventive Dentistry, Government Dental College and Hospital, Bambolim, Goa

³ Lecturer, Department of Prosthodontics, Government Dental college, Bambolim Goa

⁴ Lecturer, department of Oral Surgery, Government dental college, Bambolim Goa

⁵ Senior Resident, Department of Orthodontics, Government Dental College and Hospital, Bambolim, Goa

⁶ Senior Resident, Department of Conservative dentistry and Endodontics, Government Dental College and Hospital, Bambolim, Goa.

ARTICLE INFO



Keywords:

abnormal; surgical repositioning;
hypertrophy; fibres; masticatory
muscles

ABSTRACT

Anatomical anomalies routinely result in restriction of movement and function, thus leading to emotional, functional and psychosocial complications. An aberrant crestal attachment of the buccinator muscle is an uncommon occurrence, which can result in impaired oral exercises and functionality. This case report describes a rare case of abnormal attachment of the buccinator muscle on the alveolar ridge of the mandible in an 8 year old male child. It was successfully managed by surgically repositioning the aberrant muscle attachment, resulting in a favourable post-operative outcome.

INTRODUCTION

CASE REPORT

An 8 year old male child reported to the department of Pedodontics with the complaint of a thick band of tissue attached between his cheek and the lower jaw on the right side, which had resulted in hindrance in the movement of his right cheek while eating and yawning. Intra-oral examination revealed a band of soft tissue resembling a hypertrophic frenum, attached between the inner portion of the right cheek and the alveolar ridge, in the region of the first primary molar (Figure 1). This had resulted in obliteration of the vestibular sulcus in that area. Based on anatomical

landmarks and the consistency of the tissue, a diagnosis of abnormal attachment of the buccinator muscle was made. It was decided to surgically reposition the abnormal muscle attachment apically, in order to obtain sufficient vestibular sulcus depth. The necessary haematological investigations were carried out and were within normal limits. Radiographically adjacent teeth showed no periapical pathology.

After explanation of the surgical procedure to be undertaken, along with its advantages and possible disadvantages, a written consent was obtained from the parents.

Under local anaesthesia (2% lignocaine with 1:80,000

* Corresponding author: Neil J De Souza, Lecturer, Department of Pedodontics and Preventive Dentistry, Government Dental College and Hospital, Bambolim, Goa 403202, Email address: neildoc86@gmail.com, desouzaorama@gmail.com, Phone No : +91- 9922087494, 7350433344, 0832-2735076

adrenalin), the portion of the buccinator muscle attached to the alveolar ridge was excised with an

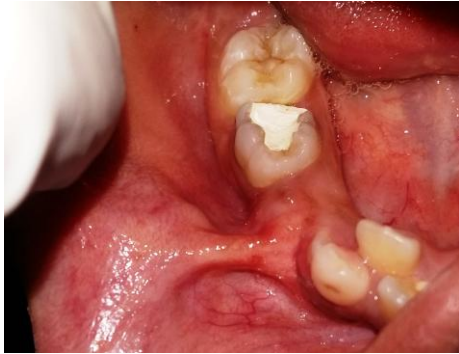

Figure 1: Abnormal buccinator attachment on the buccal side of the mandibular alveolar ridge

inverted 'V' shaped incision that continued 2.0 cm inferiorly, while keeping the periosteum intact (Figures 2a, 2b and 2c). The achieved vestibular depth and muscle repositioning was checked by retracting the cheek. After adequate vestibular depth was achieved, the area was irrigated, bleeding controlled and interrupted sutures using resorbable vicryl were placed (Figure 2d). The vestibular depth obtained was reassessed by gently retracting the cheek, following which, postoperative instructions were given.

Amoxicillin 250 mg tablets were prescribed for consumption twice daily for 5 days. A mouth rinse (0.2% chlorhexidine) was also prescribed for use twice daily for 10 days. The wound healed uneventfully after 10 days and sufficient vestibular depth had been established. The patient was satisfied with the result and did not experience any restriction during mastication and jaw movement. The patient was kept under observation for a period of two years. Two year follow up revealed no relapse of the aberrant attachment and successful eruption of the permanent premolar. (Figure 3)

DISCUSSION

The buccinator muscle is a square-shaped, bilateral muscle present in the cheek. It is classified as an accessory muscle of mastication due to its role in

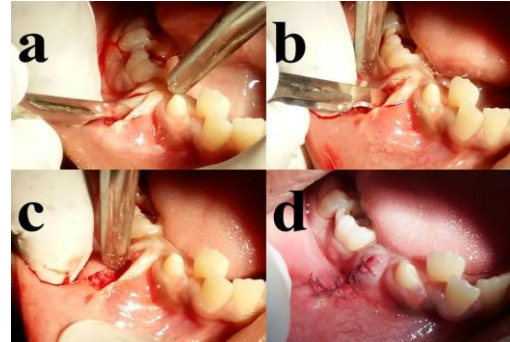


Figure 2a: Inverted 'V' shaped incision

Figure 2b: Removal of the aberrant muscle attachment.

Figure 2c: The defect after removal of the aberrant muscle attachment

Figure 2d: Post-operative interrupted sutures.

chewing, swallowing, sucking, whistling, blowing and compressing cheeks against the molars.¹ Functions such as mastication, swallowing, sucking, blowing, pronouncing vowels and coughing are carried out by the simultaneous actions of buccinator, orbicularis oris and superior constrictor muscles. Out of these, the buccinator and orbicularis oris muscles facilitate swallowing by causing peristaltic wave-like contractions originating anteriorly, towards the pharyngeal region.² Since buccinator muscle fibres extend into the terminal portion of the Stenson's fibersduct, its role in dilating the parotid duct has also been suggested.³ However, a previous study has disproved the role of the buccinator as a sphincter in the secretion of the parotid glands.⁴ Its fibres originate from the buccal surfaces of the maxilla (upper fibres) and the mandible (lower fibres), near the molar sockets, and insert into the upper and lower lips, respectively. Its middle fibres originate from the Pterygomandibular raphe and decussate at the corner of the mouth and blend with the orbicularis oris.⁵

However, the muscle may pose discomfort due to a rare aberrant attachment on the alveolar ridge via a thick and wide frenum in the molar region, near its

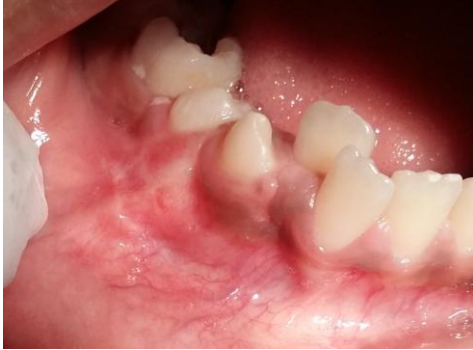

Figure 3: Two years post-operative photograph

origin. The abnormal attachment may result in problems related to oral hygiene maintenance, prosthodontic treatment, mastication, speech and lip and cheek movements. Only one such case has been previously reported in literature.⁶

The development of the abnormal attachment following extraction could result from a decrease in the alveolar ridge height resulting from the traumatic extraction; loss of soft tissue secondary to the traumatic extraction or suturing; decrease in alveolar ridge height secondary to periodontal disease; atrophy in alveolar ridge height due to absence of tooth.⁶ However, in this case, the patient complained of the abnormal attachment to be present much before the loss of the primary first molar. This further added to our diagnosis of abnormal attachment of the buccinator muscle. During the development of face and the arrival of deciduous teeth, the attachment of buccinator displaces downwards and posteriorly.⁴ The abnormal higher attachment of the buccinator at the mandibular alveolar ridge in this case must have resulted due to failure in the downward displacement of its fibres. Thick and wide frenal or muscle attachments attached to the marginal gingiva or the

alveolar ridge need to be removed.⁷ In the mandible, buccinator attachment is in the region of the premolar and molar, where the alveolar process is shorter in height and the vestibular sulcus is shallow. Frenectomy alone in these cases might still result in a shallow vestibule.⁶ A combination of frenectomy and vestibular extension has also been proposed to aid in relief from muscle attachment and for attaining adequate vestibular depth.⁴ However, in this case, frenectomy alone produced sufficient relief from restricted movement of the cheek during mastication and jaw movements. Moreover, the broad shelf-like projection in this region would make vestibular extension difficult to perform without extensive bone modification.⁸ Surgical acrylic stents also been used for apical positioning of the abnormal buccinator attachment.⁶ Other techniques that have been used in literature to decrease the resistance caused by abnormal muscle attachments and to obtain sufficient vestibular depth are fenestration operation; frenectomy with free gingival grafts; and apical repositioning with free gingival grafts.⁶ Gingival augmentation has also been proposed as a method.⁹ In patients with class II basal malocclusion, surgical marginal myotomy to elongate the buccinator muscle and inferior vestibuloplasty were carried out to relieve the jaw from excessive muscle contraction and to decrease inferior lip hypotone. The above procedures resulted in 80% improvement in cephalometric parameters in patients who underwent surgery followed by orthodontic treatment.¹⁰

CONCLUSION

A conventional frenectomy performed to remove the abnormal buccinator muscle attachment on the mandibular alveolar ridge resulted in a favourable outcome, without any relapse.

REFERENCES

1. D'Andrea E, Barbaix E. Anatomic research on the perioral muscles, functional matrix of the maxillary and mandibular bones. *SurgRadiol Anat.* 2006;28:261–6.
2. Perkins RE, Blanton PL, Biggs NL. Electromyographic analysis of the “Buccinator Mechanism” in Human Beings? *J Dent Res.* 1977;56:783–94.
3. Kang HC, Kwak HH, Hu KS, Youn KH, Jin GC, Fontaine C, et al. An anatomical study of the buccinator muscle fibers that extend to the terminal portion of the parotid duct, and their functional roles in salivary secretion. *J Anat* 2006;208:601–7.
4. Plas E, Deliac P, GaruetLempirou A, Caix P, Bioulac B. The buccinator muscle: an original morphogenetical study. *Morphologie* 2004;88(280):27-30.
5. Romanes GJ. The deeper dissection of face. In: Romanes GJ, editor. *Cunningham’s manual of practical anatomy.* 15th ed (vol 3). New York: Oxford University Press; 1996. pp. 95-104.
6. Baghele ON, Baghele MO. Buccinator muscle repositioning: a case report. *CompendContinEduc Dent* 2012;33(8):98-101.
7. Rosenberg MM. Vestibular alterations in Periodontics. *J Periodontol*1960;31:231–7.
8. Bradin M. Precautions and hazards in periodontal surgery. *J Periodontol.* 1962;33:154–63.
9. Consensus Report. Mucogingival therapy. *Ann Periodontol.* 1996;1:702–6.
10. Mortellaro C, Manuzzi W, Caligiuri F, Vota A, Pavese M, Di Vincenzo S, et al. Surgical buccinator muscle myotomy in dentoskeletal Class II alterations. *J CraniofacSurg* 2001;12(5):409-26.