

Fixation of Mandibular angle fractures with a 3 –dimensional strut plate – a prospective study

Debasis Sahu¹, Khochai Chiang², Shilpa Jain³, Arpit Jain⁴

¹ Assistant Professor, Department of Oral and maxillofacial surgery, Sree Sai Dental College & Research Institute, Srikakulam (A.P)

² Assistant Professor, Department of oral and maxillofacial surgery, Gitam Dental College & Hospital, Vishakhapatnam (A.P)

³ Assistant Professor, department of Prosthodontics, crown& bridge & Implantology, Rishiraj college of dental sciences, Bhopal (M.P)

⁴ Assistant Professor, department of Oral Medicine & Radiology, Rishiraj college of dental sciences, Bhopal (M.P)

ARTICLE INFO



Keywords:

3-D strut plates, internal fixation, open reduction, osteosynthesis, wound dehiscence.

ABSTRACT

INTRODUCTION- Mandibular angle is one of the most common site for the fracture (20-30 %) that may result from sports injury, road traffic accidents, sports injury, pathology or falls. Various techniques have been described in the past like internal fixation or open reduction to treat these conditions but the major disadvantage with these was restricted dietary intake. This prospective study uses 3-D strut plates to overcome these problems. **AIMS AND OBJECTIVES-** To evaluate the efficacy of 8 holed 3D strut plate in the management of patients with mandibular angle fracture. **MATERIALS AND METHOD-** This prospective study was conducted on 10 patients sustaining mandibular angle fracture. The transbuccal trocar was inserted through a stab incision in the safe zone. On removing trocar, cheek sleeve was placed. Transbuccal holes were drilled and 8 monocortical screws were inserted to secure the 3D strut plate. Follow up was done on 3rd day, 1st & 3rd week, 1st & 3rd month to evaluate the efficacy of 3-D strut plates. **RESULT-** adequate anatomical reduction, with no signs of inflammation, swelling or malunion of fractured fragments was seen 3 months post operatively in all patients thus demonstrating the efficacy of 3-D strut plates in treatment of Mandibular angle fracture. **CONCLUSION-** within the limitations our study suggests that 3-D strut plates can be effectively used for the treatment of Mandibular angle fracture.

Introduction

Angle fracture accounts for 20%-36% of all mandibular fractures which may be due to interpersonal violence, motor vehicle accidents, falls, sports injury, occupational accidents, and pathology. Different techniques have been described to treat these conditions with major disadvantage being restricted dietary intake. This has forced surgeons to look for different methods like open reduction and internal fixation (ORIF). Despite many advances in internal fixation, angle fractures remains most difficult and unpredictable to treat. During the last decade significant attention has been placed on fixation using

mini plates secured with monocortical screws that had simplified surgery and reduced surgical morbidity but it failed to surpass the predictability of rigid fixation.

Primary aim of fracture management is to make patient return to function and to attain anatomic reduction. Placement of large plates through extraoral approach or use of Champy's mini plates is relatively less successful in displaced mandibular angle fractures and can not overcome torsional and occlusal forces. To overcome these shortcomings, 3D strut plates are used that has increased resistance against torque forces. In this study, curved strut plates were used as being anatomically similar to the Mandibular angle region.

Here , 10 patients with mandibular angle fractures were treated by fixation with 3D strut plate hypothesizing that it is one of the easier & best option
AIM AND OBJECTIVE: To evaluate the efficacy of 8 holed 3D strut plate in the management of patients with mandibular angle fracture.

MATERIALS AND METHODOLOGY-

This prospective study was conducted on 10 patients sustaining mandibular angle fracture visiting Department of Oral Surgery, in a Dental College and Hospital of south India.

PATIENT SELECTION CRITERIA: Ethical clearance was obtained from the institute and patients who gave their consent for the study were included. While those with infected fractures, medically compromised patients , Age below 18 and above 60 years, patients with significant bone/ soft tissue loss or severly comminuted fracture(i.e. gunshot wound) and those who did not give consent for the study were excluded.

METHODOLOGY- after obtaining demographic details, informed consent, blood investigations and pre operative radiographs, Erich arch bar or eye let wiring was applied and occlusion was achieved. Along with regular titanium trauma kit additional armamentarium used were 8 holed 2mm curved titanium strut plate along with 2mm×6mm & 8mm screws. Transbuccal trocar was used in all cases. Post operatively IMF was applied to those with Occlusal derangement. A pressure dressing was applied for 24 – 48 hours. No drains were used. IV antibiotics and analgesics were administered. Soft diet was prescribed for a period of 3-4 weeks.

SURGICAL TECHNIQUE: After achieving general anesthesia and patient preparation, sub mandibular and buccal region of the affected side were exposed.

Fracture fragments were anatomically reduced, occlusion was achieved & I.M.F. was placed. The 3D curved strut plate was adapted approximately to the underlying bone on the lateral surface of mandible such that horizontal cross bars were perpendicular to the fracture line and vertical cross bars were parallel to fracture line. Mono cortical screws were placed perpendicular to the bone by percutaneous transbuccal approach.

The transbuccal trocar was inserted through a stab incision in the safe zone (figure II) and transbuccal tunnel established. On removing trocar, cheek sleeve was placed . Transbuccal holes were drilled using 1.5 mm drill bit. Eight monocortical screws of size 2 x 6 or 2 x 8 mm screws were inserted to secure the 3D strut plate.

IMF was removed, leaving arch bars in place and occlusion was checked. The fixed fracture fragments were checked for adequate reduction. After achieving hemostasis, incision was closed and pressure bandage was placed for 24-48 hours. I.V antibiotics were administered thrice daily for five days, along with analgesic. Liquid diet was prescribed for 3-4 weeks. Follow up was done on 3rd day, 1st & 3rd week, 1st & 3rd month. Preoperatively, oedema, occlusion, step deformity, paresthesia, presence of infection were assessed. Intraoperatively- anatomical reduction, occlusion, no of screws placed and immediate post operatively, reduction of fracture fragment, Position/ proximity of plate and screws to neurovascular structure, root injuries were assessed.

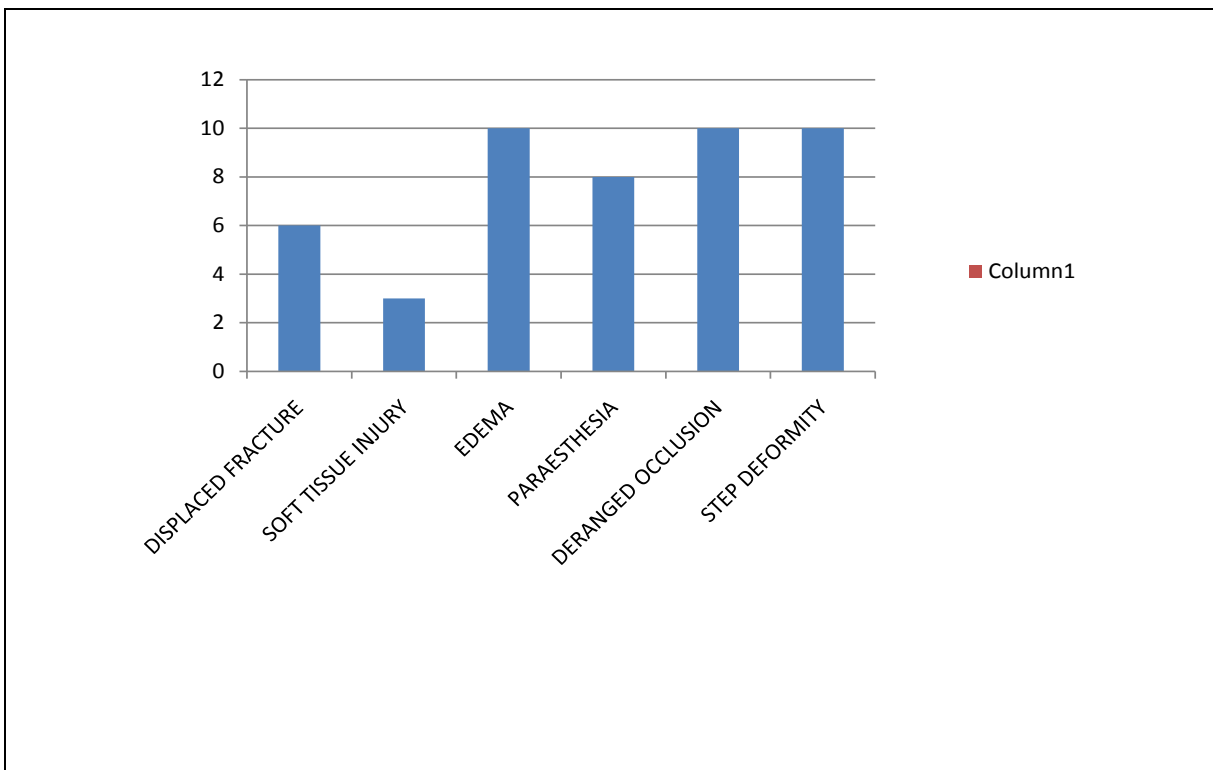
S.NO	AGE	SEX	ETIOLOGY	FRACTURE SITE	DISPLACEMENT	SOFT TISSUE INJURY	OEDEMA	PARESTHESIA	OCCLUSION	STEP DEFORMITY	TEETH IN LINE OF FRACTURE
1	25	M	RTA	Right angle with left parasymphysis	Displaced	Present	Present	Present	Deranged	Present	Present
2	20	M	FALL	Left angle with right body fracture	Not Displaced	Absent	Present	Present	Deranged	Present	Present
3	26	M	FALL	Left angle fracture	Displaced	Absent	Present	Absent	Deranged	Present	Present
4	21	M	ASSAULT	Left angle with right parasymphysis	Displaced	Present	Present	Present	Deranged	Present	Present
5	29	M	FALL	Left angle fracture	Not Displaced	Absent	Present	Absent	Deranged	Present	Present
6	29	M	ASSAULT	Right angle fracture	Not Displaced	Absent	Present	Present	Deranged	Present	Present
7	25	M	RTA	Right angle with left parasymphysis	Displaced	Absent	Present	Present	Deranged	Present	Present
8	27	M	RTA	Left angle with right parasymphysis	Not Displaced	Absent	Present	Present	Deranged	Present	Present
9	40	M	ASSAULT	Left angle fracture	Displaced	Absent	Present	Present	Deranged	Present	Present
10	22	M	RTA	Right angle with left parasymphysis	Displaced	Present	Present	Present	Deranged	Present	Present

Table I: SHOWS DIFFERENT PRE OPERATIVE FEATURES.

RESULTS: 10 patients with Mandibular angle fracture were evaluated for the efficacy of 3D strut plate. Intra operative and post operative parameters evaluated were signs of infection, mobility of the fracture fragments, paresthesia, and intra operative hardware failure. All the cases were evaluated intra-operatively, 3rd day, 1st week, 3rd week, 1st month and 3rd month postoperatively.

Infection was evaluated intra-operatively, 3rd day, 1st week, 3rd week, 1st month and 3rd month. No patient presented with pus formation or discharging sinus or any other signs of infection. All other fracture sites healed uneventfully (**table 2**).

Occlusal discrepancies were assessed intra-operatively, immediate post operatively, 1st and 3rd weeks of operation, 1st and 3rd months post operatively based on



GRAPH I: DIFFERENT PRE OPERATIVE FEATURES

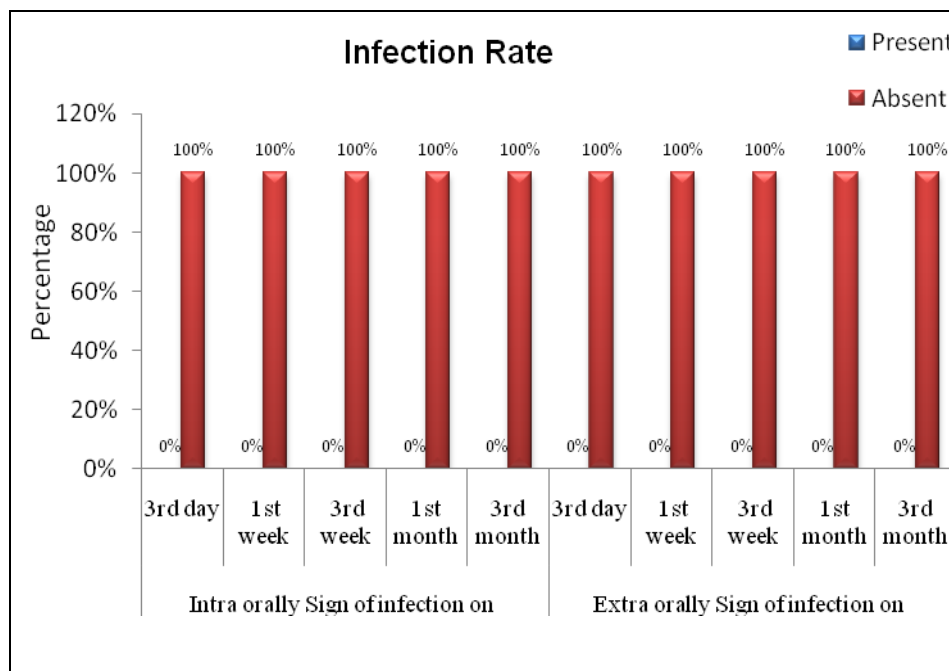
Infection	Present	Absent
Intra orally Sign of infection on 3 rd day	0%	100%
Intra orally Sign of infection on 1 st week	0%	100%
Intra orally Sign of infection on 3 rd week	0%	100%
Intra orally Sign of infection on 1 st month	0%	100%
Intra orally Sign of infection on 3 rd month	0%	100%
Extra orally Sign of infection on 3 rd day	0%	100%
Extra orally Sign of infection on 1 st week	0%	100%
Extra orally Sign of infection on 3 rd week	0%	100%
Extra orally Sign of infection on 1 st month	0%	100%
Extra orally Sign of infection on 3 rd month	0%	100%

TABLE II: INFECTION

clinical examination. There were no reported cases of occlusal discrepancies

Anatomical reduction was assessed by clinical and radiographic examination. In this study 90% anatomical reduction were achieved. Immediate post operative radiograph showed anatomic reduction and alignment of the fractured segments in 9 patients (90%). In one patient, reduction was not achieved intra operatively but at the end of 1st month, it was evident without any signs of step defect or gap formation. At the end of 3rd month, the anatomic reduction was achieved.

Assessment of the involved nerve was done at 3rd day, 1st and 3rd week, 1st and 3rd month postoperatively by static two-point discrimination test. Paresthesia was seen in all patients preoperatively. In 8



GRAPH II: INCIDENCE OF RATE OF INFECTION

patients (80%) post operatively on 3rd day paresthesia was seen, in 4 patients (40%) at 1st week and none of them complains of paresthesia at 3rd week. All sensitivity alterations were noted through Static two-point discrimination test and were more frequently related with concomitant fracture of the parasymphysis region.

SWELLING: was assessed pre operatively, 3rd day, 1st week, 1st month and 3rd months postoperatively. Swelling was observed in all patients preoperatively, in eight patients (80%) post operatively on 3rd day & in two patients (20%) post operatively at end of 1st week. By 3rd week onwards swelling was not clinically evident (**table 4**).

Hardware failure rate was assessed by clinical (intra operatively) and radiographic examination (post operatively at 1st month, 3rd month). None of them had hardware failure in form of fracture of plate or screws or screws loosening (**table 5**)

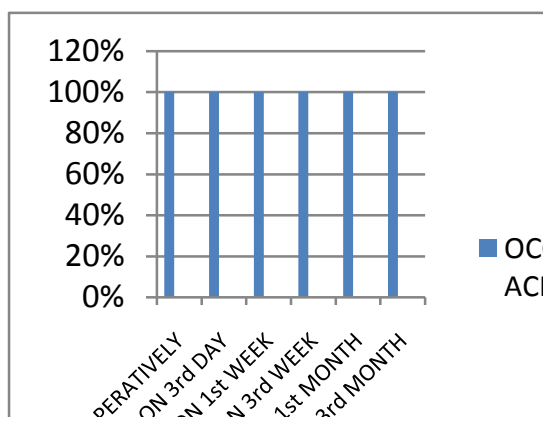
Assessment of stability was done post operatively after 3 months, in fracture fragments were stable & no mobility was detected across fracture fragments.

Malunion and non-union was assessed by radiographic examination postoperatively at the end of 1st and 3rd months. Postoperative evaluation revealed no case of non union or malunion in any of the ten patients.

DISCUSSION- Rapid urbanisation, introduction of high speed automobiles, poor road conditions, road traffic accidents have increased alarmingly. Facial injuries cause both cosmetic and functional disturbances. Mandible which constitutes largest facial bone, by virtue of its position and prominence is one of the commonest sites of fractures. Its peculiar curved pattern and contour, forms the so called jaw line makes it susceptible to trauma. Moreover, mandibular angle fracture is one of the most frequent sites for fracture, accounting for 20%-36% of all

Type	Achieved	Not Achieved
Occlusion in intra operative	100%	0%
Occlusion on 3rd day	100%	0%
Occlusion on 1st week	100%	0%
Occlusion on 3rd week	100%	0%
Occlusion on 1st month	100%	0%
Occlusion on 3rd months	100%	0%

TABLE III: OCCLUSION DATA

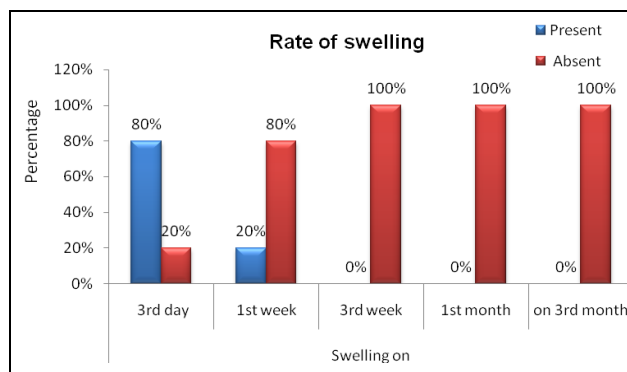


GRAPH III: DATA FOR OCCLUSION

mandibular fractures. Early treatment modalities based on immobilization used either wires, arch bars, cap splints or gunning splints resulting in delayed return of function and diet restriction leading to severe malnutrition. Champy’s miniplate even though made treatment easy, were not successful because of compression, tension and torsional forces. This prompted surgeons to use Luhr’s Vitallium compression plates, dynamic compression plates(DCP), eccentric dynamic compression plates(EDCP), reconstruction plates which gave rigid fixation but also had disadvantages like wider incisions and exposures to accommodate large sized hardware, need of specialized armamentarium and training . Thus, new options that gave better stability, function and require small incision and less exposures

Swelling	Present	Absent
Swelling on 3rd day	80%	20%
Swelling on 1st week	20%	80%
Swelling on 3rd week	0%	100%
Swelling on 1st month	0%	100%
Swelling on 3rd month	0%	100%

TABLE IV: RATE OF SWELLING

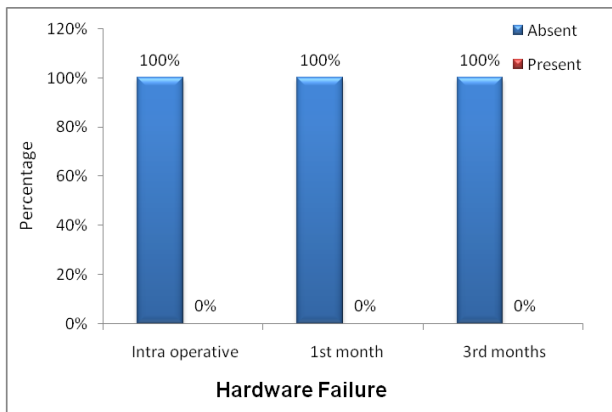


GRAPH IV:SWELLING

were developed. 3D strut plates introduced by Mustafa Farm and had geometry such that it can overcome the muscular activity at the angle region. The concept behind 3-D fixation being that it has geometrically closed quadrangular plate secured with bone screw that create stability in 3 dimensions. The smallest structural component of 3-D plate together with the bone screws is a cube or a square stone. The stability is gained over a defined surface area. On changing the length of each side, geometric arrangement can be altered. This position is essential for optimal stability. The principle of 3-D fixation is based on the idea that the plate is not positioned along the trajectories but over the weak structure lines. The fixation points of the plate remain in the vicinity of the fracture or osteotomy line. Blood is not disturbed much in the fracture site as less dissection is necessary.

Hardware failure	Absent	Present
Intra operative	100%	0%
1st month	100%	0%
3rd months	100%	0%

TABLE V: HARDWARE FAILURE RATE



GRAPH V: HARDWARE FAILURE

Stability of the 3-D plate is achieved by its configuration, not by thickness or length.

Principle of 3-D plate osteosynthesis - Tissue dissection only in the vicinity of the planned osteotomy or fracture line, 3-D plates positioned parallel to the osteotomy or fracture line and the connecting arms of the plate positioned rectangular to the osteotomy or fracture line

Biomechanics of mandibular angle: Understanding the biomechanics of fracture helps clinician choose proper management. Here, mandible acts as class 3 lever. The muscles attaching the mandible creates tensile force at superior border and compressive force at the inferior border. This zone is termed as neutral zone and is found at the level of inferior alveolar nerve, where separation at the superior border and reduction at the inferior border occur during angle fracture under function.²¹ According Zix et al(2007),3D plates were placed near the tension

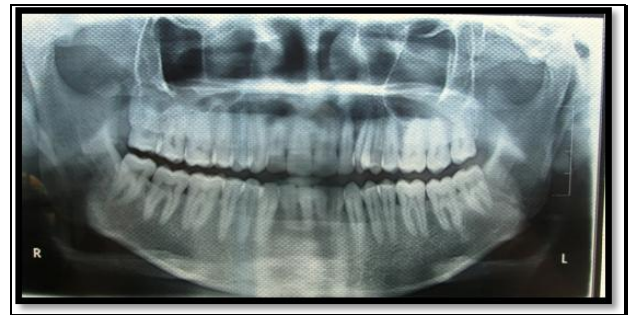

FIGURE I: Preoperative Radiograph

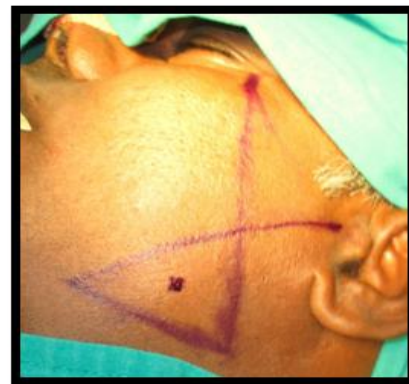

FIGURE II :Line 1 (trans-basal line) ran from the tragus to the groove over the body of mandible, Line 2 (cantho-gonial line) , Line 3 (mandibular line) was the border of the mandible.

trajectories of the mandible. The interconnecting cross struts were placed parallel, toward the fracture line.⁴ In this study, 3D strut plate was used to treat angle fracture. The patients were evaluated for both pre and post surgical occlusal relationship, infection, wound dehiscence, adequacy of reduction on postoperative radiograph, immediate post operative stability and any postsurgical complications requiring a secondary surgical intervention.

The efficacy of 3D – strut plate was demonstrated by the evaluating parameters like stability, paresthesia, infections, wound dehiscence, hardware failure & radiographical parameters such as hardware failure, mal-union and non-union.

No signs of infection were reported in our study, which is comparable to one by Juergen Zix et al(2007)

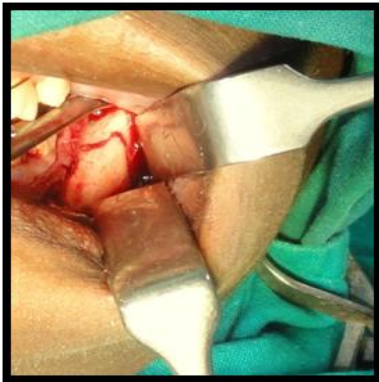

FIGURE III: EXPOSURE OF FRACTURE SITE

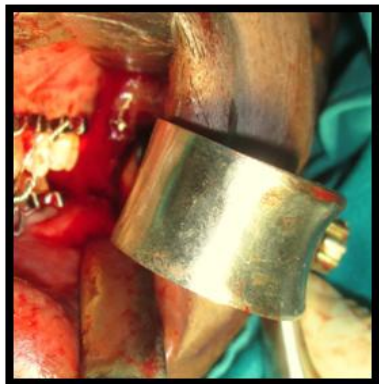


FIGURE IV: PLACEMENT OF TROCHER

where none of the patients developed infection on treatment of angle fracture.⁴ In the study by Guimond et al(2005)⁵ and Marshall(2013)¹⁹ et al infection rate was low that is 5.4% and 4% respectively when non comminuted mandibular angle fractures was fixed with a curved 2.0-mm multidimensional strut plate via transbuccal percutaneous approach in 37 patients and 90 patients respectively. Absence of infection might be attributed to the fact that minimal dissection required for the placement of hardware which is in accordance with study done by Peter bui et al (2009)². The percuateous transbuccal approach using a stab incision was successful not only for the ease of approach to fractured site, but also gives minimal scar. According to Evan Moore et al (2013) 8-hole strut plate has a lower infection rate as compared to

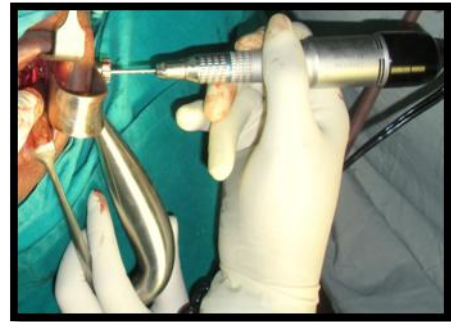

FIGURE V: TROCAR PLACED

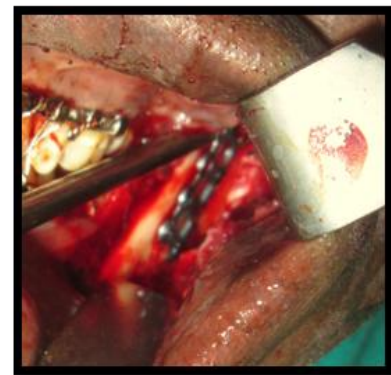


FIGURE VI: FIXATION OF FRACTURE

Champy miniplate. In this study the strut plate lies completely on the lateral aspect of the mandible and is relatively better protected than the champy plate in terms of exposure and is covered with vascular soft tissue, which may be one of the reasons for lower extrusion and infection rates.²⁰

Swelling: was assessed pre operatively, 3rd day, 1st week, 1st and 3rd month postoperatively. All patients reported swelling preoperatively, 8 patients (80%) post operatively on 3rd day, 2 patients (20%) post operatively at 1st week and none of them at 1st and 3rd month which is in accordance with study by Gandi et al(2012), who reported swelling present in all patients by 3rd day. In 3rd week swelling was present in only 20% cases, but this was non-significant. At 6th week follow up, the swelling was present in 10% patients only. No swelling was present at 3rd and 6th

POST OPERATIVE RADIOGRAPH

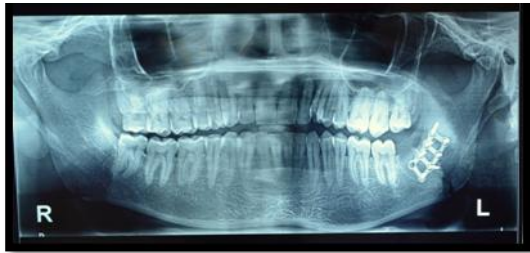
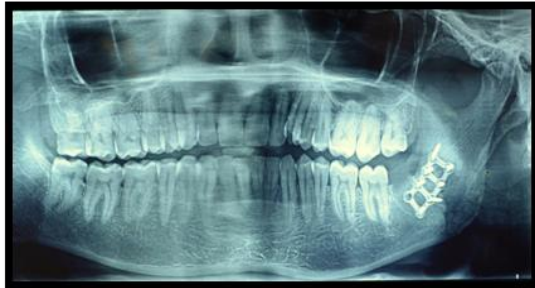
FIGURE VII : IMMEDIATE POST OPERATIVE RADIOGRAPH

FIGURE VIII: 1st MONTH POST OPERATIVE RADIOGRAPH

month follow -ups.¹⁹ Postoperative swelling can be attributed to blunt dissection of the masseter muscle in transbuccal approach.

Wound Dehiscence: was not found in any case which is in accordance to the study by Gokkulakrishnan S et al (2012)⁹ , Jain M et al (2012) . These studies prove wound dehiscence is usually less or nil while using 3-D plating system.

Stability: Guimond et al (2005)⁵ and Winttenberg et al (1997)⁶ explained the biomechanics of strut plate as it allows for almost no movement at the superior and inferior borders with manual torsional and bending forces, as opposed to a single linear plate is applied to the superior border area. When only 1 linear plate is placed at the superior border, torsional and bending forces usually cause movement along the axis of the plate with buccal-lingual splaying and gap formation

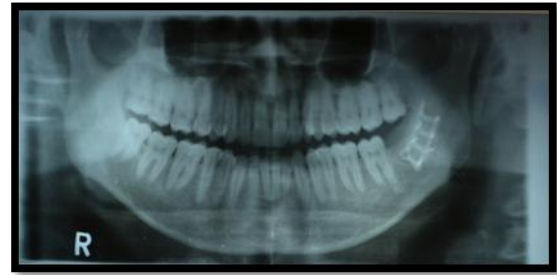

FIGURE IX : 3rd MONTH POST OPERATIVE RADIOGRAPH

FIGURE X: 3D STRUT PLATE WITH MONOCORTICAL SCREWS

at the inferior border, respectively. Because the screws are placed in a box configuration on both sides of the fracture rather than on a single line, broad platforms are created that may increase the resistance to torsional forces along the axis of the plate. As the design of strut plate is such that 2 linear plates are connected by reinforcing vertical struts, these plates may thus provide greater resistance against gap opening at the inferior border with biting forces that explains the stability achieved in this study. According to Alkan(2007) , the 3D strut plate technique had more favourable biomechanics than the Champy technique.

He demonstrated that 3D strut plates had greater resistance to compression load than the Champy technique.³ The stability of fracture fragments post operatively was assessed as described by Sehgal S et al (2014).¹⁵

Anatomical reduction: was assessed intra operatively based on clinical and radiographic examination. In this study 90% anatomical reduction were achieved. Immediate post operative radiograph showed anatomic reduction and alignment of the fractured segments in 9 patients (90%).Anatomic reduction after one month was evident without any signs of step defect or gap formation at the two fractured ends. At the end of 3rd month, the anatomic reduction achieved was still evident. Guimond et al(2005) reported a satisfactory reduction and occlusion in all cases.⁵ Krishna S et al(2008)¹⁰ reported good anatomic reduction(75%) post operatively. Edward Ellis III et al(1994)⁷ showed excellent reduction in all cases except one in postoperative radiographs taken within the first 2 days. S. Laverick et al (2012) reported most of fracture reduced through transbuccal approach.¹³ Goyal M et al(2011) reported no gap & displacement on postoperative radiograph.¹⁴

Clinically, occlusal discrepancy was assessed at various time intervals such as intra operatively, immediate, 1st week , 3rd week , 1st and 3rd month post operatively. No occlusal discrepancies were noted at any of the time interval in this study. Which is comparable to Gokkulakrishnan S et al(2012)⁹ , Bui et al(2009)² and Jain et al(2012)¹⁷ Tej raj P kale¹¹.The 3-D plating system achieves good and stable occlusion which is evident in this study.

Malunion and non union: were assessed by radiographic examination postoperatively 1st month and 3rd month. Non union or malunion was not reported in any patient in this study which is comparable to J. zix et al(2007)⁴ , Vineeth K. et al (2013)¹⁸.

Hardware failure: was assessed at 1st month & 3rd month post operatively by radiographic examination.

None of them had failure of hardware in this study which is comparable to Gokkulakrishnan et al (2012)⁹, Bui et al(2009)² and Jain et al(2012)¹⁷ Vineeth K. et al (2013)¹⁸. This may be attributed to use of intraoral and transbuccal approach which requires less bending of the plates and placement of plate in the neutral zone as in the study of Sudesh et al (2011)¹²

IMF Placement: The stability achieved by the 3D strut plate when applied at the angle region was stable enough where the requirement of Inter maxillary fixation was not required which is comparable to the studies done by Farmand Mustafa et al(1995) Manoj Jain et al (2012)¹⁷ et al .

The curved 3D strut plating system was found to be advantageous in mandibular angle fracture. It needs less surgical exposure, reduces the operation time with more stability. This study suggests that the use of curved 3D strut plate for mandibular angle fracture had more advantages & less limitations.

CONCLUSION- Efficacy of curved 3D strut plate in patients with mandibular angle fracture was evaluated in this study. 10 healthy patients with mandibular angle fracture were included. All patients underwent surgery under GA following adequate reduction & achieving proper occlusion. Plates were fixed through a stab incision & transbuccal trocar. In 90% cases anatomical reduction was achieved. Preoperatively all patients had paresthesia, 80% patients complained of paresthesia on 3rd day, 40% at 1st week and none at 3rd week

Preoperatively swelling was noticed in all patients, post operatively on 3rd day swelling was seen in 80% patients, in 20% at 1st week and none of them had swelling at end of 3rd week.

All fracture fragments were stable & were adequately fixed when checked intra-operatively. No immediate post-operative IMF was used in any of the patients. None of the cases reported wound dehiscence, infection, non union, mal union, malocclusion or hardware failure. The curved 3D strut plates were found to be advantageous in mandibular angle fracture. It needs less surgical exposure, reduces the operation time and has more stability. This study suggests that the use of curved 3D strut plate for mandibular angle fracture had more advantages & less limitations.

REFERENCES:

1. R. Mukerji, G. Mukerji and M. McGurk. Mandibular fractures: Historical Perspective. *British J Oral Maxillofac Surg* 2006; 44: 222-228.
2. Peter Bui, Nagi Demian, Patrick Beetar. Infection Rate in Mandibular Angle Fractures Treated With a 2.0-mm 8-Hole Curved Strut Plate. *J Oral Maxillofac Surg* 2009; 67: 804-808.
3. Alper Alkan, Nukhet celebi, Bora Ozden, Burcu Bas, Samet Inal, Kayseri et.al. Biomechanical comparison of different plating techniques in repair of mandibular angle fractures. *OOO*. 03-14, 2007.
4. Juergen Zix, Oliver Lieger, Tateyuki Lizuka . Use of Straight and Curved 3-Dimensional Titanium Miniplates for Fracture Fixation at the Mandibular Angle. *J Oral Maxillofac Surgery* 2007; 65:1758-1763.
5. Claude Guimond, James V. Johnson, Jose M. Marchena. Fixation of mandibular angle fractures with a 2.0 mm 3-dimensional curved angle strut plate. *J Oral Maxillofac Surg* 2005; 63: 209-214.
6. J.M.Wittenberg, D.P.Mukherjee, B.R.Smith, R.N. Kruse. Biomechanical evaluation of new fixation devices for mandibular angle fractures. *Int J Oral Maxillofac Surg* 1997; 26: 68-73.
7. Ellis E III and Walker Lee. Treatment of mandibular angle fractures using two non compression miniplates. *J Oral Maxillofac Surg* 1994; 52:1032-1036.
8. Farmand Mustafa. Three dimensional plate fixation of fractures and osteotomies. *Facial plastic surgery clinics of North America* 1995; 3(1): 39-56.
9. Sadhasivam Gokkulakrishnan, Sanjay Singh, Ashish Sharma, Ashish Kumar Shahi. An analysis of postoperative complications and efficacy of 3-D miniplates in fixation of mandibular fractures. *Dental Research Journal* 2012 : 9(2).
10. Sai Krishna D , Sujith Kumar Shetty , Vikas Kunwar Singh. A clinical study on transbuccal fixation of mandibular angle fractures. *Journal of Maxillofacial and Oral Surgery*. 7(3):2008.
11. Tej raj P Kale , Baliga SD, Nitin Ahuja, Kotrashetti SM. A comparative study between transbuccal and extra oral approaches in treatment of mandibular fractures. *J Maxillofac Oral Surg*.2010; 9 (1) 9-12
12. Sudesh kumar, Vikram Prabhakar, Kiran Rao, Ramandeep Brar. A comparative review of treatment of 80 mandibular angle fracture fixation with mini dlates using 3 different techniques. *Indian J Otolaryngol Head Neck Surg* 2011; 63(2):190-192
13. S. Laverick, P.Siddappa, H.Wong, P.Patel, D.C.Jones. intraoral external oblique ridge compared with transbuccal lateral cortical plate fixation for the

treatment of fractures of the mandibular angle: prospective randomized trial. *British Journal of Oral and Maxillofacial Surgery* .2012;50: 344-349.

14. Manoj goyal , Karan Marya, Sonia Chawla, Richa Pandey. Mandibular Osteosynthesis: a comparative evaluation of two different fixation systems using 2.0mm titanium mini plates and 3-D locking fixation plates. *J.Maxillofac.Oral Surg.*2011;10 (4):316-320.

15. Saumya Sehgal ,Lalitha Ramanujam,Kavitha Prasad, Ranganath Krishnappa. Three dimensional v/s standard titanium mini plate fixation in the management of mandibular fractures- a randomized clinical study. *Journal of Cranio-Maxillo-Facial surgery* 2014; 1-8.

16. Uma shanker, R.K.Singh, Satish Dhasmana, Somdipto Das, Sanjib K.Das. Use of 3D plate in displaced angle fracture of mandible. *Cranio Maxillofac Trauma Reconstruction*, 2013: 6; 25-30.

17. Manoj kumar Jain, K.Sankar, C.Ramesh, Ramakrishna Bhatta. Management of mandibular interforaminal fractures using 3dimensional locking and standard titanium mini plates- a comparative preliminary report of 10 cases. *Journal of Cranio-Maxillo-Facial Surgery.*2012; 40: 475-478.

18. Vineeth K, R.M.Lalitha, Kavitha Prasad, K.Ranganath, V.Shwetha, Jasmeet singh . A comparative evaluation between single non compression titanium mini plate and three dimensional titanium mini plate in treatment of mandibular angle fracture- a randomized prospective study. *Journal of Cranio-Maxillo-facial Surgery*. 2013; 41: 103-109.

19. Laksmi Gandhi, Vivekanand S.Kattimani. 3 dimensional bone plating system in the management of mandibular fractures- a clinical study. *Annals and essences of dentistry*, 2012; 4 (2).

20. Evan Moore , Sinehan Bayrak, Marcus Moody, J.Michael Key, Emre Vural. Hardware removal rates for mandibular angle fractures; comparing the 8 hole strut and champy plates. *Journal of CranioFacial Surgery* 2013; 4 (1).

21. Daniel Carmeron Braasch, A. Omar Abubaker . Mangement of mandibular angle fracture. *Oral Maxillofacial Surg Clin N Am*. 2013; 25: 591-600.