

Case Report

Ewing's Sarcoma of mandible

**Thriveni R¹, Saba Nasreen², DNSV Ramesh³, Praveen.A.H⁴, Amit Byatnal⁵, Sweta Kattimani⁶,
Wajiha Shereen⁷**

¹ Professor, Department of Oral medicine and Radiology, AMES, Dental College and Hospital, Raichur, Karnataka

^{2,6,7} Post graduate, Department of Oral medicine and Radiology, AMES, Dental College and Hospital, Raichur, Karnataka

³ Professor and Head of the Department Oral medicine and Radiology, AMES, Dental College and Hospital, Raichur Karnataka

⁴ Professor and Head of the Department Oral and Maxillofacial Surgery, AMES, Dental College and Hospital, Raichur, Karnataka

⁵ Reader, Department of Oral medicine and Radiology, AMES, Dental College and Hospital, Raichur, Karnataka

ARTICLE INFO



Keywords:

Ewing's sarcoma, Round cell tumor,
Sarcoma of jaws, Histogenesis, EWS
gene.

ABSTRACT

Ewing's sarcoma is a highly lethal neoplasm of bone and soft tissue and is the sixth most common malignant neoplasm which is composed of small round cells of uncertain histogenesis that usually occurs in childhood and is rare in the facial skeleton with mandible being most commonly affected bone.

Introduction

Ewing's sarcoma is the sixth most common malignant bone tumor that usually occurs in childhood¹. It was first described in 1921 by James Ewing who believed it to be a tumor of endothelial origin and described it under term diffused endothelial myeloma². Ewing's sarcoma is a distinctive primary malignant tumor of bone account for 4-15% of all primary bone tumors and 1% of all malignant tumors of children³. The long bones and pelvis are the preferential sites. Primary Ewing's sarcoma of the mandible is exceedingly rare. Less than 70 cases of Ewing's sarcoma reported in the literature⁴. We present a rare case of Ewing's sarcoma of mandible.

Case report

A 10 years old male patient reported to our department of oral medicine and radiology with complaint of mild pain and swelling measuring 4X4 cms in antero posterior and superior inferior dimension, which was small initially but gradually enlarged to present size, in the right body of the mandible with mobility of the involved teeth (Fig 1). On clinical examination the swelling was firm to hard in consistency, mild tenderness and without paraesthesia, soft and nonulcerated, with defined borders and extended from premolar region to the angle of the mandible and from occlusion surface to inferior border of the mandible, with obliterated vestibular sulcus, all the involved teeth are grade II to grade III mobile. Submandibular and jugular lymph nodes were

* Corresponding author: **Dr. Saba Nasreen, Post graduate Student, Department of Oral Medicine & Radiology, AME'S Dental College and Hospital, Raichur, Karnataka, India. email: drsabanasreen@gmail.com, Mobile: 9901960447**

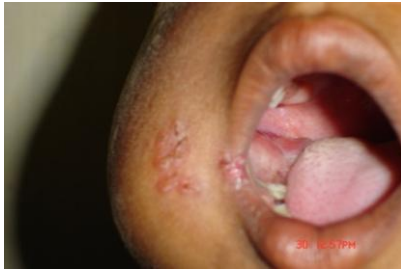

Fig. 1

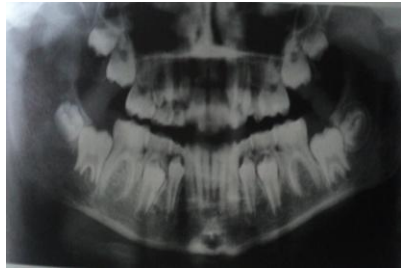


Fig. 2

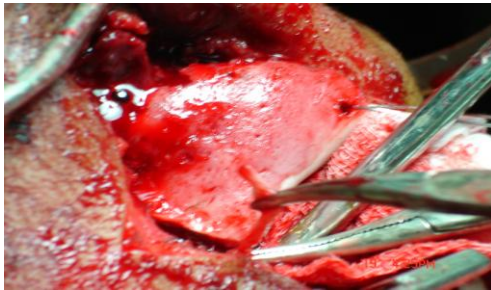


Fig. 3

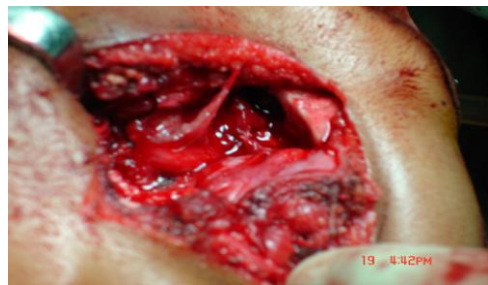

Fig. 4

palpable which was nontender, mobile, soft and enlarged. Panoramic film showed lytic changes in the right body of the mandible extending posteriorly (Fig 2). The incisional biopsy was performed at the alveolar crest region and sent for histopathological examination. On microscopic examination sections showed uniform, small round cells arranged in diffused pattern with scanty cytoplasm, the round cell

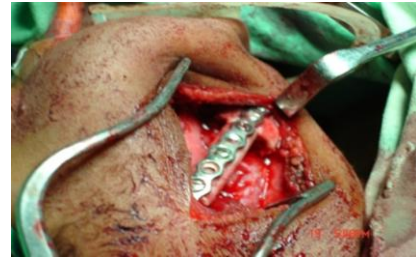

Fig. 5

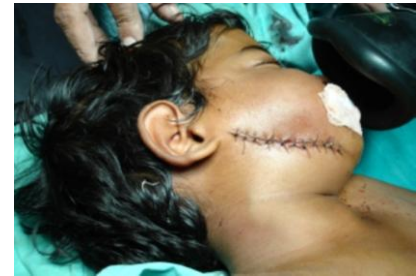

Fig. 6

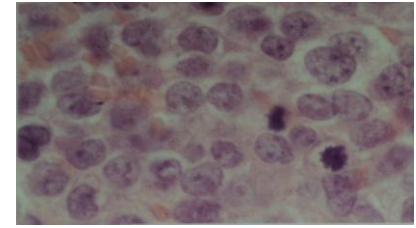


Fig. 7

showed ill-defined cellular border and well defined nuclear border, the report confirmed the diagnosis as Ewing's sarcoma. All the blood parameters were within the normal range except for mild rise in ESR. The surgical procedure was carried out under general anesthesia, The tumor site was approached extra orally through the submandibular incision, blunt dissection was carried out to expose the total tumor mass, segmental mandibulectomy was done leaving a clear margin of 1 cm from the tumor site and total tumor mass was resected (Fig 3,4). The resected site was grafted with free fibula and it was secured with the reconstruction plate and screws (Fig 5). The incision site was closed in multilayer with 3-0 vicryl (Fig 6).The resected specimen was sent for histopathological examination to reconfirm the preoperative diagnosis of Ewing's sarcoma (Fig 7).

The patient was subjected to radiotherapy and chemotherapy and he was followed for the period of 12 months with no recurrence at the site.

Discussion

Ewing's sarcoma is an unusual disease comprising about 4-6% of all primary bone tumors. Although it has been reported at any age majority of cases are seen with in first two decades of life. The usual site of occurrences is at diaphysis of long bones and less often in the ribs vertebrae. The head and neck region of Ewing's sarcoma is very unusual, accounting for 1 to 4% of cases⁵. Males are affected more commonly than females in the ratio of 3:2¹.

Generally the Ewing's sarcoma present with pain and local swelling, dilated veins, hyperthermia, anemia, raised ESR and leukocytosis. A history of previous trauma is present in many reported cases⁵, the typical radiographic appearance is a destruction of bone with large soft tissue mass and can cause periosteal reaction called onion skin appearance with displacement or destruction of teeth bud and widening of periodontal ligaments space⁶.

Radiologically onion skin periosteal reaction is characteristic in long bones, but rare in jaws because.

1. Mandible is typically a flat bone with less mass than long bones as a result rapid growth of tumor in head and neck region is more likely to violate the cortex and more lytic destruction takes place.
2. The cortices of bones in head and neck region are thinner, so expansion of bones in more in slower growing lesion than in longer bones⁷.

The radiographic differential diagnosis of ewings sarcoma of the mandible consists of osteogenic

sarcoma, lymphosarcoma, histiocytosis X, rbdomyosarcoma, and metastasis tumor⁶.

Facial sites of Ewing's sarcoma carry a better prognosis than long bones and pelvis, since facial sites are diagnosed early and are treated with local therapy and chemotherapy to decrease both the incidences of local disease recurrence and the development of pulmonary and skeletal Ewing's sarcoma of mandible⁸.

Generally the clinical symptoms are nonspecific like rapidly growing swelling of the affected area, pain, loosening of teeth, otitis media, parasthesia, etc. Systemic symptoms like fever, lymphadenopathy, weight loss, anemia, and albuminuria are observed frequently⁹.

Poor prognostic factors are patients below 10 years of age, pelvic lesion, presence of metastasis, presence of systemic symptoms, large tumors, high mitotic rate, filigree pattern in histological sections, poor response to chemotherapy. The recent report shows 2year disease free survival rate in 79% and 5 year survival rate in 60%¹⁰.

Conclusion:

Ewings sarcoma is highly metastatic and potential tumour so it demands early intervention. Evaluation of radiographs and biopsy followed by histopathology is necessary for early diagnosis and management, for good prognosis.

References

1. Eggi KD, Quiogue T, Moser RP, Ewing's sarcoma :RCNA 1993 Mar 31(2):325-37.
2. Luis Goraspe, Maria Angeles, Fernandez :Ewing's sarcoma of the mandible : Radiological features with emphasis on magnetic resonance appearance , oral surge oral med oral pathol endod, 2001;91:728-34
3. Da Fonseca MA, Abramas RB . Ewing's sarcoma of the mandible in young patient:A case report .pediatr dent 1992;14:402-04.
4. Wood RE, Nortje CJ, Hesselling P, Grotepass F. Ewing's sarcoma of the mandible. Oral surge Oral med Oral pathol 1990;69:120-6.
5. Fonseca AS, Mezzalirra R, Crespo AN jr, Paschoal jr . Ewing's sarcoma of the head &neck: sao pa Nov; 118(6):198-200.
6. Yalçın S, Turoglu T, Özdamar S, et al. Ewing's tumor of the mandible. Oral surge Oral med Oral pathol 1993;76:362-
7. Siegal et al. Primary Ewing's sarcoma involving the bones of the head &neck, cancer. 1987;60:2829-40.
8. JP Singh, L Garg, R Shrimail, V Gupta . Radiological appearance of Ewing's sarcoma of the mandible. Indian J Radiol Imagin 2003;13(1):23-25.
9. Brazo-Silva MT, Frenandes AV, Faria PR, Cardoso SV, Loyola AM ,Ewing's Sarcoma of the mandible in a young child. Braz Dent J 2010;21:74-9.
10. P Sharada, HC Girish ,HS Umadevi, NS Priya. Ewing's sarcoma of the mandible. J Oral Maxillofac Pathol 2006;10:31-5.