

## Case Report

# Familial Amelogenesis Imperfecta With Growth Hormone Deficiency And Skin Lesions- Case Report Of Unique Melange Of Disorders

Shalini Sharma<sup>1</sup>, S.Sudeep<sup>2</sup>, Antarmayee Panigrahi<sup>3</sup>

<sup>1</sup>Professor, Dept of Pedodontia and Preventive Dentistry, Ahmedabad Dental College & Hospital

<sup>2</sup> Professor, <sup>3</sup>Assistant Professor, Dept of Pedodontia and Preventive Dentistry, Institute of Dental Sciences & Hospital, SOA University, Odisha, India

## ARTICLE INFO



### Keywords:

Stunted Growth, Squamous Papilloma,  
Orphan Type Of Amelogenesis  
Imperfect

## ABSTRACT

Amelogenesis Imperfecta (AI) is a hereditary disorder expressing a group of conditions causing developmental alterations in structure of enamel, affecting aesthetics and function of enamel of one or all teeth in varying degree. It can either occur as isolated trait or with abnormalities in syndromes. Being genomic in nature, it can occur either as autosomal dominant or recessive, X-linked dominant and recessive modes of inheritance. Hypoplastic enamel has been commonly associated with growth hormone deficiency and vice versa as well. However, available literature lacks reported case of AI with growth hormone deficiency. This case report presents a case of 12year old prepubertal girl with AI with growth hormone deficiency, squamous papilloma and skin lesions. This rare conglomeration of presentation makes it the first reported case of this kind and second reported case of AI with growth hormone deficiency. Following appropriate diagnosis and pedigree charting, full mouth rehabilitation was done with adhesive restorations and preformed crowns to restore the hard tissues and function. Patient was put on preventive protocol and regular follow up aiming as enhancing oral and general health as well as her quality of life.

## Introduction

UNICEF Amelogenesis Imperfecta (AI) represents term for clinical and genetic heterogenous group of conditions that affect the dental enamel, occasionally involving other dental, oral, and extra oral tissues. It affects the quality and quantity of both primary and permanent enamel.<sup>1</sup>

Reported inheritance patterns are autosomal dominant, autosomal recessive, and X-linked. Based on the population studied and diagnostic criteria, reported incidence varies from 1:700 to 1:16,000 with no racial and sexual predilection.<sup>3</sup>

Various genes have been reported to play critical role in enamel formation like AMBN, TUFT1, MMP20, AMELX, ENAM, KLK and FAM83H.<sup>1, 3-4</sup>

AI has been broadly classified based on phenotype 1) hypoplastic 2) hypocalcified 3) hypomaturation 4) hypomaturation-hypoplastic. However atleast 14 subtypes have been mentioned in literature when phenotype and mode of inheritance are considered.<sup>1, 3</sup> Dental anomalies analogous with AI include quantitative and qualitative enamel deficiency, poor dental aesthetics, decreased vertical dimensions, impacted teeth, congenitally missing teeth, dentin dysplasia, Hypercementosis, root formation, taurodontism and growth hormone deficiency.<sup>3</sup> Nonetheless, the obtainable literature reports of just one case presenting with growth hormone.<sup>4</sup> This case being the second reported case of this association. Numerous treatment modalities are described for rehabilitation in adults and children. One of the most

\* Corresponding author: Dr. Antarmayee Panigrahi, Assistant Professor Dept of Pedodontia and Preventive Dentistry Institute of Dental Sciences & hospital, SOA University Bhubaneswar – 751003, Odisha, India

demanding aspect in rehabilitation of AI is to maintain maximum amount of hard tissues and restoring vertical dimension along with maintaining optimum periodontal health. Other factors to be considered include patient's age, socioeconomic status, type and severity, and intra-oral condition. Based on the factors, treatment traditionally includes combination of extractions, adhesive restorations, preformed crowns, overdentures, and veneers.<sup>3</sup>

This is the first description of a 12-year old girl presenting with AI with a familial tendency. Simultaneous presentation of squamous papillomatous lesions and skin lesions with diagnosed growth hormone deficiency makes this a unique melange of disorders.

This case report presents a unique coalition of disorders along with its diagnosis, pedigree charting, esthetic and functional rehabilitation and follow-up elevating the quality of life of the patient.

### **CASE REPORT**

A 12 year pre-pubertal girl was referred to our clinic for generalised yellowish discoloration of teeth. Past medical history revealed that she was undergoing treatment for growth hormone deficiency since past 7 years. She also suffered from squamous papillomatous lesion and under treatment since 2 years. Her younger (male) sibling and maternal uncle presented with similar presentation suggestive of familial pattern.

Stunted growth, papillomatous skin lesions and notched blackish malformed nails became evident on general examination. Skin lesions were seen at varying stages which can be attributed to the dermatological treatment. (Fig 1). Intraorally solitary papillomatous mass was evident on the posterior part of dorsum of tongue. Hard tissue examination revealed yellowish

discoloration of primary and permanent teeth. Marked vertical grooves and ridges on enamel surface with chipped of enamel were inescapable. She exhibited retained deciduous teeth (63&75) along with mild anterior crowding. Considerable loss of enamel associated with increased sensitivity was evident for 46. (Fig 2)

Orthopantomogram revealed generalised hypoplasia of primary and permanent dentition as evident by considerably reduced radioopacity as seen in normal enamel 41 and 47 were congenitally missing. (Fig 3)

Correlating clinical presentation, radiographic examination along with pedigree analysis it was unearthed to be a unique triad of hypoplastic AI along with growth hormone deficiency and squamous papilloma lesion and established to be the first reported case. (Fig 4)

Parents were unwilling for the extraction of retained teeth hence only direct composite laminates were done for the esthetic rehabilitation of 12,11,21 and 22 . Stainless steel crown was placed for 46 to prevent further degradation and aid in mastication. (Fig 5) Patient reported asymptomatic after 8month follow up.

### **DISCUSSION**

Amelogenesis imperfect is hereditary disorder expressed as defect in quality and quantity of both primary and permanent tooth enamel.<sup>2</sup>

According to Witkop classification as modified by Nuiser 2004, it can be classified based on phenotypic appearance into hypoplastic, hypomaturation and hypocalcified each with distinguished feature.<sup>5</sup>In the present case presence of discoloration, vertical grooves on enamel surfaces and notching of incisal edges along with discernible difference in radioopacities were found to be harmonious with hypoplastic AI.<sup>5</sup>

**FIGURE 1: EXTRAORAL APPEARANCE OF PATIENT**

(Stunted growth, mutilated nails and skin lesion in varying stages presenting as patches and scars)

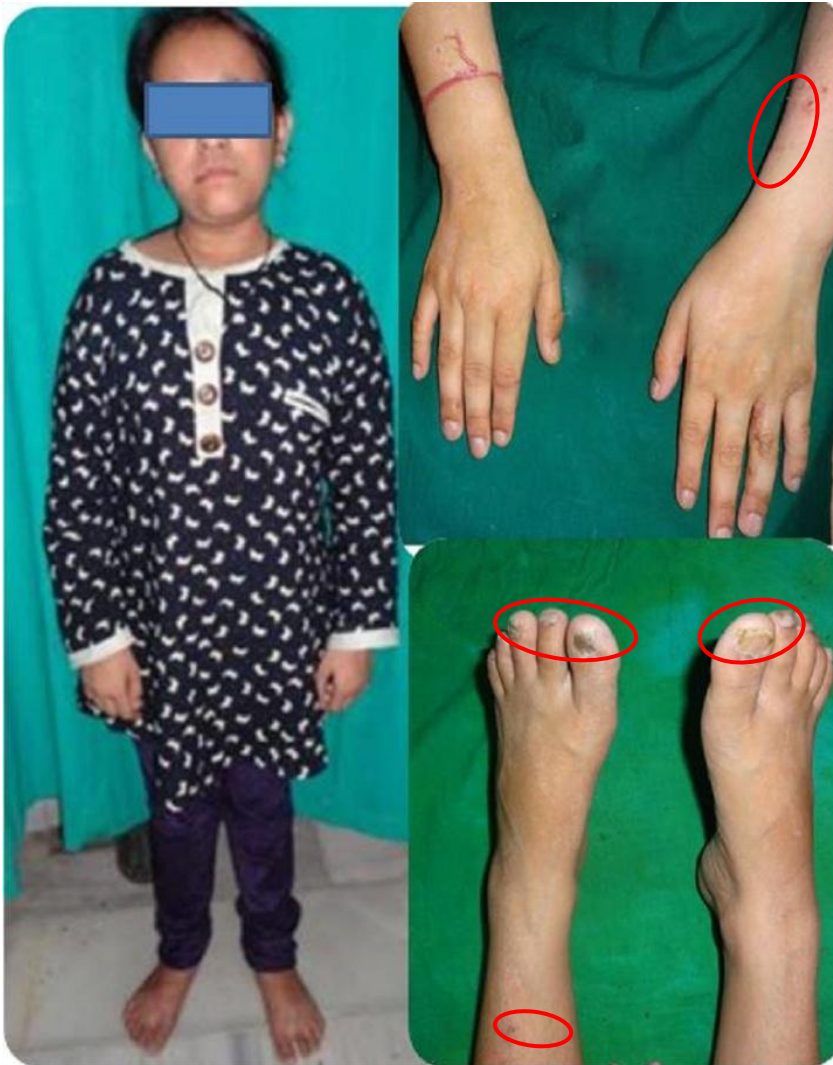

FIGURE 2:

INTRAORAL VIEW SHOWING DISCOLOURED GENERALISED ENAMEL HYPOPLASIA IN MAXILLA & MANDIBLE AND SQUAMOUS PAPILLOMA ON DORSUM OF TONGUE

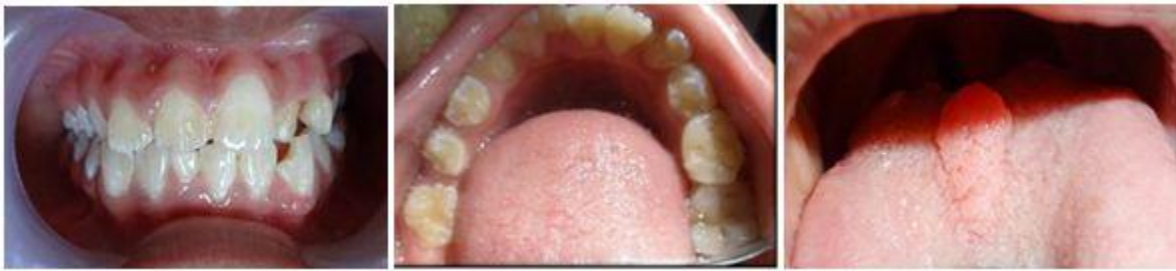

FIGURE 3: ORTHOPANTOGRAM

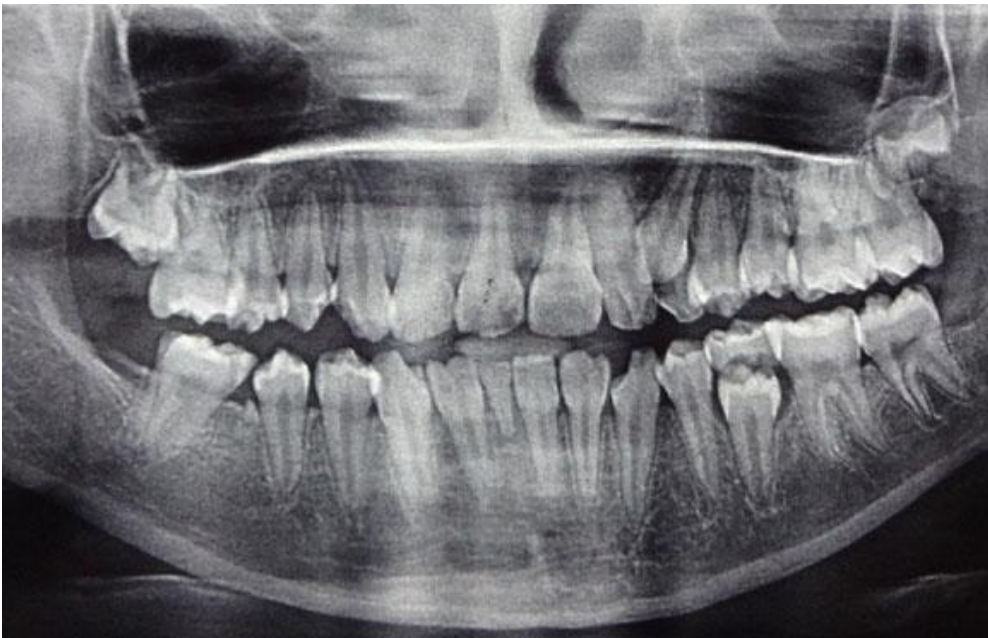

FIGURE 4: PEDIGREE ANALYSIS

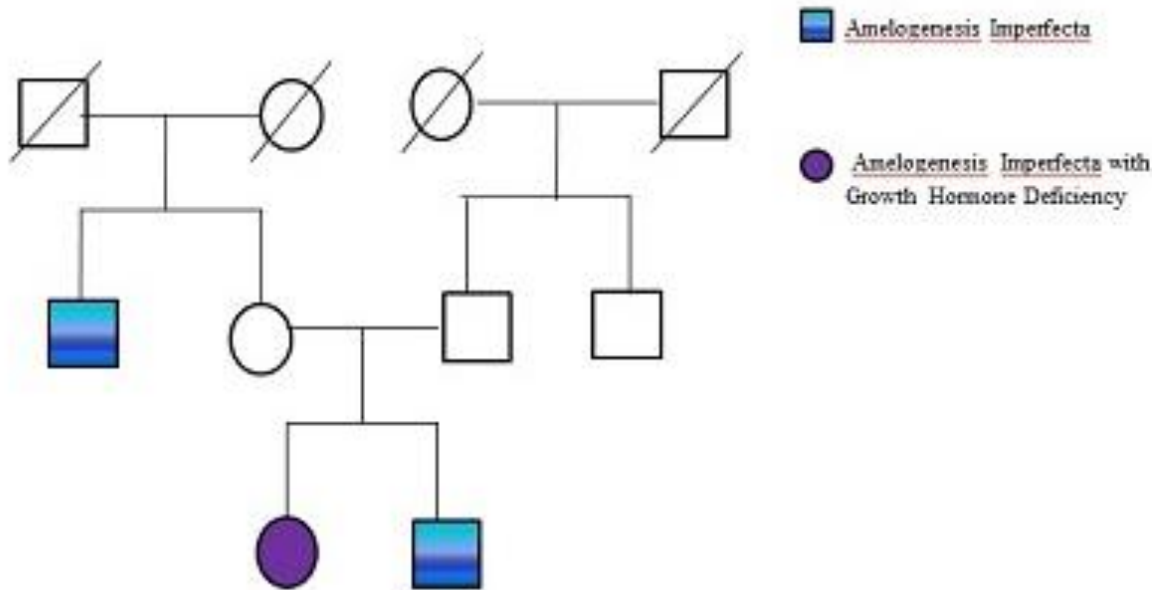
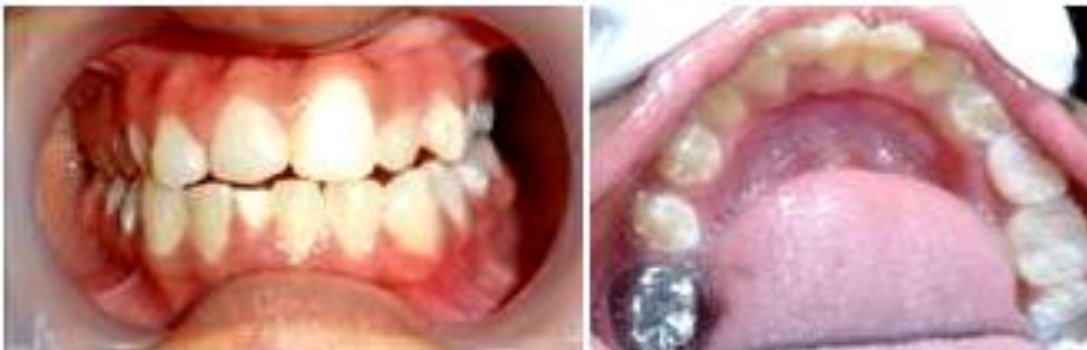

FIGURE 5: INTRAORAL POSTOPERATIVE VIEW



Fluorosis, other systemic diseases, local toxic agents, disorders of renal disorders were ruled out but our patient was known case of growth hormone deficiency since age of 2yrs. GH deficiency in childhood is mostly idiopathic and have varying expositions including growth failure, altered facial appearance,

delayed bone age, hypoplastic teeth, delayed eruption and retained teeth.<sup>5,6</sup>

Available literature reports of just one case presenting AI with growth hormone deficiency.<sup>7</sup>

In our case, patient presented AI with growth hormone deficiency with a familial tendency. Intraoral

squamous papillomatous lesion as well as dermatological lesion made this a unique conjunction.

Familial presentation further confirmed its genomic origin. So this rare co-nexus affecting mainly tissues of ectodermal origin needed further analysis genetically, which remained as a limitation of this case.

Clinical management was aimed to address the esthetic appearance of affected teeth, reduce dentinal sensitivity, and conserve the disintegrating tooth structure and intensification of masticatory function.<sup>3</sup>

In the present case, patient being at adolescent age direct composite laminates were done in the anterior tooth region ( 12,11,21 &22).Stainless steel crown was placed on disintegrating and mutilated 46. Patient received oral hygiene instructions and preventive appointments were scheduled at regular interval. Patient's esthetic and functional conjecture were satisfied. In the 8-month follow up patient was asymptomatic and considerable improvement in oral hygiene and overall health was noticed.

## CONCLUSION

Amelogenesis imperfect seldom occurs alone so thorough checkup must be performed to rule out any other underlying or associated medical condition so that early diagnosis and timely management can aid in improvising the overall health. This case not only is addition to the available literature but also emphasize on the need for establishment of detailed diagnostic protocol including genetic analysis and management guidelines for such cases.

## REFERENCES

1. Crawford PJM, Aldred M, Bloch-Zupan A; Amelogenesis imperfect. Orphanet Journal of Rare Diseases 2007, 2:17.
2. Canger EM, Celenk P, Yenisey M, Odyakmaz SZ; Amelogenesis Imperfecta, Hypoplastic Type Associated with Some Dental Abnormalities: Braz Dent J 2010 ;21(2):170-174
3. Dilsah Cogulu, Sema Becerik, Gülnur Emingil, P. Suzanne Hart, - Oral Rehabilitation of a Patient with Amelogenesis Imperfecta. Pediatr Dent. 2009; 31(7): 523–527.
4. Fernanda Veronese Oliveira et al- Amelogenesis imperfect and screening of mutation in amelogenin gene. Case reports in dentistry 2014;1-5
5. Neville BW, Douglass DD, Allen CM, Bouquot JE. Abnormalities of teeth. In: Oral and Maxillofacial Pathology. Elsevier. 2004. 89-94.
6. Rappold GA, Fukami M, Niesler B - "Deletions of the homeobox gene SHOX (short stature homeobox) are an important cause of growth failure in children with short stature". J. Clin. Endocrinol. Metab. 2002; 87 (3): 1402–6
7. Dundar B, Ercal D, Bober E, Berk T, Buyukgebiz : Amelogenesis Imperfecta with Growth Hormone Deficiency in a 12 year old boy. J. Ped Endocrinol Metab. 2002; 15: 659-662.