

Case Report**Leukemic Gingival Enlargement - A Role Of Periodontist In Early Diagnosis And Prompt Referral: A Case Report**Jampani Narendra Dev¹, Songa Vajra Madhuri², Lahari Buggapati³, Theruru Kotaiah⁴, Mohd Aijaz Ahmed⁵¹Professor & HOD, ²Associate Professor, ³Assistant Professor, ⁵Post Graduate Student, Department of Periodontics, Government Dental College and Hospital, Vijayawada⁴Professor & HOD, Department of Pedodontics, Government Dental College and Hospital, Vijayawada.

ARTICLE INFO



Keywords:

Acute myeloid leukemia, gingival hyperplasia, oral manifestations

ABSTRACT

Acute Myeloblastic Leukemia (AML) is a malignant disease of bone marrow, usually presenting gingival overgrowth as its first clinical manifestation. Even though many cases of gingival enlargement associated with AML are reported in the literature, there are very few cases diagnosed by dental professionals based on oral manifestations. Here is a case report of a 35-year-old male patient who reported to our department with a chief complaint of generalized gingival overgrowth and inability to chew. Since the clinical findings did not bear resemblance to any inflammatory condition, and the patient was not under any medication, blood sample was sent for routine blood investigations which rendered to diagnose it as acute myeloid leukemia. Treatment by chemotherapeutic induction regimen for a period of two months along with meticulous oral hygiene maintenance resulted in remission of the disease and complete regression of the gingival hyperplasia. The purpose of this article is to bring awareness on early oral signs and symptoms of systemic conditions and the role of periodontist who can provide an opportunity for timely diagnosis, early referral and prompt treatment.

Introduction

Leukemia is a malignant neoplasm that results from proliferation of a group of abnormal hematopoietic stem cells with impaired differentiation, regulation and apoptosis.¹ It is classified as myeloid or lymphoid forms based on the involvement of primary haematopoietic stem cells and acute or chronic forms based on its clinical behaviour. French-American British (FAB) classification further divide Acute Myeloid Leukemias (AML) in to eight subtypes (M0 – M7) according to the nature of cell from which the leukemia developed and its extent of maturity.²

Etiology of leukemia remains uncertain, increased risk is associated with exposure to large doses of ionizing radiation, exposure to certain chemicals like benzene, and exposure to specific viruses such as Epstein-Barr virus, human lymphotropic virus. In most of the leukemias chromosomal damage occur due to

cytogenetic abnormalities which inactivates tumor suppressor genes or activate oncogenes leading to increased proliferation of hematopoietic stem cells.¹

Leukemic cells penetrates in to various tissues throughout the body like spleen, lymph nodes, the central nervous system, skin and gingiva.³ AML generally associated with pancytopenia, weakness, fatigue, infections and other finding like ecchymosis, bleeding from nose and gingival bleeding.⁴

This case report highlights the role of periodontist in the early diagnosis of AML based on the intraoral findings along with blood investigation, which enabled to provide accurate treatment for the patient by referring to higher oncology center.

CASE REPORT

A 35 year old male patient reported to the Department of Periodontics, Government Dental College & Hospital, Vijayawada, with the chief complaint of gum swelling

* Corresponding author: Dr.Mohd Aijaz Ahmed, Department of Periodontics, Government Dental College and Hospital, Vijayawada– 520004, Andhra Pradesh. Phone: 9573732909 E-mail – draijazmds@gmail.com

since 6 months and difficulty in chewing since 1 month. Onset of gingival swelling was sudden and gradually increased to the present size which was associated with dull pain (Figure 1). Patient also gave a history of mild weight loss and loss of appetite since one month.

Patient gave no relevant drug and medical history but submandibular lymph nodes were palpable and tender bilaterally. On oral examination the gingiva appeared erythematous with areas of pigmentation, enlarged, lobulated, soft and edematous with loss of stippling. Enlarged gingiva cover the crowns of teeth in the posterior region and interfere with occlusion. Generalised pseudo pockets were present without any tooth mobility. Moderate deposits of plaque and calculus was noticed which is not in relation to the amount of gingival enlargement. Hard palate showed the presence of petechiae (Figure 2). There were no significant radiographic changes. Based on the above findings differential diagnosis of inflammatory gingival enlargement, enlargement associated with systemic disease and neoplastic enlargement were made.

Routine blood investigation report revealed a total Leucocyte count of 44,400/Cub.mm (Leucocytosis), Platelet count of 16000/ μ l (Thrombocytopenia) and Haemoglobin count of 9.6mg/dl (Anemia). Leukocyte differential count displayed 21% neutrophils, 72% lymphocytes, 02% monocytes and 05% eosinophils. The peripheral smear displayed myeloid precursor cells along with monocytes and blast cells. Based on the blood investigation report a final diagnosis of leukemic gingival enlargement was made. Routine supragingival scaling was done and patient referred to the regional oncology center for further management.

All the investigations were repeated again in the regional oncology center, including glucose tolerance and urine analysis. Bone marrow biopsy was done which revealed

hypercellular marrow with 80% blast cells which confirmed AML -FAB classification M2/M4. Treatment initiated with the induction regimen of chemotherapy consisting of intravenous administration of cytosine arabinoside (ARA-C,100mg/day x 7days) and daunomycin 20mg x 3 days along with whole blood transfusion.

The patient was regularly monitored to evaluate oral hygiene and measures like gentle brushing and mouth rinsing with 0.2% chlorhexidine were reinforced. After two months of initiation of treatment overall health of the patient was improved and gingival enlargement of leukemic infiltration was regressed completely (Figure 3). The patient was discharged with a WBC count of 4000 /cub.mm, platelet count of 2.0 Lakhs/ μ l, hemoglobin 10.2 gm/dl, differential count of neutrophils (60%) and lymphocytes (35%). Thereafter the patient was recalled after every 3 months for chemotherapy and follow up.

DISCUSSION

Oral lesions are the early manifestation for most of the leukemias.⁵ Most common oral manifestations of acute leukemias are gingival hyperplasia, mucosal ulceration, spontaneous gingival bleeding, petechiae, ecchymoses and infections of oral cavity.⁶ Gingival hyperplasia due to infiltration of leukemic cells is considered as diagnostic indicator for AML.⁷ It is characterized by gradual increase in size of interdental papilla along with marginal and attached gingiva, in severe cases crowns of the teeth were covered and interfere with the occlusion as seen in the present case.

Specifically gingival tissue was targeted by leukemic cells due to the properties of inherent extravascular infiltration and unique gingival microanatomy.⁸ Furthermore, Dreizen S et al. reported that increased mitotic rate and adequate leukemic cells are key

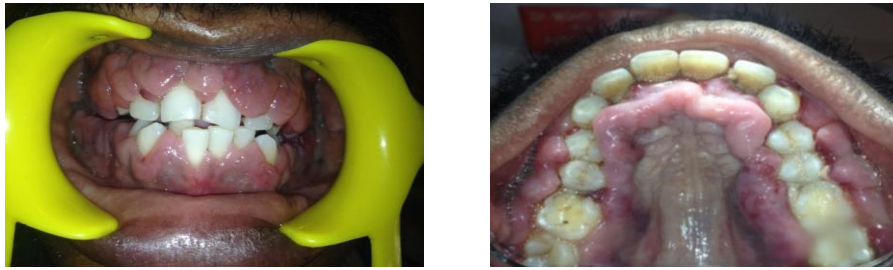

Fig. 1 : Initial intra operative view Fig. 2 : Intraoral view showing palatal petechia

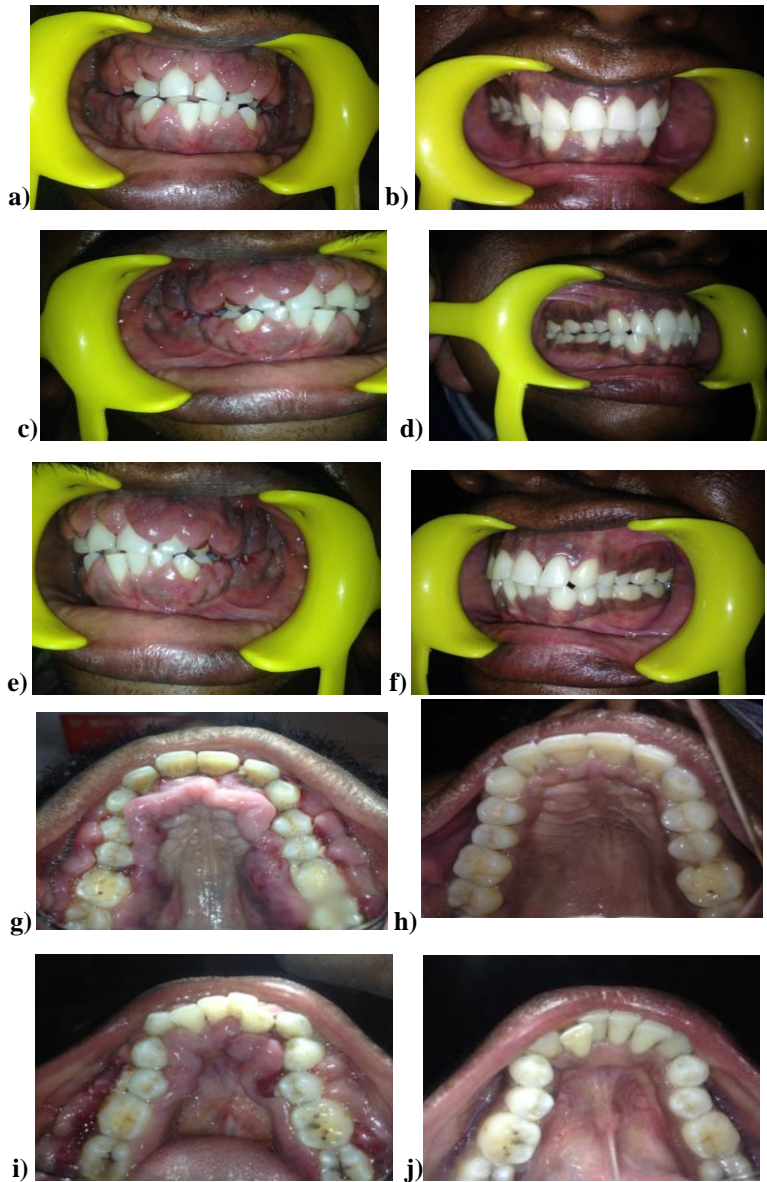


Fig. 3 - Intraoral initial and post treatment views after 2 months. a & b (labial view), c & d (right buccal view), e & f (left buccal view), g & h (palatal view), i & j (lingual view)

elements in starting the infiltration.⁹ These were the possible explanations given in the literature for the infiltration of leukemic cells in to the gingiva.

Cooper CL et al. reported that 66.7% of AML subtype M5, 18.5% of AML subtype M4 and 3.5% of AML subtype M1,M2 were commonly associated with gingival hyperplasia.¹⁰ Osgood EE observed 127 cases of monocytic leukemia, and stated that 53% of the patients were associated with gingival swelling.¹¹

Most of the time oral lesions in patients with acute leukaemia's seek dental consultation and were diagnosed during periodontal examination, so it is very important for dental professionals to have sound knowledge about the clinical manifestations of acute leukemias. Berkeisev S in his study stated that 25-33 % of patients with AML were diagnosed by dental professionals.¹²

In majority of the case reports of AML in the literature there will not be complete regression of gingival hyperplasia after chemotherapy but in the present case there is complete regression which makes it more interesting. This shows that, eliminating the etiology of gingival hyperplasia and maintaining ideal systemic health will result in good periodontal healing. As of now AML patients of age less than 60 years have response rates of 70% to 80% after induction chemotherapy.¹³ This case report emphasizes the importance of periodontist who initiates the diagnosis of AML during periodontal examination.

CONCLUSION

Leukemia often has oral manifestations as its first indication, which is what compels patients to seek dental care. Which alerts all the dental practitioner to be familiarized with all the diagnostic signs and complications associated with leukemia. Periodontist plays a fundamental role in the early diagnosis of

leukemia and can provide accurate treatment by referring the patients to higher medical centers.

REFERENCES

1. McKenna SJ. Leukemia. *Oral Surg Oral Med Oral Pathol Oral Radiol Endod* 2000; 89:137-139.
2. Santosh Patil, Nitin Kalla, D.N.S.V Ramesh, A.R. Kalla. Leukemic gingival enlargement: a report of two cases. *Archives of Orofacial Sciences* 2010; 5: 69-72.
3. Williams WJ, Beutler E, Erslev AJ, Litchman MA. *Hematology*; 4th ed. Mc Graw Hill 1990:243-4.
4. Demire S, Ozdemir H, Sencan M, Marakoglu I. Gingival hyperplasia as an early diagnostic oral manifestation in acute monocytic leukemia: a case report. *Eur J Dent* 2007;1:111-4.
5. Love A. Manifestations of leukemia encountered in otolaryngologic and stomatologic practice. *Arch Otolaryngol* 1963;23:173-7.
6. Soheylifar S, Vahedi M, Kadkhodazadeh M and Bidgoli MJ. A case of gingival enlargement in acute myeloid leukemia. *J Periodontal Implant Dent* 2009;1:48-50.
7. Hou GL, Tsai CC. Primary gingival enlargement as a diagnostic indicator in acute myelomonocytic leukemia: A case report. *J Periodontol* 1988;59:852-5.
8. Kinane D. Blood and lymphoreticular disorders. *Periodontal* 2000 1999;21: 84-93.

9. Dreizen S, McCredie KB, Keating MJ, Luna MA. Malignant gingival and skin “infiltrates” in adult leukemia. *Oral Surg* 1983;55:572–9.
10. Cooper CL, Loewen R, Shore T. Gingival hyperplasia complicating acute myelomonocytic leukemia. *J Can Dent Assoc* 2000;66:78-79.
11. Osgood EE . Monocytic leukemia: report of 6 cases and review of 127 cases. *Arch Intern Med* 1937;59:932-6.
12. Berkeisev S. Studies on the comparative morphology of monocytic leukemia, granulocytic leukemia and reticular cell sarcoma. *Cancer* 1957;10:606-16.
13. Amadori S, Suci S, Willemze R, Mandelli F, Selleslag D, Stauder R, Ho A, Denzlinger C, Leone G, Fabris P, Muus P, Vignetti M, Hagemeyer A, Beeldens F, Anak O, De Witte T. Sequential administration of gemtuzumab ozogamicin and conventional chemotherapy as first line therapy in elderly patients with acute myeloid leukemia: a phase II study (AML-15) of the EORTC and GIMEMA leukemia groups. *Haematologica* 2004;89:950-6.