



CASE REPORT

Neutral zone technique in complete denture –Case report

Pooja Asnani¹ , Chandu GS² ,Sunil Kumar Mishra³

¹Post Graduate Student, ²Professor and Head, Department of Prosthodontics, Rishiraj College Of Dental Sciences, Bhopal,

³Reader, Department Of Prosthodontics, Peoples's Dental Academy, Bhopal

ARTICLE INFO

Article history:

Received 23rd May 2015

Received in revised form 3rd June 2015

Accepted 6th June 2015

Keywords:

Stability, Support, Resorbed Ridges, Neutral Zone, Impression technique

ABSTRACT

The reduction in the denture foundation is one of the most commonly faced problems among long term denture wearers . Prosthetic Rehabilitation of a patient with severely resorbed ridge is the most challenging treatment for a prosthodontist. In order to have a favourable prognosis for the denture , impression technique selected should be based on the present state of the basal tissue support. This article presents the application of neutral zone concept being incorporated in to impression making in an effort to achieve successful complete denture.

INTRODUCTION

Introduction:

Loss of teeth leads to multi factorial changes occurring in the mouth like alveolar ridge resorption, expansion of the tongue, and laxity of muscles of face.¹ Optimum denture stability is difficult to achieve specially in the mandibular dentures due to less surface area coverage by the denture base and altered muscle activity.²

One of the important factor for the success of the complete denture treatment depends mainly upon the proper positioning of the teeth on the denture foundation.³ Fish and other researchers emphasized on the concept of neutral zone that is the zone of equilibrium in which the outward forces exerted by tongue counterbalance the inward forces of lips and cheeks in complete denture construction.^{4,5,6} Resorption of mandibular ridge occurs from the lingual plate allowing for more space for tongue movement leading to tongue enlargement over the years. On the contrary the cheek and lip muscles loose their tonicity with the advancing age. This results in a shift of the neutral zone more towards the buccal and labial sides. Accurate recording of this zone and arranging the teeth in this zone is very important in increasing the denture stability.⁷

Clinical Case Report:

A seventy year old male patient reported to the Department Of Prosthodontics, Rishiraj College Of Dental Sciences and R.C. Bhopal with the chief complaint of difficulty in chewing food due to loss of teeth

[Figure 1]. The patient was edentulous for past fifteen years and was wearing complete denture prosthesis since then. Patient lost his former set of dentures while pulling a bucket from the well, which is suggestive of ill fitting dentures.

Intra oral examination:

Clinical evaluation revealed resorbed maxillary ridge with flabby tissues in the canine to canine region [Figures 2], and flat (atrophic) mandibular ridge Atwood Order V [Figures 3] and an increased interarch space



Figure 1

* Corresponding author. Dr Pooja Asnani, Rishiraj College Of Dental Sciences & Research Centre, Bhopal, India
E-mail address: asnani.pooja@gmail.com

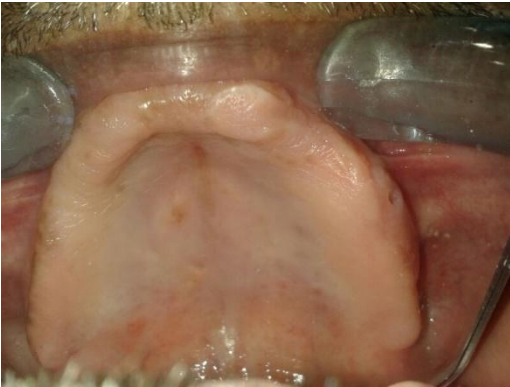

Figure 2

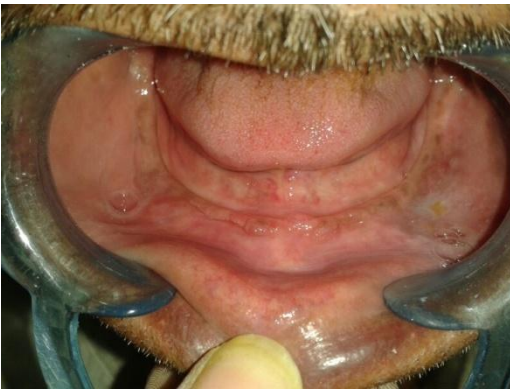
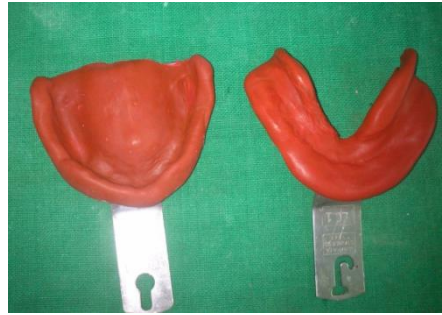
Figure 3



Figures 4



Figure 5

Maxillary custom tray was fabricated using a full spacer design additional spacer was placed in the anterior region so that the flabby tissues could be recorded in an uncompressed state (mucostatic impression). Border molding was done using low fusing impression compound and wash impression was made with zinc oxide eugenol impression paste [figure 6].

The mandibular final impression was made using custom tray, putty and light body consistency addition silicone material. (Double pour wash impression) [figure 7].

Clinical Procedure:

Impression making:

The primary impressions were made using impression compound and metal stock trays [Figure 4], and the cast poured using dental plaster [Figure 5].

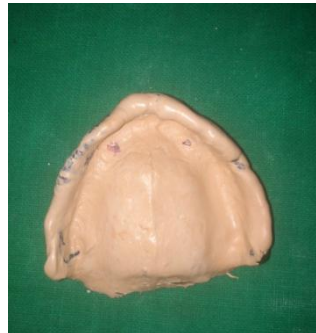

Figure 6

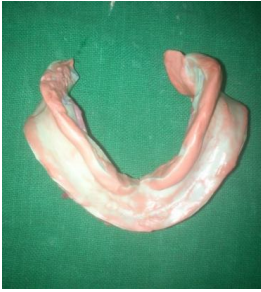

Figure 7.

Impressions were poured using type III gypsum product (dental stone) [figure 8 & 9]

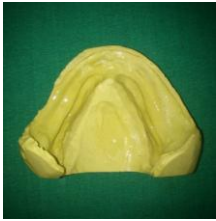


figure 8




figure 9

Mandibular neutral zone impression recorded :

Record base was made with self cure acrylic, and occlusion rims were prepared using modeling wax. After the registration of maxilla-mandibular relations, the casts were mounted on a three point articulator.

The neutral zone was recorded using mandibular compound occlusion rim. The mandibular wax occlusion rim was removed and retentive wire loops were attached to the record base in the premolar and molar area. Acrylic stents were made in the canine region for determination of the vertical height of the rim [figure 10]. Kneaded impression Compound was adapted to the denture base.

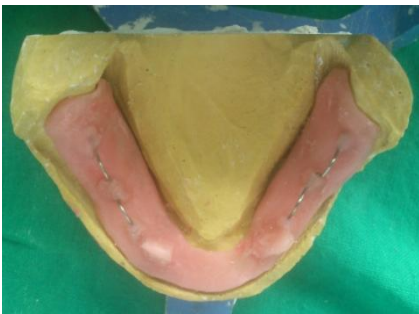

figure 10

Mandibular compound rim was softened in hot water and both Maxillary and mandibular record bases were placed in the patient's mouth. The patient was asked to carry out different functional movements like swallowing, sucking, whistling, smiling, licking the lips, and pronouncing vowels. Mandibular compound rim was taken out and Excess compound was trimmed away till the level of the acrylic stents and the material was re softened and replaced in the mouth asking the patient to repeat the functional movements. This procedure was repeated for about ten times so

that a narrow accurate zone could be recorded. The resultant molded occlusion rim is the neutral zone of the patients where the teeth are to be set [figure 11].

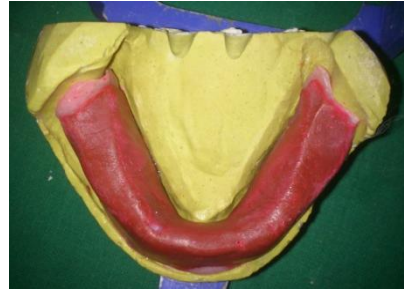

figure 11

The base of the cast was indexed by making notches. Addition silicone Putty index of this recorded zone was made. The compound rim, the retentive loops and acrylic stents were removed. The putty index was replaced on the cast and melted wax was flown to obtain a wax rim in the neutral zone area [figure 12].

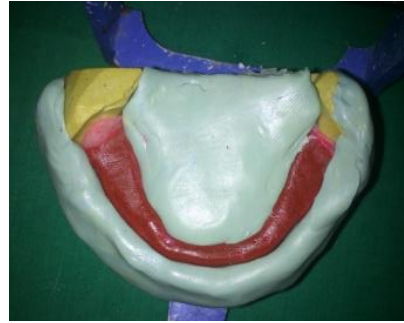

figure 12

Teeth arrangement:

First the mandibular teeth were arranged in the neutral zone area. And checked by replacing the putty index [figure 13]. The maxillary teeth were arranged according to the mandibular teeth.

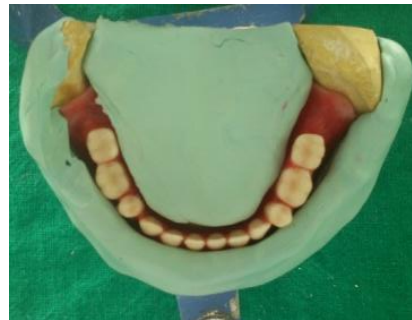

figure 13

Try in was done and the denture was processed, finished and inserted [figure 13 & 14].

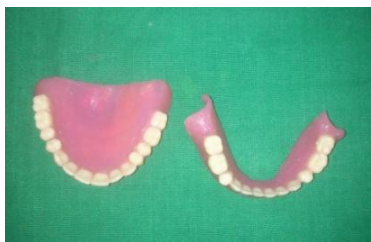

figure 13

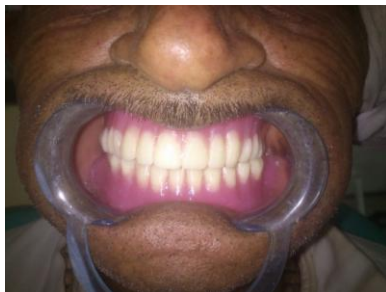

figure 14

Follow up:

The patient was followed for several months and was highly satisfied with his new denture.

**References:**

1. Fahmi FM. The position of the neutral zone in relation to the alveolar ridge. *J Prosthet Dent* 1992;67:805-09.
2. Watt DW, McGregor AR. Complete dentures: General considerations. In *Designing complete dentures*. 2nd ed. Bristol: WB Saunders; 1986: 1-2.)
3. Rahn OA, Heartwell LM. Tooth arrangement. In: Rahn OA, Heartwell LM. *Textbook of complete dentures*. 5th ed. India: Elsevier Science; 2002: 325-37.
4. Fish EW. An analysis of the stabilizing force in full denture construction. *Br Dent J* 1947; 83:137-42.
5. Lott F, Levin B. Flange technique: an anatomic and physiologic approach to increased retention, function, comfort and appearance of dentures. *J Prosthet Dent* 1966; 16:394-413.
6. Heath R. A study of the morphology of the denture space. *Dent Pract Dent Rec* 1970; 21:109-17.
7. Beresin VE, Schisser FJ. The neutral zone in complete and partial dentures. 2nd ed. St. Louis: CV Mosby; 1978: 15-30.
8. Gahan MJ, Wansley AD. The neutral zone impression revisited. *Br Dent J* 2005; 198(5): 269-72

How to cite this article: Asnani P , Chandu GS , Mishra SK
Neutral zone technique in complete denture –Case report..*J App. Dent. Med. Sci.* 2015; 1(1):15-18.

. Source of Support: Nil, Conflict of Interest: None declared.

Conclusion:

Recording of the Neutral zone is a simple effective non invasive and economic procedure which involves only one extra clinical step and improves the denture stability tremendously. This procedure should be performed for all the complete denture resorbed ridge patients either solely or in conjunction with other procedures to improve the denture stability.