



CASE REPORT

Anterior Maxillary Excess Correction With ASMO – A Case Report

Abhishek Mishra¹, Anisha Maria²

¹Post Graduate Student, Department of Oral and Maxillofacial Surgery, Rishiraj College Of Dental Sciences & Research Centre, Bhopal, India

²Professor and Head, Department Of Oral And Maxillofacial Surgery, Rishiraj College Of Dental Sciences & Research Centre, Bhopal, India

ARTICLE INFO

Article history:

Received 10th June 2015

Accepted 20th Aug 2015

Keywords:

Anterior segmental maxillary
Osteotomy, Cupar Technique, down
fracture

ABSTRACT

The goal of orthodontics is to maintain or improve a patient's facial balance. When orthognathic surgery is performed in conjunction with orthodontics, the capacity to alter facial appearance is increased. With proper diagnosis, treatment planning and follow-up care, the anterior maxilla can be surgically repositioned to correct the sagittal, vertical and transverse discrepancies of the jaw.

Introduction

With the advancement in all the spheres of medical profession, there has been most conspicuous and phenomenal progress in orthognathic surgery. The field of orthognathic surgery is not only fascinating but also challenging because it provides the patient an optimal aesthetic and functional result. However, best result can only be obtained, if the management of maxillo - mandibular deformities are meticulously assessed, planned and correctly executed from the very beginning¹. With the availability of numerous surgical procedures, it has become mandatory that there should be an organized pre-operative diagnosis and plan for

achieving the most acceptable and perfect post operative treatment results.

The first report of an anterior segmental maxillary osteotomy (ASMO) was published by *Cohn Stock* in 1921. Currently, mainly three variations of ASMO are used; the Wassmund, Wunderer, and down fracture methods. The usual indications for ASMO are excessive vertical or sagittal development of the maxillary alveolar process in patients where the relationships between the posterior teeth are acceptable. Anterior maxillary excess presents with excessive gummy smile with increased over jet and deep overbite. Surgical approach with ASMO has produced excellent treatment results. This clinical case typically exemplifies the effect of ASMO on improving the

* Corresponding author: Dr. Abhishek Mishra, Post Graduate Student, Department Of Oral And Maxillofacial Surgery, Rishiraj College Of Dental Sciences, Bhopal, India Email: anisha.maria99@gmail.com

skeletal, dental, soft tissue and over all aesthetics of the patient²

There are varieties of severe malocclusions that can be treated orthodontically but with a great deal of effort. Skeletal open bite is among the most challenging clinical situations that the orthodontists are facing orthodontists these days. Several treatment protocols have been proposed to correct anterior open bite malocclusions that can distinctly influence long term stability³. Conventional orthodontic treatment is marked by significant open-bite relapse that is greater in non extraction treatment. So the patients with severe skeletal anterior open bite discrepancies can be managed with the use of a combined orthodontic and surgical treatment that includes segmental osteotomies of the anterior part of the maxilla. Clinicians have stopped performing open bite closure via mandibular surgery with counterclockwise rotation of the mandible and intermaxillary wire fixation because of the instability associated with this technique. Surgical management of anterior open bite can be achieved with various surgical techniques but most commonly maxillary impaction either alone or in conjunction with mandibular Osteotomy is used to eliminate open bites. Proffit⁴ et al in considering a hierarchy of stability for orthognathic surgery procedures, proposed maxillary impaction as the most stable procedure and maintained that the type of fixation (rigid

internal or wire) in maxillary impactions did not influence stability. Bimaxillary procedures to correct anterior open bite appear to be less stable than maxillary procedures alone. Anterior segmental osteotomies are the procedures which can be accomplished intraorally without facial scar and do not require prolonged inter-maxillary fixation and there is no change in the posterior occlusion. These are not only stable but also versatile and can be undertaken for multiple deformities affecting the anterior portion of the jaw.

Case History

A 20 year old female patient came to the Department of oral maxillofacial surgery, Rishiraj college of Dental sciences Bhopal M.P., with a chief complaint of forwardly placed upper front teeth. Initial examination reveals excess visibility of gingiva at rest and during smiling. Incompetent lip with gap of 9 mm suggesting of vertical maxillary excess. She had dolichocephalic, convex profile and posterior divergent and a high lip line with 7 to 8 mm of gingival visibility during smiling. Class I molar and class I canine with overjet of 3 mm and overbite of 4 mm. Lower midline shifted to left side by 2mm with mild lower anterior crowding.

Treatment Plan

1. Impression making, Model surgery performance
2. Orthodontic procedure
3. Surgical procedure

4. Post orthodontic procedure

PARAMETER	PRE OPERATIVE	POST OPERATIVE
SKELETAL		
SNA	86°	82°
SNB	78°	80°
ANB	6°	2°
N PERP TO PT A	6mm	3mm
N PERP TO POG	-8mm	-3mm
GOGN TO SN	32°	33°
UAFH	51°	45°
LAFH	48°	54°
DENTAL		
UI TO NA	12mm	5mm
LLI TO NB	13mm	5mm
UI TO SN	127°	104°
LI TO MAND PLANE	114°	92°
INTERINCISAL ANGLE	90°	125°
SOFT TISSUE		
NASOLABIAL ANGLE	69°	89°
SLINE TO UPPER LIP	6mm	-1mm
SLINE TO LOWER LIP	3mm	0mm

1. Impression making and Model surgical performance

Model surgery⁵ has become an essential procedure for planning surgical outcomes of patients requiring a correction of a dentofacial deformity.

Basic Requirements

1. Making a impression
2. Making of model
3. Face bow transfer
4. Articulations
5. Fabrication of splints

2. Orthodontic procedure

After clinically examining the patient it was found that the overjet was not enough to surgically rotate the anterior maxillary segment clockwise by anterior maxillary Osteotomy and to push it posteriorly to reduce proclination of maxillary anterior teeth and to correct the open bite. Therefore both the lower first premolars were extracted and the anterior segment was retracted

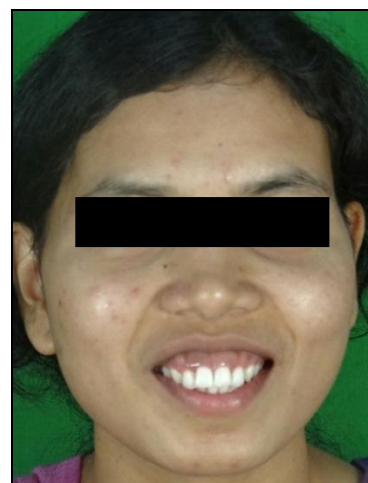

Fig 1: Facial Profile Pre Operative Anterior View

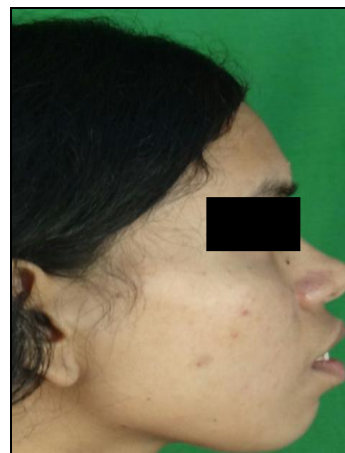

Fig 2: Facial Profile Pre Operative Lateral View

en mass with sliding mechanics to create over jet of 6mm. All the extraction spaces were closed in 8 months and the patient was ready for orthognathic surgery.

3. Surgical procedure

(Anterior maxillary Osteotomy – Cupar technique)⁶

The procedure was carried out under general anaesthesia with nasal

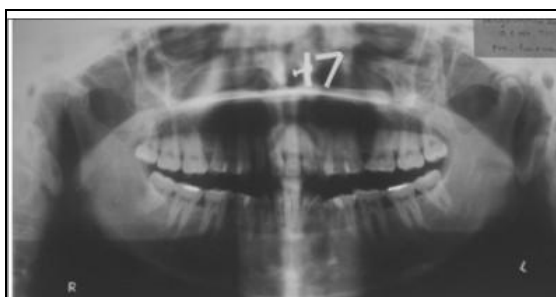


Fig 3: Pre Operative Orthopantomogram view

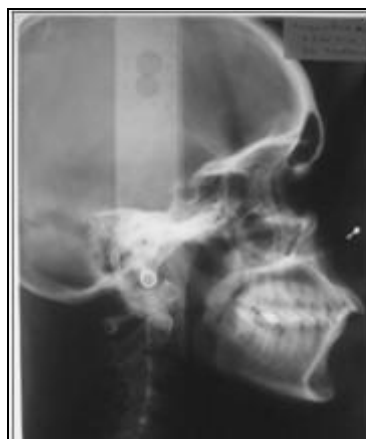

Fig 4: Pre Operative Lateral Cephalogram view

intubation, local infiltration with 2% lignocaine Hcl with adrenaline 1: 80000 as done in maxillary vestibule. Standard Cupar incision was given from

first premolar to premolar .The Mucoperiosteum was elevated through this incision to



Fig 5: Model Cast Mounted On Hanau Articulator

expose the pyriform aperture & anterior wall of the maxilla up to the canine fossa. Upper first premolars were extracted on both the sides. Palatal tunneling was done from the extraction socket converging at midline. Keeping the gingivoperiosteal flap intact & well retracted vertical maxillary osteotomy was carried out from the socket of extracted premolars to pyriform aperture bilaterally followed by the palatal Osteotomy. After completing the Osteotomy, anterior maxillary segment was down fractured and Superior and posterior repositioning was done. Additional bone was removed from anterior segment or the adjacent maxilla.

Suturing was done .No operative and postoperative complications were observed.

4. Post Surgical Orthodontics

Three months after surgical procedure it was found that approximately 1mm residual space was left distal to all canines, so post surgical orthodontics was performed for 3 months for residual space closure and minor leveling and alignment. Short class 2 elastics were given on both sides with class 1 elastics in the lower arch. The case was deboneded after 3 months of post surgical orthodontics.

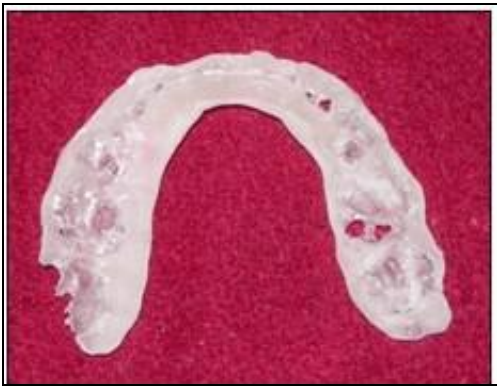

Fig 6: Fabricated Occlusal Splint

Discussion

A dramatic improvement in facial esthetics and occlusal function was realized with the completion of treatment. The lip competency, gingival exposure on smile and facial contour was significantly improved. The patient was very satisfied with the results of treatment. The excessive vertical dysplasia was dramatically reduced, and most of the cephalometric values were brought into the normal range. The anterior maxillary excess was significantly reduced, an

ideal over jet and overbite and the chin deficiency was well addressed.

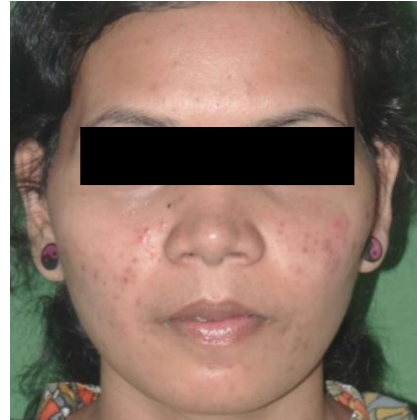

Fig 7: Facial Profile Anterior View Post Operatively

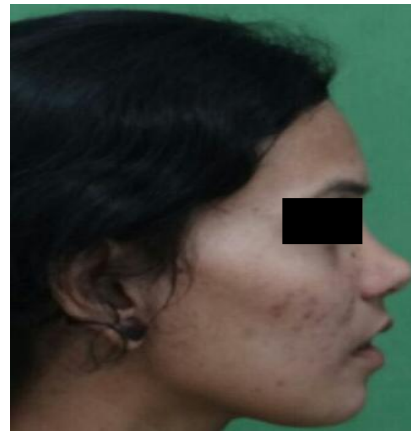

Fig 8: Facial Profile Lateral View Post Operatively

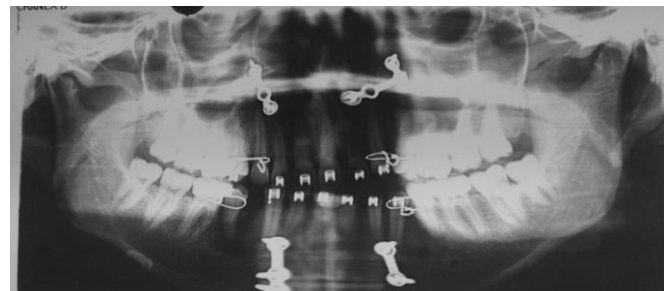

Fig 9: Post Operative Orthopantomogram view

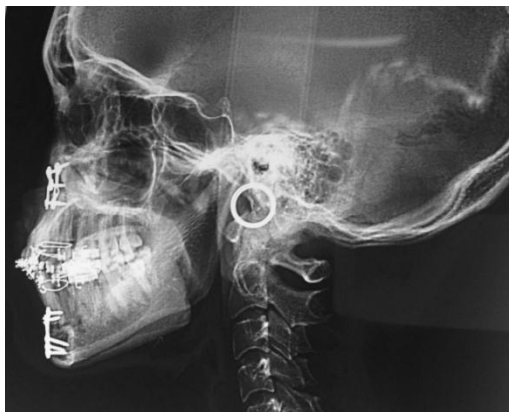

Fig 10: Post Operatively Lateral Cephalogram View

Conclusion

This case illustrates the importance of proper diagnosis and treatment planning. A team approach with the orthodontist, surgeon, and restorative dentist all having input before the initiation of treatment is the best way to achieve stable, functional, and esthetic results. Through this combined approach, the patient had a dramatic skeletal, dental, and occlusal improvement. As an added benefit, the patient has reported a better self-esteem and a greater degree of pleasure related to his appearance.

References

1. Lisen Espeland, Paul A. Dowling, Karim A. Mobarak, and Arild stenvik- Three year stability of open-bite correction by 1-piece maxillary osteotomy .Am J Orthod Dentofacial Orthop 2008;134:60-6.
2. Rosenquist B. Anterior segmental maxillary osteotomy:: A 24-month follow-up. International journal of oral and maxillofacial surgery. 1993;22(4):210-3.

3. Lew KK- A ten year follow up case report follow surgical correction of anterior open bite. Aust. Dental journal 1991,36; 109-112
4. Profitt.W.R.L.J, Bailey et al: A long term stability of surgical open bite correction by Le Fort 1 osteotomy. Angle orthodontics 2000; vol 36: 110-12
5. Reyneke JP. Essentials of Orthognathic surgery, China 2003, Quintessence publishing co.
6. Cupa IDie Chirurgische Behandlung der Form- und Stellung-Sveranderungen Des Oberkiefers, O&err. Z. Stomatol. 51: 565, 1954; Bull. SC. Cons. Acad. R..P.F. Yougosl.2: 60, 1955.

How to cite this article: Mishra A, Maria A. Anterior Maxillary Excess Correction With ASMO – A Case Report. JOADMS 2015;1(2):18-23.
 Source of Support: Nil, Conflict of Interest: None declared