

Case Report

Fabrication of Quinlivan Attachment Using Metal Press Button– A Case Report

Reji P Goplalan ¹, Vivek V Nair ², Joy P T ³, Prasanth Manohar ⁴

¹Senior Resident, ²Professor, ³Assistant Professor Department of Prosthodontics, Government Dental College, Thrissur, Kerala, India

⁴Consultant Prosthodontist and Implantologist, Kozhikode

ARTICLE INFO



Keywords:

Overdenture, metal press button, copings, tooth supported denture, custom attachments, orthodontic separators.

ABSTRACT

The use of last few remaining teeth in a ravaged dentition to improve the stability and retention of prosthesis is an age old concept. Retention is improved greatly by use of attachments, but many are deprived of overdenture treatment because of financial constraints. This article describes a novel method of fabricating a quinlivan overdenture attachment by use of a metal press button. This acts as the male component and orthodontic separators are used as the female component. This technique provides a reasonable amount of retention in a cost effective and simple way.

INTRODUCTION

Over the past few years number of edentulous patients among the general population has risen steeply. Even though rehabilitation of edentulous ridge with implant persists, it is an expensive treatment not afforded by many. Preventive prosthodontics including overdentures comes into play to meet the increasing demands of the edentulous patients under these circumstances. Over denture is a favored treatment modality for patients with few remaining teeth because it improves stability and retention of dentures which in turn increases the masticatory efficiency. The retained teeth are endodontically prepared and coronally modified to be used as abutments for an overdenture if resorption pattern suggests an unfavourable prognosis for complete denture. The objective is to

distribute stress between the retained abutments and denture-supporting soft tissues and to maintain the morphology of alveolar ridge.^[1,2] Attachments used in overdenture are often made by either connecting them to cast abutment copings or into the prepared post space of the abutment teeth.^[3] Usually complexity in design and high cost impede the use of prefabricated attachments, in spite of high precision, in numerous situations.

This clinical report describes a method in which the attachments are fabricated utilizing simple technique and cost effective item like metal press button.

CASE REPORT

A healthy 42 year old male patient with chief complaint of difficulty in chewing food. Clinical

* Corresponding author: Dr Reji P Goplalan, Senior Resident, Department of Prosthodontics, Government Dental College, Thrissur

examination revealed partially edentulous maxillary and mandibular arches with multiple missing teeth except 13, 23, 24, 33 and 43. Radiographic assessment revealed adequate bone support around the remaining dentition (Figure 1). After assessing the available interarch space through diagnostic mounting it was decided to fabricate tooth supported maxillary overdenture using copings in conventional manner. It was decided to use custom ball attachment obtained from metal press button in mandibular arch for additional retention. The proposed treatment plan was presented to the patient and consent obtained. Treatment plan was divided into three phases: Phase 1: Scaling and root planning Phase 2: Endodontic treatment of 13,23,24,33 and 43, Phase 3: Prosthodontic rehabilitation

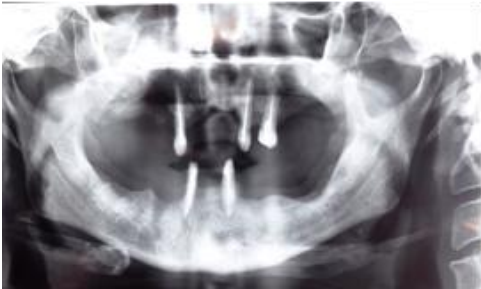


Fig 1. OPG



Fig 2. Metal press button

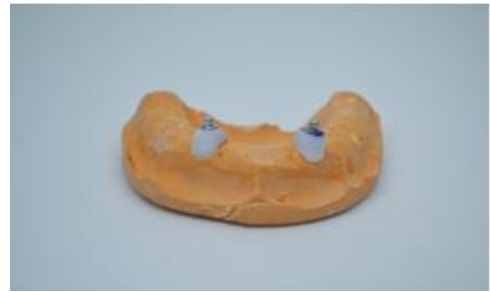

Fig 3. Wax pattern for mandibular copings



Fig 4. Mandibular copings

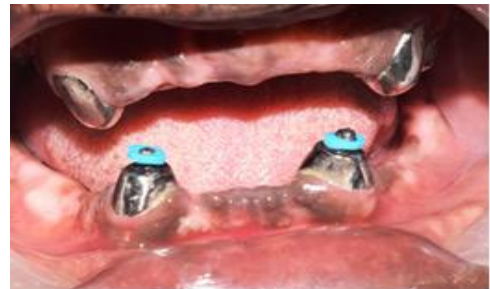

Fig 5. Cemented copings- intra oral view

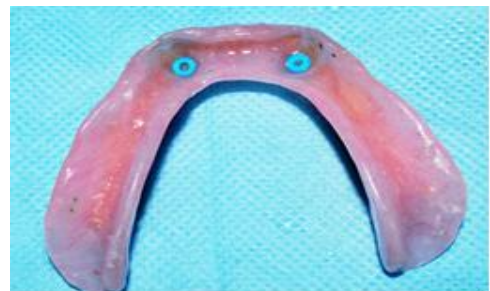

Fig 6. Mandibular denture with elastics picked up

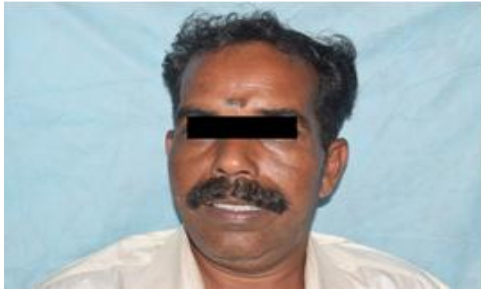

Fig 7. Post operative- frontal view

PROCEDURE

1. Following proper endodontic therapy the teeth were prepared in a dome-shaped contour with approximately 3–4 mm projecting just above the gingival .
2. Maxillary and mandibular impressions were made using irreversible hydrocolloid impression material (Chromatic Jeltrate, Dentsply, India) for the fabrication of copings and then poured in die stone (Type IV diestone, Ultrarock, Kalabhai Karson Pvt. Ltd., Mumbai, India).
3. The maxillary copings were cast using Co-Cr alloy.
4. After fabrication of wax pattern on the mandibular canines, the male component (male extension) of the metal press button (Geox Brand) (Figure 2) was kept at right angles to the mean foundation plane of the basal seat and parallel with the counterpart on the opposite side of the arch (Figure 3). This assembly was then cast in the conventional manner (Figure 4).
5. Orthodontic separators were tried over the custom ball attachment on mandibular canines (Figure 5).
6. Finished copings were luted to the abutment teeth using GIC (GC Fuji PLUS™ GCAmerica) luting cement.
7. Primary impression of the maxillary and mandibular arches were then made with alginate impression material (Chromatic Jeltrate, Dentsply, India) and special tray fabricated using self cure acrylic resin (DPI-RR; Dental Product of India, Wallace Street, Mumbai, India).
8. Border moulding was performed with low fusing compound (DPI Pinnacle Tracing Stick, DPI, Mumbai, India) and secondary impression was made with low viscosity rubber base material (Aquasil, Dentsply International Inc., USA).
9. After a satisfactory try-in, the waxed up denture was processed using heat cure acrylic.
10. Maxillary and mandibular complete dentures were fabricated with a recess created on the impression surface of the maxillary denture to accommodate the abutments.
11. Vent holes were prepared on the mandibular denture in the space maintained for attachments.
12. Orthodontic separators were placed over the custom ball attachment on mandibular canines.
13. The separators were picked up by adding autopolymerizing acrylic resin (Figure 6) in the space while maintaining maxillary and mandibular dentures in occlusion. The excess self-cure acrylic that came out of the vent holes was trimmed followed by polishing.
14. Dentures were delivered and the patient was given instructions for using and maintaining the denture. Periodic follow-up was carried out once in 6 months.

DISCUSSION

Healthy teeth with compromised periodontal status can be modified and retained under overdentures as a part of preventive prosthodontics.^[4]The main objective in using tooth-supported overdenture is to preserve the remaining supporting tissue and to restore missing structures in such a way as to provide maximum service for maximum amount of time. A major function of tooth supported overdenture treatment is to transfer some of the occlusal forces through the periodontal ligament to the bone and provide a reasonable amount of retention.^[5]Techniques used in the treatment of teeth to serve as abutment for overdenture ranges from simple tooth modification and reduction, tooth preparation with cast coping to cast coping utilizing a number of both prefabricated and custom made attachments.^[6]Though the prefabricated attachments are more precise, they are not preferred at times due to their high cost and need of precise location between various components, placement of additional forces on their dowel. In view of the exalted rate of root caries progression and neglected oral hygiene of most overdenture wearers, placement of protective copings on root abutments is considered mandatory.^[7]In the present situation, custom made ball attachments fabricated over cast copings using metal press button (male component) and orthodontic separators (female component) were used as simple and extremely cost effective alternative to the use of prefabricated attachments. Separators are small elastics which are commonly used during orthodontic treatment to create space between the teeth prior to placement of metal bands.^[8]These are first tried on the matrix part of metal press button to ensure the snug fit. They are easy to use since a diameter of required dimensions is available and there is no need

of cutting a central hole. Retention may decrease after a period of time due to wear of the elastic separator, in such situation it can be easily replaced by chair side technique.^[9]

CONCLUSION

The selection of attachment depends on inter arch space, bone support, personal preferences, maintenance problems, cost and patient motivation.^[10]The use of attachments at times can be cumbersome, expensive and time consuming. These factors keep both the patient and clinician reluctant to implement overdenture treatment modality. Use of metal press button is found to be a simple technique to fabricate overdenture attachments economically. Replacement of matrix part is also not a difficult affair as separators are readily available in different sizes. A 2 year follow up of the patient was found to be satisfactory.

CONFLICT OF INTEREST

None declared

REFERENCE

1. Zarb, Hobkirk, Eckert, Jacob (2012). Prosthodontic treatment for edentulous patients: complete dentures and implant—supported prostheses, 13th edn. Elsevier, St. Louis, pp 290–295.
2. Winkler S (1996). Essentials of complete denture prosthodontics, 2nd edn. Ishiyaku EuroAmerica, St. Louis, pp 384–401.
3. Preiskel HW. Overdentures made easy: a guide to implant and root supported prostheses. Quintessence Int. 1996;2:12–32.
4. Frantz WR. The use of natural teeth in overlay dentures. J Prosthet Dent. 1975;34:135–40.

5. Warren AB, Caputo AA. Load transfer to alveolar bone as influenced by abutment design for tooth-supported dentures. *JProsthet Dent.* 1975;33;137-148.
6. Henking JP (1982). Overdentures. *J Prosthet Dent* 10;217-25.
7. Dable RA, Gaikwad BS, Marathe SS, Badgujar MS, Dole VR (2013). A simplified technique for custom made overdenture semi-precision attachments. *Indian Journal of Dental Research.* 1;24:622.
8. Bansal S, Aras MA, Chitre V (2014). Tooth Supported Overdenture Retained with Custom Attachments: A Case Report. *J Indian Prosthodont Soc.* 14:283-6.
9. Wolf K, Ludwig K, Hartfil H, Kern M (2009). Analysis of retention and wear of ball attachments. *Quintessence Int.* 40:405-12.
10. Samra R, Bhide S, Goyal C, Kaur T (2015). Tooth supported overdenture: A concept overshadowed but not yet forgotten! *J Oral Res Rev.* 7:16.