

Case Report

Large Erupting Maxillary Odontome: A Case Report with Literature Review

Amit Bali¹, Pareedhi²

¹Professor, Department of Oral and Maxillofacial Surgery, M.M. College of Dental Sciences and Research, Mullana, Ambala, Haryana

²MDS Student, Department of Oral and Maxillofacial Surgery, M.M. College of Dental Sciences and Research, Mullana, Ambala, Haryana

ARTICLE INFO



Keywords:

Odontogenic tumours, maxillary odontomes, maxillary sinus, treatment

ABSTRACT

Odontomas are the most frequently occurring tumours of odontogenic origin. The case presented is of a young male patient who reported with a swelling present over the right side of his face and a missing right maxillary second molar. Routine radiographic investigations suggested the presence of a complex odontoma involving the right maxillary sinus with the missing molar positioned superior to it. Surgical enucleation of the mass was carried out with peripheral curettage. A literature review is done to discuss similar uncommon cases involving the maxillary sinus and gradual eruption into the oral cavity by the odontome.

INTRODUCTION

Odontomas are the most common benign tumours of odontogenic origin, their reported occurrence ranging from 21 % to 67 %.^{1,2} They are hamartomas that can be composed of assorted dental tissues such as enamel, dentin, cementum and even pulp. They are usually found to be slow-growing without signs of aggressive behaviour. Complex odontomas are encountered less commonly than the compound variety in the ratio of 1:2.¹ The eruption of an odontoma into the oral cavity is quite rare. The case presented here is of complex odontoma in an adolescent male patient, which was progressing towards eruption into the oral cavity in the posterior area of the right maxillary alveolus and involving the maxillary sinus.

CASE REPORT

A 16 years old male patient reported to Dept. of Oral and Maxillofacial Surgery with chief complaint of swelling over right side of mid-face region for 10 days. There was no significant medical or dental history. The swelling was associated with mild pain and tenderness. Extra-orally the swelling extended supero-inferiorly from right infra- orbital margin till the level of angle of mouth, and antero – posteriorly from nasolabial angle till level of middle third of zygomatic arch. Intra – orally, the swelling had obliterated the right buccal vestibule from the tuberosity till the second premolar. Small areas of soft tissue loss were present over the tuberosity area exposing the tumour into the oral cavity.

The orthopantomogram(OPG) revealed a large radiopaque lesion extending into the right maxillary sinus with a superiorly displaced second molar (Figure

* Corresponding author: Dr. Pareedhi, MDS Student, Department of Oral and Maxillofacial Surgery, M.M. College of Dental Sciences and Research, Ambala, Haryana – 133203. Email: drpareedhi@gmail.com, Phone Number: 08685048120

1). NCCT face was advised for further imaging. There was a well - defined complex lesion with ossified component involving the alveolar arch of maxilla on right side measuring 3.4 cm × 2.5 cm × 2.4 cm. Associated erosions of buccal and palatal cortices were seen with unerupted second molar tooth at the superior aspect of the pathology projecting into the right maxillary sinus. (Figure 2)

A provisional diagnosis of complex odontoma was made and surgical enucleation under general anaesthesia was planned.

Patient was taken up under general anaesthesia and right maxillary crevicular incision was given extending from canine till the distal end of maxillary tuberosity with releasing incision distal to right maxillary canine. Mucoperiosteal flap was raised and the lesion was exposed completely. The lesion was gently elevated from surrounding tissues without further damage to the walls of the maxillary sinus and removed. It was separated from the surrounding bone using a surgical drill and burr. The superiorly displaced tooth was also removed subsequently. (Figure 3) Peripheral curettage was done and the cavity was irrigated with Betadiene solution and normal saline. Primary closure of the incision was done with 3 - silk suture after complete haemostasis was achieved.

The enucleated specimen was sent for histopathological examination, and the diagnosis of complex odontoma was confirmed. (Figure 4)

The patient was placed on post - operative analgesics and antibiotics and discharged on the 3rd post - operative day.

DISCUSSION

Odontomas are usually incidental radiographic findings diagnosed in the second decade of age and are in general classified as mixed radiolucent/radiopaque odontogenic tumours.³

Odontomas can be broadly classified into 2 types: the compound type that usually consists of formed tooth-like calcified structures and the complex type that is a haphazard and disordered organization of calcified dental structures. The complex type is more prevalent in the mandible in the posterior region while the compound type is more prevalent in the anterior maxillary region.⁴ The reported case of complex odontoma doesn't conform to the usual trend of occurrence of this lesion as it was situated in the posterior maxillary region.

Odontomas of the maxilla can be situated in close vicinity to the maxillary sinus. They can grow to a large size, partially or fully obliterating the antral cavity, yet remaining asymptomatic. Routine clinical signs of odontoma may include pain, swelling, retention of deciduous teeth, unerupted/ missing permanent teeth, expansion of the cortical plates and displacement of adjacent teeth. Other symptoms include paraesthesia in the upper or lower lip and soft tissue of the affected area.^{5, 6, 7, 8}

The mechanism of eruption of odontoma seems to be different from tooth eruption because of the absence of periodontal ligament, the mechanism behind the eruption times remains ambiguous as some erupt at a young age and others at an older age. The increase in

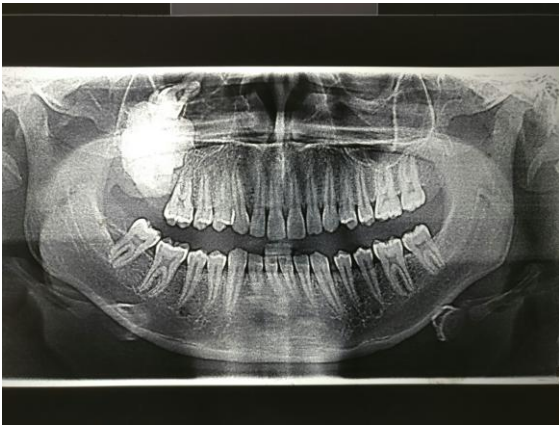


Figure 1: OPG showing a radiopaque mass involving the posterolateral wall of the right maxillary sinus with a superiorly positioned maxillary molar

the size of the tumour produces a force adequate to lead to bone resorption. Erupted odontomas are most often seen in older people due to the resorption of the edentulous part of the alveolar process. Eruption at a young age is possible through bony remodelling that may have resulted from dental follicles.⁶

The primary treatment protocol followed for these tumours is surgical enucleation. Small to medium-size odontomas can generally be removed with ease, depending on their proximity to adjacent vital structures. Nevertheless, accessing large odontomas can present a dilemma, especially for those encased densely in bone.

Removal of large maxillary tumours can lead to gross osseous defects in the maxillary sinus walls, resulting in functional or cosmetic problems post-operatively.⁵ Troeltzsch et al suggested a standard maxillary vestibular incision for removal of maxillary odontomes.² Another accepted approach to tumour removal directly through the anterior and lateral walls

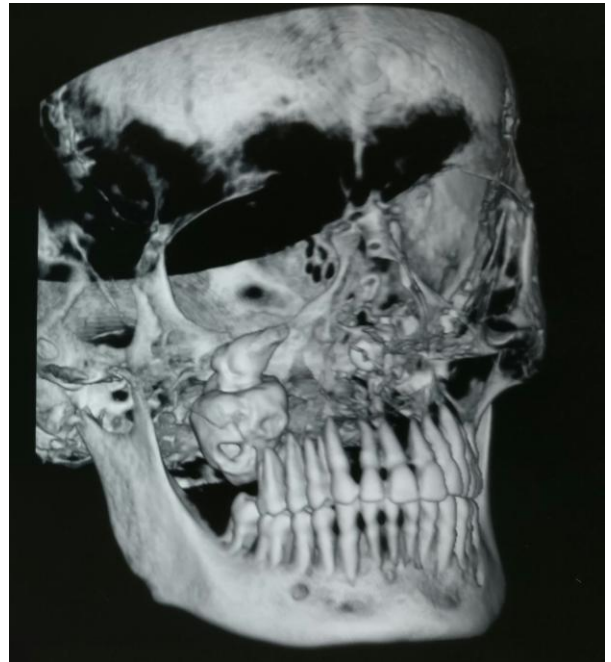


Figure 2: 3D reconstruction of NCCT face displaying a large ossified mass

of the maxillary sinus is the Caldwell-Luc antrostomy approach.³ Korpi et al have, however, suggested a Le Fort I down-fracture approach for removal of the same as they believe it provides excellent exposure of the tumour and avoids sacrificing large amounts of maxillary bone with minimal chances of oroantral fistula formation. They opine that even though the Caldwell-Luc antrostomy approach seems to be more suitable, the Le Fort I technique provides better access for removal of large odontomes in the posterior region of maxilla.⁵

The size of the tumour in the case reported was quite large on removal, measuring about 3×3 cm, similar to those removed by other operators from the maxilla.^{3, 5, 6} The largest odontoma reported in literature weighed 0.3 kg.⁹ The large size of this lesion makes an enigma from a surgical point of view, and the most

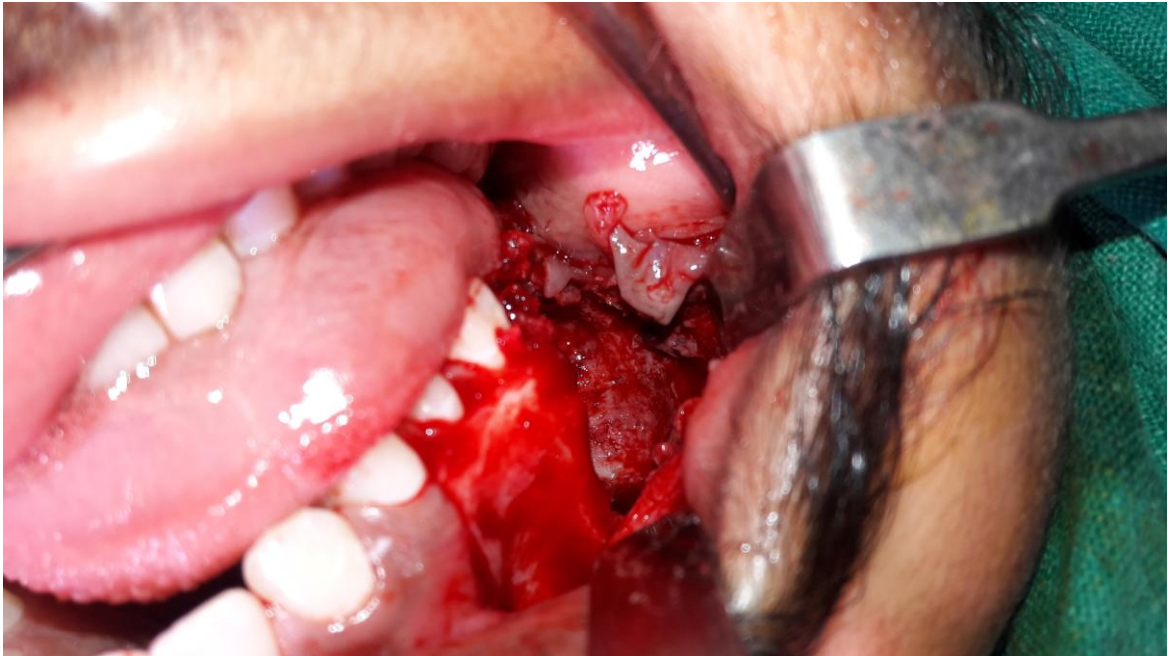

Figure 3: Exposure of the odontome during surgery

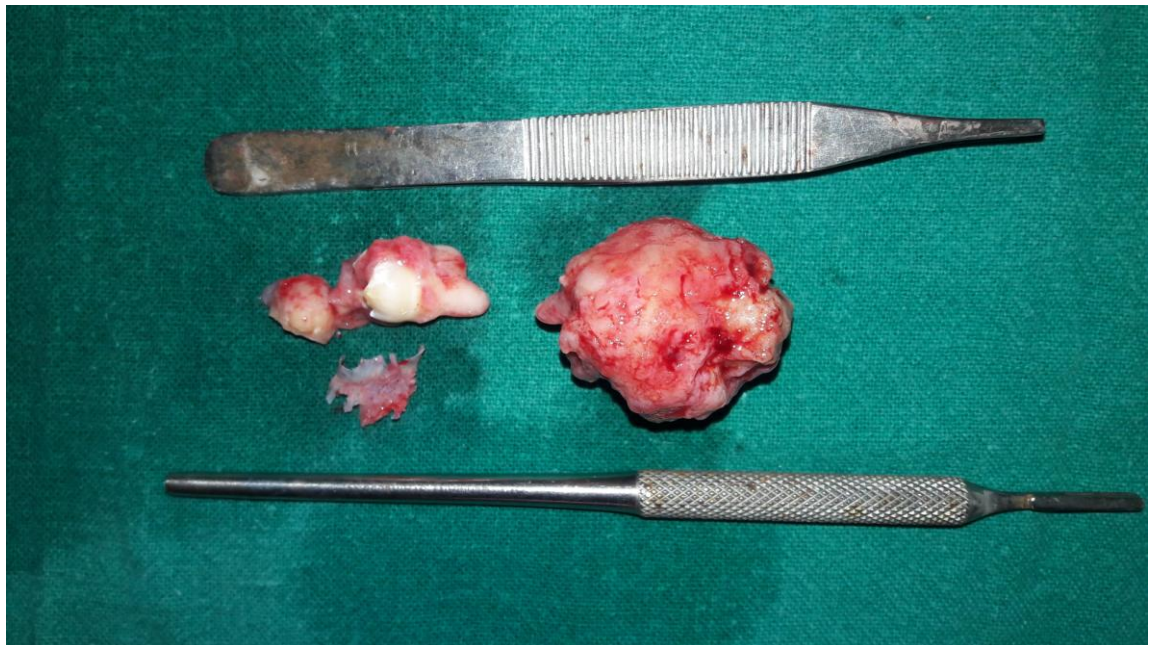

Figure 4: Excised specimen along with the unerupted tooth

appropriate approach must be chosen so that there is no inadvertent injury to adjacent structures. The integrity of the walls of the maxillary sinus must be maintained while an attempt should be made to remove the entire tumour. Number of large maxillary odontomes reported in the literature are quite few, their removal is the general consensus with judicious surgical technique.

REFERENCES

1. Shafer, W. G., Hine, M. K., and Levy, B. M.: A Textbook of Oral Pathology, 6th Ed, 2009, Philadelphia, Elsevier, pp 287 - 290.
2. Troeltzsch M, Liedtke J, Troeltzsch V, Frankenberger R, Steiner T, Troeltzsch M. Odontoma-Associated Tooth Impaction: Accurate Diagnosis with Simple Methods? Case Report and Literature Review. *J Oral Maxillofac Surg* 2012; 70: e516-e520.
3. Singer SR, Mupparapu M, Milles M, et al: Unusually large complexodontoma in maxillary sinus associated with uneruptedtooth. *N Y State Dent J* 2007; 73: 51 - 53.
4. Fonseca RJ. Oral and Maxillofacial Surgery: Surgical Pathology Volume 5, 2008, Philadelphia, Elsevier, pp 379 – 381.
5. Korpi JT, Kainulainen VT, Sandor GKB, Oikarinen KS. Removal of Large Complex Odontoma Using Le Fort I Osteotomy. *J Oral Maxillofac Surg* 2009; 67:2018 – 2021.
6. Vengal M, Arora H, Ghosh S, Pai KM. Large Erupting Complex Odontoma: A Case Report. *J Can Dent Ass* 2007; 73(2): 169 – 172.
7. De Visscher JGAM, Guven O, Elias AGMJ. Complexodontomainthe maxillarysinus. *Int J Oral Surg* 1982; 11: 276-280.
8. Ragalli CC, Ferreria JL, Blasco F. Large erupting complex odontoma. *Int J Oral MaxillofacSurg*2000; 29(5): 373-374.
9. Worth HM: Principles and Practice of Oral Radiographic Interpretation.Chicago: Yearbook Medical, 1963, pp 420-424.