

**CASE REPORT****Transsurgical Autogenous Re Attachment Of Coronal Fragment In Anterior Fractured Tooth- A Case Report & Interdisciplinary Management****Roma Kewlani<sup>1</sup>, Arati C Koregol<sup>2</sup>, Nagaraj Kalburgi<sup>3</sup>, Waseem Ahmed Kazi<sup>4</sup>**<sup>1</sup> MDS Periodontics, Consultant Periodontist at Narayana Health City, Bangalore, Karnataka<sup>2</sup> Professor, Dept of Periodontics, PMNM Dental College & Hospital, Bagalkot, Karnataka<sup>3</sup> Professor and Head of the Department, Dept of Periodontics, PMNM Dental College & Hospital, Bagalkot, Karnataka<sup>4</sup> MDS Periodontics, Consultant Periodontist and Implantologist at Clove Dental Bangalore, Karnataka

## ARTICLE INFO



Keywords:

Reattachment, anterior fractured tooth, interdisciplinary management

## ABSTRACT

Tooth fragment reattachment technique is an esthetic, cost effective conservative option for fractured anterior teeth. In the present case report mucoperiosteal flap was reflected as the fracture extended subgingivally and tooth fragment was reattached using light cure flowable composite. Post treatment re-evaluation of treated tooth at an interval of 3 and 6 months, demonstrated functional and aesthetic harmony with the adjacent oral tissues. For a duration of one year the follow-up evaluation of periodontal, pulpal, and occlusal status was done. Thus reattachment offers a viable technique with medium term prospects.

**Introduction**

Tooth fracture can occur at any age due to trauma. Impact of trauma on tooth varies from mild enamel chipping to complex crown root fractures. Aesthetic and functional involvement of tooth fracture is determined by its severity and age of the patient. About 5% of all dental traumas are found to be associated with crown root fractures.<sup>1</sup> Severe pain in crown root fracture cases can be either due to exposure of pulp or due to collateral periodontal tissue injury or both.

Clinical considerations for determining the treatment plan and prognosis of coronal teeth fractures include the extent of fracture, pulp involvement, periodontal status, biological width violation, pattern of

alveolar bone fracture, degree of restorability of fractured tooth, secondary traumatic injuries, presence/absence of fractured tooth fragment and the fit between the fragment and remaining tooth, occlusal status, aesthetics and finances.<sup>2</sup>

Subgingival extension of fracture presents concern with regard to biological width violation. Periodontal flap surgery combined with osteoplasty procedures is indicated for deep subgingival fractures to comply with the requirement of biological width.<sup>3</sup> Tooth fragment reattachment techniques constitute a prime step in restoring fractured anterior teeth.<sup>4</sup> Tooth fragment reattachment is attaining wide acceptance as it offers a conservative approach alternative to the restoration of

\* Corresponding author: Dr. Roma Kewlani, MHF 091, DLF Maiden Heights, Bommasandra Jigani link road, Bangalore, Karnataka 560105. Mobile no. 9945347324, 9886724550, romakewl@gmail.com

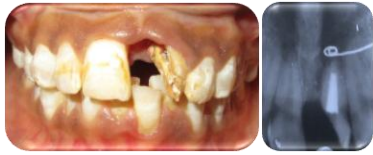

Figure 1: Pre-operative view: clinical and radiograph showing coronally fractured left maxillary central incisor

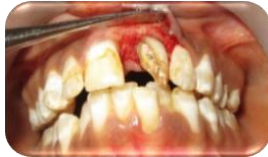

Figure 2: Incisions given and mucoperiosteal flap reflected, fracture extending subgingivally

the fractured tooth with resin-based composite or full-coverage crown. Enduring aesthetics are obtained since original anatomic form of tooth, color, and surface texture are preserved. It is adequately simple technique and results in favourable psychological patient response.<sup>5</sup>

It is cost effective and requires fewer chair side appointments. The present case report illustrates an interdisciplinary approach to the management of maxillary left central incisor crown fracture extending subgingivally.

## CLINICAL REPORT

A 17 year old female patient presented to the Outpatient Department of PMNM Dental College and Hospital, Bagalkot, Karnataka with the chief complaint of her fractured but intact maxillary left central incisor due to history of trauma four years back and wanted it to be replaced out of esthetic concerns.

The fractured but intact fragment of tooth was extracted atraumatically under local anaesthesia and placed in Hanks balanced salt solution (HBSS) to prevent dehydration uptill the reattachment procedure.

Clinical and radiographic examination exhibited crown fracture extending on the mesiolabial and mesio palatal aspect subgingivally (Figure 1).

During the clinical examination, on probing the

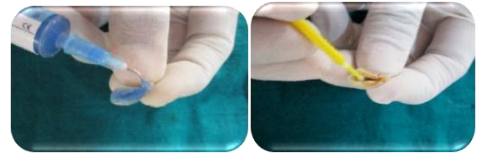


Figure 3: Etching of tooth fragment and application of primer after rinsing and drying

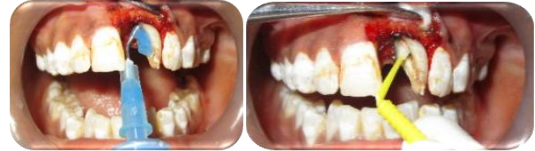

Figure 4: Etching of fractured tooth and application of primer after rinsing and drying

fractured tooth circumferentially it was determined that the biological width was not violated and that bone recontouring via osteoplasty would not be indicated or required as long as the restorative margin were placed at or above the level of the cemento enamel junction.

Consent was obtained from the patient who was previously informed about eventual risks such practices may involve. The aim was to preserve the greatest amount of supporting bone and to render rational treatment. As a first step, antisepsis and anaesthesia of the involved tooth was carried out. The tooth fragment was tested for adaptation and occlusion.

To gain access to the subgingival fracture line and verify that the fracture did not extend apically, a mucoperiosteal flap was planned. Sulcular and vertical releasing incisions were given. Flap was reflected, fracture line and its relation with underlying alveolar bone was evaluated (Figure 2). The operative procedure was performed in a moisture-free field, which was maintained with the help of high volume suction and cotton roll isolation.

Acid etching was done on both the fragment and the tooth using 37% phosphoric acid for 15 seconds and thoroughly rinsed off (Figure 3). A bonding agent [adper single bond2, 3M ESPE] was applied and light cured for 15 seconds (Figure 4). A flowable composite resin (A2, Flowable, 3M ESPE) was used to perform

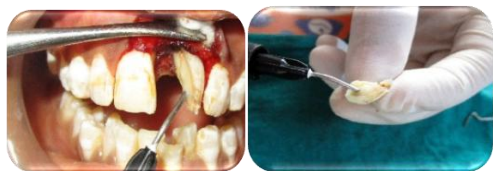

Figure 5: Application of flowable composite to the fractured tooth and the tooth fragment

attachment (Figure 5). After receiving a slight layer of resin, the fragment was repositioned and kept in position until light polymerization was completed. The surgical site was closed, and interrupted sutures were placed. Coe pack dressing was given and patient was recalled after 10 days for re-evaluation and suture removal. The occlusion was examined and the patient was sent after instructions to avoid exerting masticatory or other loads on this tooth and to follow regular oral hygiene procedures. Suture removal was done, postoperative view at 10<sup>th</sup> day shown in figure 6.

Post treatment re-evaluation of treated tooth at an interval of 3 and 6 months, demonstrated functional and aesthetic harmony with the adjacent oral tissues (Figure 6). The crown was placed after re-evaluation of the reattached tooth. One year follow-up examination of pulpal, periodontal and occlusal status was done. Radiographic examination revealed no significant pulpal or periapical changes. No alterations in the periodontium that could jeopardize the treatment were observed. The treated tooth continued to be in functional and aesthetic harmony.

## DISCUSSION

Fracture of anterior teeth after trauma adversely affects the psychological well-being of a person apart from causing discomfort and pain. Restorative design of such fractured teeth is influenced by the complexity and extension of fracture. Reattachment of the tooth is a possibility when the broken fragment is intact and available. It offers diverse benefits over conventional

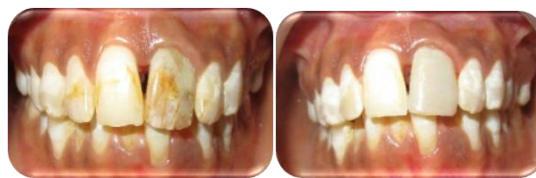

Figure 6: Postoperative view on the 10th day and after 6 months of reevaluation

restorative methods. The translucency of natural tooth is retained and its abrasive resistance is greater than composites.

Also, preservation of natural tooth structure has positive emotional and social response from the patient. Various studies have shown that the impact strength of reattached tooth is not significantly different from that of the intact natural tooth.<sup>6,7</sup>

Depending on these factors various treatment options are composite restorations, orthodontic extrusion, surgical extrusion or crown lengthening followed by post and core supported restorations and reattachment of fractured fragment.<sup>8</sup>

Composite restorations can be considered only for less extensive fractures in enamel and dentin. Post and core supported crowns are recommended in cases of major tooth loss where the fractured fragment is not available. Orthodontic extrusion or surgical extrusion is recommended before the restoration when fracture extends beyond alveolar crestal bone. Whereas if fracture is lying coronal to the crest, reattachment is preferred.

Reattachment procedure is decisively affected by the extension of tooth fracture and trauma to the attachment apparatus. In the present case report as the fracture was supraalveolar extending subgingivally, mucoperiosteal flap was reflected to achieve sufficient access, visibility and isolation. Endodontic treatment was done previously.

Endodontically treated teeth can be reinforced with the use of resin composite restoration. The flowable composite reinforces the tooth, helps in achieving higher

bond strengths and minimizes the inclusion of air voids.<sup>9</sup>

The use of natural tooth substance clearly eliminated problems of differential wear of restorative material, unmatched shades and difficulty of contour and texture reproduction associated with other restorative techniques.<sup>5</sup>

Available clinical evaluation for longevity of reattachment shows medium-term prospects. A seven-year follow-up of crown reattachment showed mild discoloration of crown without any evidence of fracture.<sup>10</sup> Long-term follow up is required to assess the longevity of reattachment technique. Development in adhesive technology may provide a long-established bonding to achieve better prospects of reattachment procedure in future.

## SUMMARY

Mucoperiosteal flap reflection is required when the fracture extends subgingivally for better assessment of fracture extension and tooth-alveolar bone relationship. Reattachment is an effective technique that restores function and esthetics, and it is primarily indicated when treating younger patients with coronal fractures of anterior teeth.

## ACKNOWLEDGEMENT

I would like to acknowledge Department of Endodontics, PMNM Dental College and Hospital, Bagalkot, Karnataka for their support.

## REFERENCES

[1] Andreason JD, Andreason FM, and Andersson L. Textbook and Colour Atlas of Traumatic Injuries to Teeth, Blackwell, Oxford, UK, 4th edition, 2007.  
 [2] Olsburgh S, Jacoby T, and Krejci I. Crown fractures in the permanent dentition: pulpal and restorative

considerations. *Dent Traumatol* 2002; 18(3): 103-115.

[3] Baratieri LN, Monteiro S, Cardoso CA, and Andrada MAC. Coronal fracture with invasion of the biologic width: a case report. *Quintessence Int* 1993; 24(2): 85–91.

[4] Chosack A and Eidelman E. Rehabilitating of a fractured incisor using the patient's natural crown: a case report. *J Dentistry for Children* 1994; 71: 19–21.

[5] Maia EA, Baratieri LN, de Andrada MA, Monteiro S Jr, de Araújo EM Jr. Tooth fragment reattachment: Fundamentals of the technique and two case reports. *Quintessence Int* 2003; 34: 99-107.

[6] Farik B, Munksgaard EC, and Andreasen JO. Impact strength of teeth restored by fragment-bonding. *Dent Traumatol* 2000; 16(4): 151–153.

[7] Farik B and Munksgaard EC. Fracture strength of intact and fragment-bonded teeth at various velocities of the applied force. *Eur J Oral Sci* 1999; 107(1): 70–73.

[8] Macedo GV, Diaz PI, De O Fernandes CA, Ritter AV. Reattachment of anterior teeth fragments: A conservative approach. *J Esthet Restor Dent* 2008; 20: 5-18.

[9] Trope M, Maltz DO, Tronstad L. Resistance to fracture of restored endodontically treated teeth. *Dent Traumatol* 1985; 1: 108-111.

[10] De Castro JCM, Poi WR, Pedrini D, Tiveron ARF, Brandini DA, and de Castro MAM. Multidisciplinary approach for the treatment of a complicated crown-root fracture in a young patient: a case report. *Quintessence Int* 2011; 42(9): 729–734.