

Review Article

Interrelationship Between Prosthodontics And Periodontics-A Review Article

Preetika bansal¹, Pardeep Bansal ², Tejinder ³

¹ Associate Professor, Department of Periodontics, Dasmesh Institute of Research and Dental Sciences, Faridkot, Punjab

² Professor & Head, Department of Prosthodontics, Dasmesh Institute of Research and Dental Sciences, Faridkot, Punjab

³ PG Student, Department of Prosthodontics, Dasmesh Institute of Research and Dental Sciences, Faridkot, Punjab

ARTICLE INFO



KEYWORDS: Prosthodontics,
Periodontics,Occlusal effects,
inflammation

ABSTRACT

Sound periodontium is of utmost importance for the success of restorative therapy and maintenance of periodontal health for the long term success of prosthetic treatment. the collaborative discipline between prosthodontics and periodontics are much needed for the good prognosis of the prosthodontic treatment. For the facilitation of this collaboration, prosthodontists should appreciate the periodontic implications of gingival displacement procedures and tooth preparation and should also have knowledgeable about the types of gingival tissues, osseous topography, occlusal effects, and their implications for abutment choice. Hence the prosthodontics and periodontics share an intimate and inseparable relationship in multiple aspects, including treatment plan, procedures execution, outcome achievement and maintenance.

INTRODUCTION

Sound periodontium is of utmost importance for the success of restorative therapy and maintenance of periodontal health for the long term success of prosthetic treatment. the collaborative discipline between prosthodontics and periodontics are much needed for the good prognosis of the prosthodontic treatment. For the facilitation of this collaboration, prosthodontists should appreciate the periodontic implications of gingival displacement procedures and tooth preparation and should also have knowledgeable about the types of gingival tissues, osseous topography, occlusal effects, and their implications for abutment choice. Hence the prosthodontics and periodontics share an intimate and inseparable relationship in multiple aspects, including treatment plan, procedures execution, outcome

achievement and maintenance. Periodontists provide a solid foundation for successful prosthetic outcomes by controlling inflammation and preparing sites for proper prosthetic treatment. On the other hand, prosthodontists should make proper restorative margin, shapes and contacts that benefit the harmony of periodontium and prosthesis. This article is aimed to address the relationship between prosthodontics and periodontics. The impacts of healthy periodontium on longevity of prostheses are discussed.

*Corresponding author: Dr Pardeep Bansal, Professor & Head, Department of Prosthodontics, Dasmesh Institute of Research and Dental Sciences, Faridkot, Punjab

IMPLANT SUCCESS DEPENDANT UPON HEALTHY PERIODONTIUM

Interdisciplinary dental rehabilitation should be contemplated as a long term solution for esthetic and functional dental rehabilitation of patients. The therapeutic decisions must be based on the biological health of the periodontal and dental implant foundation and must respect the functional occlusion and dental alveolar anatomy to obtain longevity of the treatment. Many deficiencies can be present in patients that include loss of vertical dimension, dental caries, esthetics and speech concerns, periodontal diseases and arch discrepancies. For making an appropriate clinical treatment planning decisions, a thorough diagnosis and evaluation of their prognosis is pertinent. It is must to understand patient's chief complaint and then the patient must be made aware of various treatment options and their effectiveness.

Nowadays dental implants have become an integral part in restorative dentistry. Today's implant dentistry is not restricted to the basic needs but has evolved to cosmetic or esthetic correction. Achieving a good success rate in terms of stability is not the sole requirement but esthetic success of the therapy is also a major concern now. Maintaining the interdental papilla and bone height along following implant placement has been a challenge for the prosthodontist. The presence or absence of interdental papilla associated with multiple adjacent implants may be affected by the amount of alveolar bone loss prior to implant placement, distance between adjacent implants, position of implants in relation to adjacent teeth as well as the subgingival contours of the implant supported restoration.

HEALTHY PERIODONTIUM AFFECTING PROSTHETIC THERAPY

Tooth prognosis should be addressed both on individual tooth and the overall dentition before planning a treatment. All prosthetic and restorative therapies generally require a healthy periodontium as a prerequisite for successful outcome. Determination of individual teeth prognosis allows a virtual approach on interdisciplinary conversation for treatment strategies as the important portion of dental practice. Healthy periodontium is required for good prognosis of the implant, so any peri-implant or active periodontal disease should be treated prior to the prosthodontic construction. Signs of diseased periodontium include pocket formation, presence of bleeding on probing and tissue changes of gingival. If the periodontal inflammation is not controlled, it will lead to various adverse events of periodontal destruction. Function and life span of prosthesis are compromised in case of diseased periodontium.

In case of successful prosthetic treatments, periodontists help in preparing sites by soft and hard tissue management. Regular periodontal maintenance is a key to reduce the incidence of tooth or implant loss following prosthetic therapy. In cases of lack of home care routines, professional assistance is necessary. The subgingival restorations are known to accumulate plaque from their cervical margins, the plaque is likely to proliferate apically and cause periodontal destruction and loss of the tooth. Regular compliance of periodontal maintenance is the key to prevent the recurrence of periodontal diseases and to maintain the integrity of treatment outcomes.

RELATION BETWEEN FIXED PROSTHODONTICS AND PERIODONTICS

In case of fixed prosthodontics, the chief complaint is inability to eat satisfactorily due to missing teeth. Patients' requirement is replacement of missing teeth with fixed prosthesis. In such cases it is critical to assess the abutment via periodontal perspective for long as well as short term treatment planning. Many periodontal factors need to be examined before finalizing the treatment plan like tooth mobility, furcation involvement, severity of bone loss, bleeding or exudation from gingival pockets. If any of these factors is compromised, proper periodontal health of abutment teeth should be achieved before giving a fixed prosthesis.

Maintenance of periodontal health and prevention of gingival breakdown should be kept in mind while designing and fabricating a fixed prosthesis. The given fixed prosthesis should be self-cleansing and at the same time esthetic and functional. There are greater chances of pocket depth and increased loss of clinical attachment levels in case of open contacts between the crowns and the adjacent teeth. Food entrapment and plaque accumulation can be prevented by supragingival margins.

PERIODONTAL THERAPY AND REMOVABLE PROSTHODONTICS

Fixed prosthodontics is not always feasible in patients, even in case of sound periodontium due to financial or medical conditions. Removable prostheses are retained by means of clasps and retentive arms on the abutment teeth adjoining edentulous spaces. Faulty design of prosthesis leads to food entrapment, which in turn increases plaque accumulation and thus there are higher chances of periodontitis. Higher prevalence of gingivitis, plaque, and gingival recession on abutment teeth as compared to non-abutment teeth.

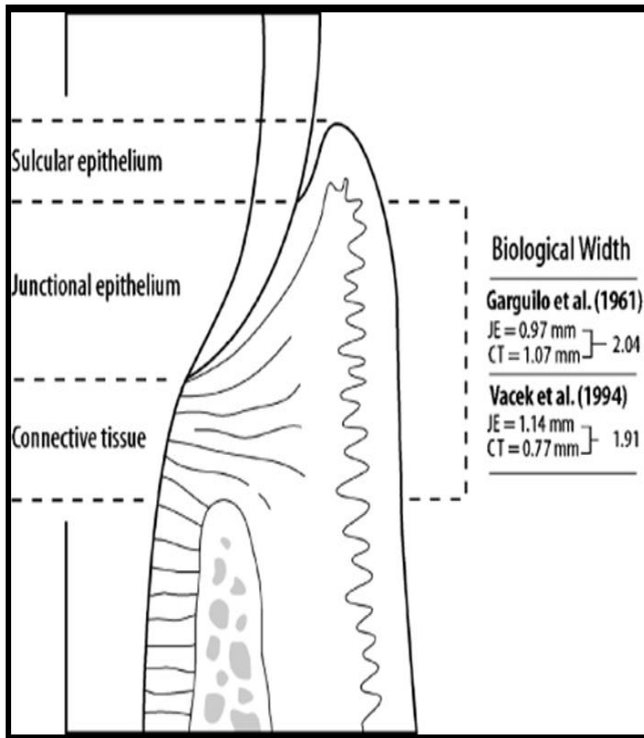
The design of partial denture also plays a role in progression of periodontal disease. In cases where lingual plates or lingual bars were used as major connectors, tooth mobility was significantly reduced due to the indirect retention provided by them.

Biologic Width

The biologic width is defined as the dimension of the soft tissue, which is attached to the portion of the tooth coronal to the crest of the alveolar bone. This term was based on the work of Gargiulo et al. (1961), who described the dimensions and relationship of the dentogingival junction in humans¹⁴. Biologic width is a cuff-like barrier that acts as a protective physiological seal around natural teeth. The violation of Biologic width has been widely discussed as a contributing factor which jeopardizes periodontal health.

The signs of Biologic width violation consist of pain, gingival inflammation, localized gingival hyperplasia, pocket formation, and loss of periodontal apparatus. Therefore, further corrective procedures should be considered prior to restorative treatments if any qualms about Biologic Width violation, including orthodontic extrusion and surgical crown lengthening procedures.

The periodontium are classified into three dimensions: superficial physiologic, crevicular physiologic, and subcrevicular physiologic by Maynard & Wilson in 1979. The superficial physiologic dimension represents the free and attached gingiva surrounding the tooth, while the crevicular physiologic dimension represents the gingival crevice – extending from the free gingival margin to the junctional epithelium. The subcrevicular physiologic space is analogous to the biologic width.



Trauma from occlusion

The tooth and its supporting structures bear the brunt of occlusal forces on the crown, as a functional unit. As a result of occlusal forces the attachment apparatus may experience tissue changes, including injury, repair and adaptive remodeling of the periodontium.

Trauma From Occlusion including occlusal disharmony, parafunction (i.e. clenching and bruxism), and occlusal schemes. Although the role of Trauma From Occlusion plays in periodontal/ peri-implant diseases remains controversial, clinicians should perform prosthetic treatments with caution to avoid failure following Trauma from Occlusion. teeth under TFO or occlusal trauma showed following clinical characteristics: tooth pain, increasing tooth mobility, sensitivity to percussion, fremitus, occlusal wear and even tooth fracture as a result of excessive support or reduced periodontal support. Occlusal overloading also causes biomechanical implant complications and marginal bone loss around dental implants. excess occlusal force could initiate

marginal bone resorption even under the circumstance of healthy peri-implant tissue. fracture of prosthetic component and loosening of attachment or abutment can also occur along with implant overloading, many other complications contribute to biomechanical implant complications like bony quality, implant designs, prosthetic designs and parafunction. Occlusion should be checked prior to dealing with the mechanical complications. Elimination or control of contributing factors should be done before repairing or replacing loosened or fractured components. Non-surgical or surgical intervention may be needed in many cases, patient is advised to wear occlusal splint to prevent biomechanical complication.

Conclusion

With a harmonious stomatognathic system, the relationship between prosthodontics and periodontics is intimate and inseparable. interdisciplinary care for dental rehabilitation can be provided with prosthodontics and periodontics working together. the treatment should be guided by accurate diagnosis, proper evaluation and coordinated planning. Regaining stable periodontal conditions rely on establishment of proper contact types, occlusal scheme and quality prosthesis. Both specialty share a common goal: to create pleasing esthetic

References

1. Abrahamsson I, Berglundh T, et al. -e mucosal barrier following abutment dis/reconnection. An experimental study in dogs. J
2. Berglundh T, Lindhe J, et al. -e so tissue barrier at implants and teeth. Clin Oral Implants Res 1991; 2: 81-90.
3. Berglundh T, Lindhe J. Dimension of the periimplant mucosa.

4. Biological width revisited. *J Clin Periodontol* 1996; 23: 971-3.
5. Bragger U, Lauchenauer D, et al. Surgical lengthening of the clinical crown. *J Clin Periodontol* 1992; 19: 58-63.
6. Chen, J. T., Burch, J. G., Beck, F. M. & Horton, J. E. (1987) Periodontal attachment loss associated with proximal tooth restorations. *Journal of Prosthetic Dentistry* 57, 416–420.
7. Dragoo, M. R. & Williams, G. B. (1981) Periodontal tissue reactions to restorative procedures, Part I. *International Journal of Periodontics and Restorative Dentistry* 2, 8–29.
8. Dragoo, M. R. & Williams, G. B. (1982) Periodontal tissue reactions to restorative procedures, Part II. *International Journal of Periodontics and Restorative Dentistry* 2, 34–42.
9. Ehrlich, J. & Hochman, N. (1980) Alterations on crown contour – effect on gingival health
9. Ericsson I, Persson LG, et al. Different types of inflammatory reactions in peri-implant soft tissues. *J Clin Periodontol* 1995; 22: 255-61.
10. Juloski J, Radovic I, et al. Ferrule effect: a literature review. *J Endod* 2012; 38: 11-9.
11. Lang NP, Loe H. The relationship between the width of keratinized gingiva and gingival health. *J Periodontol* 1972; 43: 623-7.
12. McGuire MK, Nunn ME. Prognosis versus actual outcome. II. The effectiveness of clinical parameters in developing an accurate prognosis. *J Periodontol* 1996; 67: 658-65.
13. Ong M, Tseng S-C, et al. Crown Lengthening Revisited. *Clinical Advances in Periodontics* 2011; 1: 233-9.
14. Oh TJ, Yoon J, et al. The causes of early implant bone loss: myth or science? *J Periodontol* 2002; 73: 322-33
14. Tal H, Soldinger M, et al. Periodontal response to long-term abuse of the gingival attachment by supracrestal amalgam restorations. *J Clin Periodontol* 1989; 16: 654-9.
15. Padbury Jr A, Eber R, Wang H-L. Interactions between the gingiva and the margin of restorations. *J Clin Periodontol* 2003; 30: 379–385.
16. Schmidt JC, Sahrman P, et al. Biologic width dimensions--a systematic review. *J Clin Periodontol* 2013; 40: 493-504.
17. Sorensen JA, Engelman MJ. Ferrule design and fracture resistance of endodontically treated teeth. *J Prosthet Dent* 1990; 63: 529-36.
18. Tatarakis N, Bashutski J, et al. Early implant bone loss: preventable or inevitable? *Implant Dent* 2012; 21: 379-86.
19. Vacek JS, Gher ME, et al. The dimensions of the human dentogingival junction. *Int J Periodontics Restorative Dent* 1994; 14: 154-65.