

Review Article**MASTERING DENTAL IMPLANT PLACEMENT: A REVIEW****Babita Yeshwante¹, Nazish Baig², Sejal Shinde Tambake³, Rohit Tambake⁴, Vishakha Patil⁵, Reshma Rathod⁶**¹ HOD, Dept. of Prosthodontics, CSMSS Dental college, Aurangabad, Maharashtra, India² Professor, Dept. of Prosthodontics, CSMSS Dental college, Aurangabad, Maharashtra, India^{3,5,6} Dept. of Prosthodontics, CSMSS Dental college, Aurangabad, Maharashtra, India⁴ Dept. of Conservative and Endodontics, CSMSS Dental college, Aurangabad, Maharashtra, India

ARTICLE INFO



Keywords:

CAD/CAM, haptics, Yomi

ABSTRACT

The proper positioning of dental implant is essential to prevent damage to vital structures, providing an optimal prosthesis and ensuring a successful long term outcome. Surgical guide template helps in diagnosis, treatment planning, determining proper angulation and positioning of dental implants.

Surgical guide templates can be fabricated using 3 different design concepts-completely limiting, partially limiting and completely limiting design. Advancements in the field of implantology such as three-dimensional imaging, implant-planning software, computer-aided-design / computer-aided-manufacturing (CAD/CAM) technology, computer-guided, and navigated implant surgery have led to the accurate positioning and precise placement of dental implants by the clinician. Nowadays, following the advances in robotic technology, robotics have also found its way into the field of dentistry reducing manual effort and increasing the accuracy of the treatment procedures.

This article thus reviews the recent advances in mastering the art of implant placement.

Introduction

Dental implants have become a widely accepted treatment option for replacing missing teeth. Implants are poised for explosive growth in coming decade. Nevertheless, the inadvertent association of most surgical and prosthetic complications with improper diagnosis and implant placement have also been reported.⁽¹⁾

Earlier dentists were intended to place implants where the greatest amount of bone was present, with less regards to placement of final definitive restoration. In most of the times, the placement of implant is not as accurate as intended. Even a minor variation in comparison to ideal placement causes difficulties in fabrication of final prosthesis.^(2,3) Failures arise as a result of lack of consideration of the super structure

during presurgical planning.⁽⁴⁾ Thus to establish logical continuity between diagnosis, prosthetic planning and surgical phases use of transfer device is essential.⁽⁵⁾ Such a transfer device is termed as Surgical guide template. It not only assist in diagnosis and treatment planning but also facilitate proper positioning and angulation of the implants in the bone. Moreover, restoration driven implant placement accomplished with a surgical guide template can decrease clinical and laboratory complications.⁽⁶⁾ Hence in response to increasing demand for dental implants and perceived complexity in implant placement has resulted in development of newer and advanced techniques for the fabrication of these templates.

The objective of this article is to review the recent advancements in this field based on design concept.

* Corresponding author: *Sejal Shinde Tambake, Email.add. sejaltambake1790@gmail.com*

Stumpel⁽¹¹⁾ was among the initial researchers who worked on surgical stents. He classified surgical stents based on the amount of surgical restriction offered by the surgical guide templates as:

- 1) Non limiting design
- 2) Partially limiting design
- 3) Completely limiting design

1. Non limiting design:

This design indicates only the ideal location of the implant without placing any emphasis on the angulation of the drill.⁽⁶⁾ Thus a non restrictive stent allows the surgeon more leeway in the final positioning and the result may be an implant placed at an angulation or at a position that may complicate the restoration process.⁽⁷⁾

Eg. 1) Vacuum-formed template: **Blustein et al**⁽⁸⁾ and **Engelman et al**⁽⁹⁾ described a technique in which a guide pin hole was drilled through a clear vacuum-formed matrix (Figure 1). This hole indicated the optimal position of the dental implant. However, the angulation was determined by using the long axis of adjacent and opposing teeth.

2) Circumference lead strip guide: **Almog et al**⁽¹⁰⁾ described the circumference lead strip guide in which a lead strip was attached to the external surfaces of the diagnostic waxing. This was used to outline the tooth position over the implant site (Figure 2).

2. Partial limiting design:

In this design, the first drill used for the osteotomy is directed using the surgical guide, and the remainder of the osteotomy and implant placement is then finished freehand by the surgeon.⁽¹¹⁾ Techniques based on this design concept involve fabrication of a radiographic template, which is then converted into a surgical guide

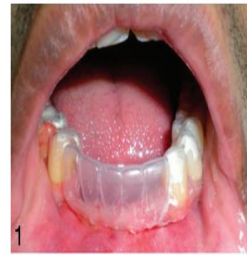

Fig 1: Vacuum-formed template guide

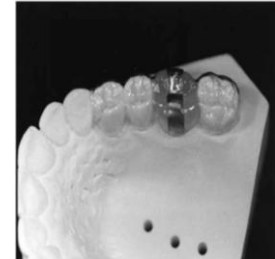

Figure 2: Circumferential Lead strip Guide

template following radiographic evaluation. Various authors have proposed different techniques involving modifications in the following stages of fabrication, namely, material used for the fabrication of the surgical template, radiographic marker used, type of imaging system used, and the conversion process involved in converting the radiographic template into a surgical template.⁽⁶⁾

Eg. 1) Guttpercha guide: **Almog et al** fabricated gutta-percha guide by using autopolymerising acrylic resin with thermoplastic vacuum formed sheets to form templates and gutta-percha as radiographic marker (Figure 3).⁽¹⁰⁾

2) Surgical guide with brass tube: **Becker and Kaiser** fabricated a surgical guide using brass tubes, vacuum formed thermoplastic matrix and orthodontic resin. A 3/16 inch tube was attached to the template and the 5/32 inch brass tube guided the pilot drill (Figure 4).⁽¹²⁾

3) Surgical guide connected to mandibular record base: **Wat et al** fabricated a surgical guide using autopolymerising acrylic resin and barium sulfate in the ratio 4:1.⁽¹³⁾ Guide was connected to the record base

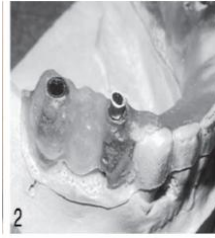
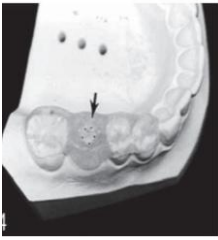

Figure 3: Gutta Purcha Guide **Figure 4 Surgical Guide with Brass tube**

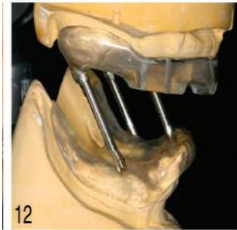


Figure 5: Guide Connected to mandibular base

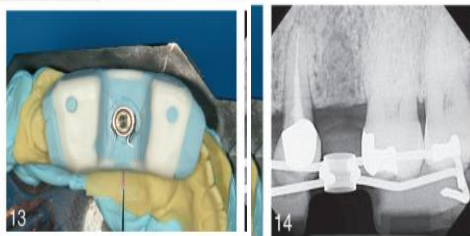


Figure 6: Cast based Surgical Guide

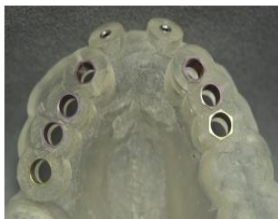

Figure 7 : Comuted Tomography Generated Static Guide

fabricated on the opposing arch, using embedded stainless steel rods and tubes that served as mouth prop for stabilizing the jaw. Surgical guide thus fabricated was indicated for edentulous arch opposing a partially edentulous arch (Figure 5).

3. Completely limiting design:

Completely limiting design constrains all of the instruments used for the osteotomy in a buccolingual and mesiodistal plane. Moreover, the addition of drill stops limits the depth of the preparation, and thus, the positioning of the prosthetic table of the implant. As the surgical guides become more restrictive, less of the decision-making and subsequent surgical execution is done intraorally.

This includes two popular designs: **Cast-based guided surgical guide** and **Computer-assisted design and manufacturing (CAD/CAM) based surgical guide.**⁽⁶⁾

A) Cast-based Guided Surgical Guide:

The surgical guide is a combination of an analog technique done along with bone sounding and the use of periapical radiographs in a conventional flapless guided implant surgery (Figure 6).⁽⁶⁾It allows implant placement in a precise predetermined position. Surgery accomplished with the aid of this guide increases patient’s comfort as it allows for flapless procedure. Since the implant position relative to the surrounding tissue is known, a provisional restoration and if desired, the definitive abutment can be prefabricated ,so that it can be inserted at the time of surgery if an immediate provisional restoration is desired.⁽¹⁴⁾

B) CAD/CAM:

Transferring the virtual treatment plan into actual patient treatment has been made possible by the revolutionary CAD/CAM technique, which is used in two guided surgery systems that is, (a) “Static” or “template-based system,” that communicates predetermined sites using “surgical templates” or implant guides in the operating field, manufactured via rapid prototyping technologies such as three-

dimensional printing and stereolithography or “computer-driven drilling” and (b) dynamic system or “surgical navigation/computer-aided navigation” technology, which communicates virtual treatment plan to the operative field with visual imaging tools on a computer monitor, rather than the intraoral guides.⁽¹⁵⁾

ADVANTAGES:

- It facilitates minimally invasive surgical procedures with surgical guides (CGIS) along with greatly improving the predictability of implant surgery.
- It allows immediate loading by enabling presurgical construction of the master cast and accurately fitting, custom designed restorations.^(16,17)

a. THE COMPUTER GUIDED IMPLANT SURGERY (STATIC SYSTEM)

A static system uses CT-generated computer-aided design and computer-aided manufacturing to create stents, with metal tubes, and a surgical system that uses coordinated instrumentation to place implants using the guide stent (Figure 7). “Static” in this sense is synonymous with a predetermined implant position without real-time visualization of the implant preparation site.⁽¹⁸⁾ The implant position is dependent on the stent without the ability to change the implant position during surgery.

Surgical template fabrication has the following advantages:^(15,16,17)

- It precisely guides the osteotomy drills.

- Directs the surgeon to the exact location and angulation to place the implant based on virtual treatment plan.
- It allows flapless surgery, which entails less bleeding, less swelling, decreased healing time and postoperative pain.
- Aids in the preservation of hard and soft tissue and maintains blood circulation to the surgical site.
- Considerably increased accuracy of implant placement within short period of time.
- Avoidance of vital structures.

Though CGIS technique has been proven as an accurate and viable technique, it also has certain drawbacks and limitations too.

The most common **drawbacks** and **limitations** associated with CGIS include:⁽¹⁵⁾

- Error in data acquisition or incorrect processing of the image.
- Deviations from planned implant positions especially in the coronal and apical portions of the implants as well as with implant angulation.
- Inaccurate fixation of the guide resulting in displacement during perforation.
- Mechanical errors caused by angulation of the drills during perforation.
- Changed positioning of surgical instruments due to reduced mouth opening.
- Fracture of the surgical guide.
- Complexity of the whole system.
- The total cost of tools needed including the software program and surgical templates.
- The potential for thermal injury secondary to reduced access for external irrigation during osteotomy preparation during flapless implant placement with surgical guides.

- Does not allow intraoperative changes during implant placement.

b. COMPUTER NAVIGATED IMPLANT SURGERY(DYNAMIC SYSTEM):

It involves the use of a surgical navigation system that reproduces virtual implant position directly from CT data with the aid of optical bur tracking system to display images onto a monitor without the requirement of fabricating a intraoral surgical guide. At present, the optical systems use either passive or active tracking arrays. Passive systems use tracking arrays that reflect light emitted from a light source back to the stereo cameras. Active system arrays emit light that is tracked by stereo cameras

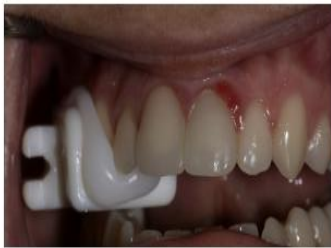

Fig 8: Clip with fiducials placed in the patient's mouth

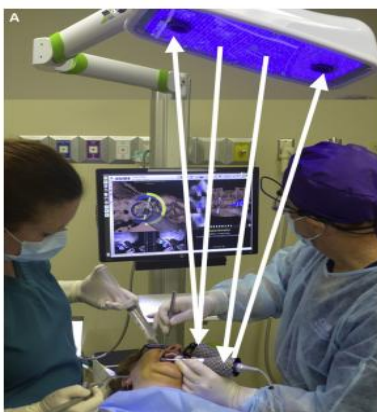


Fig 9:Overhead lights emitting blue lights, which are reflected back to 2 cameras by the arrays on the clip in the patient's mouth and on the handpiece

A passive optical dynamic navigation system (X-Nav Technologies, Inc, Lansdale, PA) requires the use of fiducial markers securely attached to the patient's arch during CBCT scanning (Figure 8). The device that contains the fiducial markers allows for registration of the arch to the cameras, with the attachment of an array. The array is positioned extraorally and attached to the clip that contains the fiducial markers. The implant handpiece also has an array, which combined with the clip's fiducial markers, allows for triangulation and, hence, accurate navigation (Figure 9). The drill and patient-mounted arrays must be within the line of sight of the overhead stereo cameras to be accurately tracked on the monitor.⁽¹⁸⁾

Computer navigated implant surgery has many **advantages** over CGIS in that:⁽¹⁹⁾

- It allows intraoperative changes in implant position that is, the virtual surgical plan can be modified during surgery and the clinician can use the navigation system to concurrently visualize the patient's anatomy, permitting the surgeon to steer around obstacles, defects etc., that were not apparent on the presurgical scan.
- Bur tracking allows the drill to be continuously visualized on a computer screen in all three-dimensions (x, y and z)
- It overcomes other limitations of CGIS like secondary thermal injury, displacement or fracture of guide etc.

Though CNIS technology (using optical tracking systems) has been widely used with superb accuracy but it also suffers the following **limitations**.^[15,18]

- They are sensitive to reflections and interference with the line of sight between the

sensors and the cameras that is, a line-of-sight between the tracking device and the instrument to be tracked has to be maintained, which is not always convenient especially with the typical seating arrangement of dental surgeon and assistant and hence may preclude tracking of instruments.

- Dynamic navigation requires registration of the jaw to the navigation system, which currently cannot use intrabony fiducial markers. For edentulous cases, CNIS cannot be used.
- More expensive as it requires an expensive hardware.
- Requires rigorous intraoperative referencing.
- Significant learning curve.

ROBOTIC TECHNOLOGY:

Robots have been used in medical field for a quite some time now, then why should dentistry be left behind. Neosis, a company based in Miami, Florida has developed ‘Yomi’ a robotically assisted dental surgical system. Yomi received FDA clearance in March 2017. It is computerized navigational system intended to provide assistance in both the planning (pre-operative) and the surgical (intra-operative) phases of dental implantation surgery. The system provides software to preoperatively plan dental implant placement procedures and provides navigational guidance of the surgical instruments. Yomi delivers physical guidance through the use of haptic robotic technology, which constrains the drill in position, orientation and depth⁽²⁰⁾. The word ‘Haptics’ is derived from Greek word ‘haptein’ which means ‘contact’ or ‘to touch’. HAPTICS-are also known as – VIRTUAL REALITY SYSTEMS. ⁽²¹⁾

Haptics are enabled by actuators. Actuators are devices that apply forces for touch feedback, and controllers. Whenever an electrical stimulus is applied, there is mechanical motion in the actuator. Earlier, only electromagnetic technology was used. These electromagnetic motors typically operate at resonance and they provide strong feedback, but produce a limited range of sensations. Newer generations of actuator technologies are emerging, with more rapid response times, which include electroactive polymers, piezoelectric, electrostatic and subsonic audio wave surface actuations. This mechanical stimulation aids in the creation of virtual objects in a computer simulation, to control such virtual objects, and to enhance the remote control of machines and devices, thus providing visual and tactile information to the operator in real time.⁽²²⁾

This assistive technology leaves the surgeon in control at all times. Unlike plastic surgical guides, Yomi allows for clear visualization of the surgical site and enables the surgeon to dynamically change the plan. A typical Yomi system is shown in (Figure 10). In a normal implant surgical procedure, dentists can capture a pre-operative cone beam CT scan (CBCT), but much of that information is effectively lost during the most critical part of the dental implant process: intra-operative surgery.

Yomi enables dentists to bridge the digital imaging preoperatively into their operating environment through the use of haptic robotic technology. They receive real-time physical and visual guidance throughout the surgery. This provides accuracy and reliability without the need to manufacture a custom plastic guide or worry about performing an unguided freehand approach.

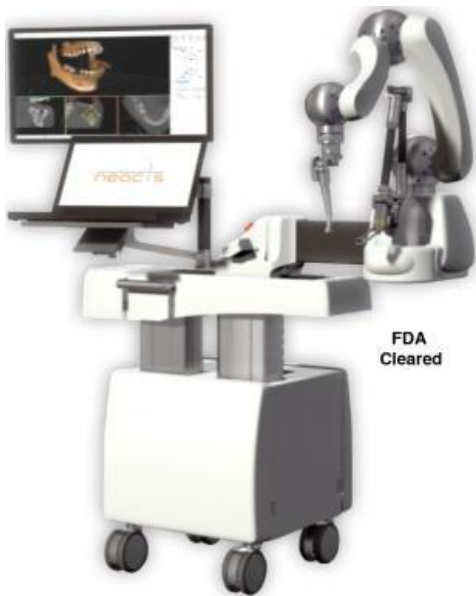

Fig 10:Yomi dental implantology robotic system

ADVANTAGES:

- Extremely high accuracy and precision.
- Stable and untiring, therefore can be used repeatedly without rest.
- Able to accurately process quantitative information fed into the system.

DISADVANTAGES:

- No judgment of the situation and hence unable to use any qualitative information.
- Continuous monitoring under the supervision of experienced dentist is required.
- These devices still remain very expensive and out of reach of the common man.⁽²³⁾

CONCLUSION:

Advances in surgical reconstructive methods as well as increased awareness in patients for esthetics necessitates a highly accurate diagnosis and treatment planning during implant placement in order to achieve

optimum treatment outcome. Completely limiting design as stated earlier is considered far superior design concept but most clinicians adopt and execute implant placement with the aid of partially limiting design concept due to its cost effectiveness and credibility in this field.

Implant placement with robotic assistance in prosthodontics will remain an intensively discussed topic in the future. Remarkable progress has been achieved in the utilizing the positive aspects of robotics in the field of dentistry. Use of sophisticated and specially made robots based on haptic technology helps to achieve the required precision in implant placement under the supervision of an experienced dentist. However taking into consideration the cost factor involved in the setup required for computer navigated implant surgery and implant placement achieved with robotic assistance more research is required in this field.

References:

1. Ganz SD. Presurgical planning with CT-derived fabrication of surgical guides. *J Oral Maxillofac Surg.* 2005;63:59–71.
2. Widmann G, Bale RJ. Accuracy in computer-aided implant surgery: A review. *Int J Oral Maxillofac Implants* 2006;21:305-13.
3. Takeshita F, Suetsugu T. Accurate presurgical determination for implant placement by using computerized tomography scan. *J Prosthet Dent* 1996;76:590-1.
4. Manikandan Ramasamy, Giri1, Ramesh Raja1, Subramonian1, Karthik2, Rachuri Narendrakumar. Implant surgical guides: From the past to the present. *Journal of Pharmacy and Bioallied Sciences* June 2013;5(1):98-102

5. Misch CE. Contemporary implant dentistry; St Louis: Mosby 1993. pp.480-3.
6. Kathleen Manuela D'Souza, Meena Ajay Aras, Types of Implant Surgical Guides in Dentistry: A Review. *Journal of Oral Implantology* 2012; XXXVIII (5) : 643-652
7. Babita Yeshwante, Neha Choudhary, Nazish Baig. Surgical Stent in Implant placement. *Int. Journal of Clinical Dental Science*. October 2014; 5(2):5-11
8. Blustein R, Jackson R, Rotskoff K, Coy RE, Godar D. Use of splint material in the placement of implants. *Int J Oral Maxillofac Implants*. 1986;1:47-49.
9. Engelman MJ, Sorensen JA, Moy P. Optimum placement of osseointegrated implants. *J Prosthet Dent*. 1988;59:467-473
10. Almog DM, Torrado E, Meitner SW. Fabrication of imaging and surgical guides for dental implants. *J Prosthet Dent*. 2001;85:504-508.
11. Stumpel LJ 3rd. Cast-based guided implant placement: a novel technique. *J Prosthet Dent*. 2008;100:61-69.
12. Becker CM, Kaiser DA. Surgical guide for dental implant placement. *J Prosthet Dent*. 2000;83:248-251.
13. Wat PY, Pow EH, Chau FS, Leung KC. A surgical guide for dental implant placement in an edentulous jaw. *J Prosthet Dent*. 2008;100:323-325.
14. Lambert J. Stumpel. Cast based Guided Implant placement : A novel technique. *J Prosthet Dent*. 2008;100:61-69.
15. Minkle Gulati, Vishal Anand, Sanjeev Kumar Salaria, Nikil Jain, Shilpi Gupta. Computerized implant-dentistry: Advances toward automation. *Journal of Indian Society of Periodontology*. 2015;19(1):5-10
16. Spector L. Computer-aided dental implant planning. *Dent Clin North Am* 2008;52:761-75, .
17. Fortin T, Bosson JL, Isidori M, Blanchet E. Effect of flapless surgery on pain experienced in implant placement using an image-guided system. *Int J Oral Maxillofac Implants* 2006;21:298-304.
18. Michael S. Block, DMD,* and Robert W. Emery. Static or Dynamic Navigation for Implant Placement—Choosing the Method of Guidance *J Oral Maxillofac Surg* 2016;74:269-277
19. Jung RE, Schneider D, Ganeles J, Wismeijer D, Zwahlen M, Hämmerle CH, et al. Computer technology applications in surgical implant dentistry: A systematic review. *Int J Oral Maxillofac Implants* 2009;24 Suppl: 92-109.
20. YOMI: redefining the standard of care. Available from <http://www.neosis.com/meet-yomi/>
21. Shalini Kapoor, Palla K Arora, ViKaS Kapoor, MaheSh Jaya Chandran, ManiSh Tiwari. Haptics – Touchfeedback Technology Widening the Horizon of Medicine. *Journal of Clinical and Diagnostic Research*. 2014 Mar, Vol-8(3): 294-299
22. Schmidt RA. Motor control and learning: a behavioural emphasis. Champaign: Human Kinetics Publishers; 1982.
23. S. Sreelekshmi Kurian Varghese Joshy P Abraham Jaysa J. J. Applications Of Robotics In Prosthodontics – A Review. *International Journal of Innovative Research and Advanced Studies* 2017; 4(5):38-41