

## Case Report

# Interdisciplinary treatment approach to the functional and aesthetic rehabilitation of a young patient with Amelogenesis Imperfecta

**Indrani Das<sup>1</sup>**

<sup>1</sup> MDS (Prosthodontics) Consultant, GNRC Medical, North Guwahati

### ARTICLE INFO



#### Keywords:

Amelogenesis imperfecta, full mouth rehabilitation, hypoplastic, decreased vertical dimension, hobo twin stage

### ABSTRACT

Amelogenesis Imperfecta (AI) encompasses a complicated group of hereditary conditions that cause a developmental alterations in the quality and/or quantity of dental enamel in the absence of systemic disorder. The treatment of such patients would not only upgrade their quality of life, but also improves self- esteem. This article describes the sequenced interdisciplinary treatment for a young female patient mutilated permanent dentition caused by hypoplastic type using Hobo's twin stage technique .

### Introduction

Amelogenesis Imperfecta (AI) is a hereditary dysplasia affecting the structure of dental enamel. The anomaly affect both primary and permanent teeth and causes them to be unusually small, discoloured, pitted, grooved and prone to rapid wear and breakage (1). The abnormality can be related to autosomal or x-linked, dominant or recessive modes. The most common is autosomal dominant form. It is known that the gene responsible to codify the most abundant protein of enamel, Amelogenin is related to occurrence of hypomineralised enamel(2)(3). AI has an estimated prevalence of approximately 1:8000 and 1:700(4). Investigations have demonstrated that it is possible to delineate 14 different hereditary sub-types of AI that

exist with numerous pattern of inheritance and wide variety of clinical manifestation.

On the clinical and radiographic basis alone 3 broad groups can be distinguished

- a) Hypoplastic which has reduced in quantity but well mineralised enamel
- b) Hypocalcified which has poorly mineralised normal quantity enamel
- c) Hypomaturation in which final stage of enamel maturation are abnormal(5-10).
- d) According to literature, AI, regardless of the sub-types has similar oral complications. Apart from enamel defects AI has been associated with inclusions and abnormalities in tooth eruption, tooth sensitivity, poor aesthetics and decreased

\* Corresponding author: *Dr. Indrani Das, MDS, House no 24, Jyoti Path , Janakpur, Kahilipara, Guwahati, PIN-781019, Mobile No. : 8011674356, Mail id: inardni@gmail.com*

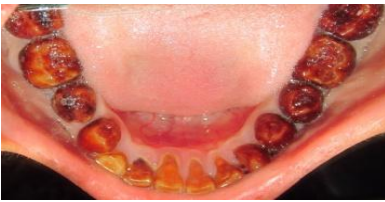
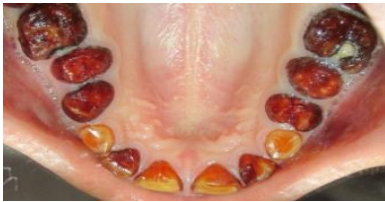
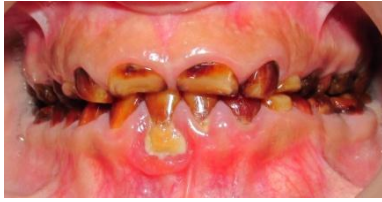Fig 1: Pre-Operative Photos

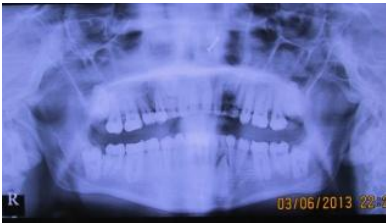

Fig 2: Preoperative OPG

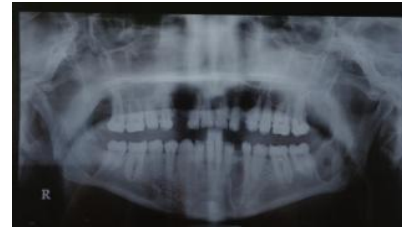

Fig.3: Post Opreative OPG

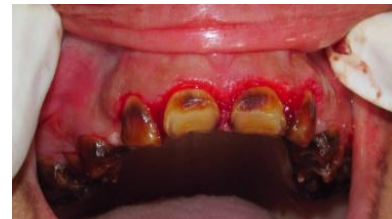
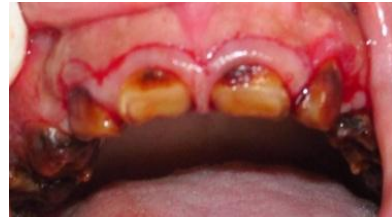
Fig 4: Crown Lengthening Was Done

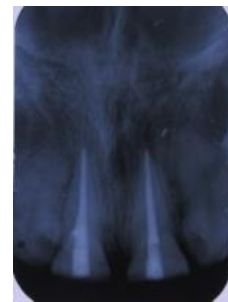


Fig 5: RCT done in 11 &amp; 2

vertical dimension of occlusion (11). Although the subtype and severity of AI may limit treatment potential, a recently published survey reported the importance of treating AI patient not only from functional standpoint but also from psycho-social healthpoint (12)(13). Treatment planning of AI patient is dependent on age, socio-economic status of patient, the type and severity of the disorder and the intra-oral situation at the time of a treatment planning. This article describes the interdisciplinary sequenced treatment approach for young female patient with mutilated and discoloured permanent dentition caused by AI of hypoplastic type.

A comprehensive management of this condition with full mouth metal-ceramic restorations with a corrective vertical dimension of occlusion was done using Hobo & Takayama approach of full mouth rehabilitation.

#### **Clinical Report:**

A 22 year old female patient reported with complaint of stained teeth, generalised sensitivity and chipping of teeth (fig1). Her family history revealed similar condition of her maternal cousin. On intraoral



Fig 6: Diagnostic wax up

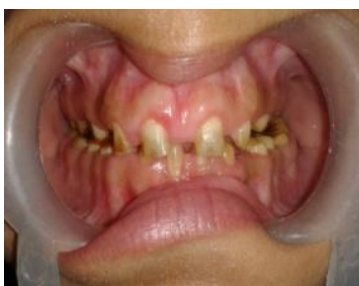

Fig 7: Mouth Preparation

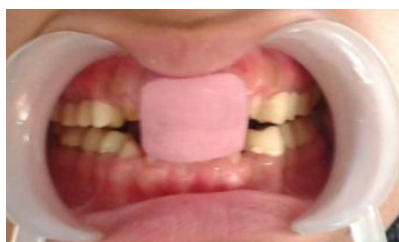

Fig 8: Right and left Temporaries as occlusal stop

examination permanent teeth present were 11, 12, 43, 14, 15,16, 17, 21, 22, 53, 24, 25, 26, 27,31, 32, 63, 34, 35, 36,37, 41,42, 43, 44, 45, 46,47. Gingival health of the patient was unremarkable and had a normal palatal arch. Past medical history of the patient was nonsignificant and the patient appeared to be well nourished with moderate height and built. Patient was advised for OPG, skull and chest X-Ray and full mouth IOPA radiographs. Skull and Chest radiographs did not reveal any significant findings. OPG revealed

impacted 13, 23, 33, 18, 28, 38, 48(fig 2). No evidence of cysts, odontoma or other abnormalities in the radiographs. To rule out any other associated syndrome complex or any other metabolic or hormonal disorder, patient was referred to a physician under whose supervision multiple tests were carried out but all of them were within normal limits.

A initial treatment plan after inter department disciplinary discussion were

- i) Oral surgical : Extraction of impacted teeth and deciduous teeth under GA(fig.3)
- ii) Periodontics : Crown lengthening of 11, 12 for aesthetic reason(fig.4)
- iii) Endodontics : management of 11,12(fig.5)
- iv) Prosthodontic rehabilitation.

After completion of pre-prosthetic procedures prosthodontic treatment protocol was formulated according to Hobo & Takayama philosophy to restore the mutilated and attrited dentition in functional harmony with the stomatognathic system. An increase in 3 mm vertical dimension was also planned. The amount of bite rise to be achieved was evaluated using closest-S speaking space.

### **Procedure:**

#### **Phase I**

Impressions of both arches were made using hydrocolloids and diagnostic casts were obtained. Facebow transfer of maxillary cast was done on semi adjustable articulator (Hanau) and mandibular cast was mounted with a Lucia jig in the anterior regions and inter occlusal records in the posterior region.

#### **Phase II**

An occlusal splint was provided to the patient as part of reversible interventional modalities to evaluate adaptation of the patient to alter VDO. Patient was

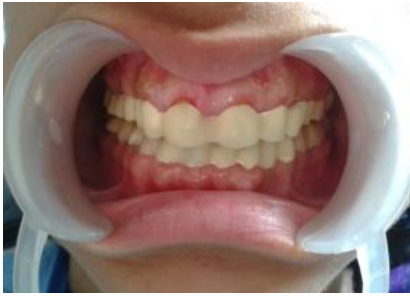

Fig 9: Temporary restorations



Fig 10: metal copings

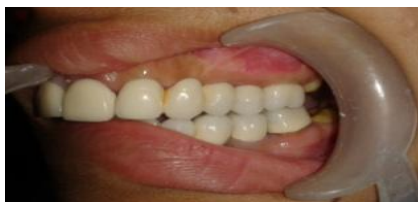
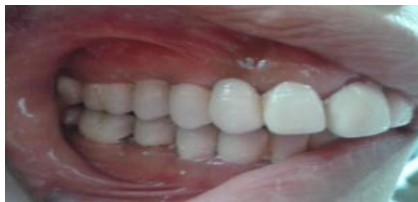
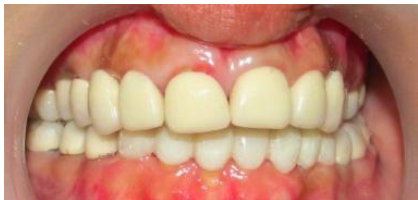Fig 11: Final prosthesis

kept in diagnostic and observational period of 6 weeks before the definitive restorative phase of rehabilitation started. A diagnostic wax up of full mouth restoration was carried out at increased vertical dimension for posterior teeth without the anterior segment of maxillary cast in place (fig.6). To produce standard effective cusp angles, the condylar and incisal guidance were set to condition 1. At this position, the diagnostic wax up was balanced in protrusive and lateral excursion. The anterior segments of cast were reassembled and condylar and incisal guidance were set again (condition-2) and wax up completed so as to generate posterior disclusion.

### Phase III

Mouth preparation was done and stage-II temporaries were fabricated chair side quadrant by quadrant (fig.7). During several appointments, patients VDO was maintained by using unprepared second molar as occlusal vertical stops which are to be prepared later. The second molars were prepared and stage-II temporaries were fabricated using the index of the diagnostic wax-up and cemented with ZnO non eugenol cement and left for 3 weeks.

Once the patient was adapted to this position, final full arch impressions were made using polyvinyl siloxane impression material and casts were poured in die stone. These casts are mounted on articulator using facebow transfer. Now to transfer the vertical dimension and centric relation temporaries of left posterior regions were removed while temporaries of the right side and the anterior regions acted as stop. Inter occlusal recording material was injected between left maxillary and mandibular prepared tooth. Similarly interocclusal record of right side was taken by keeping left posterior temporaries as stop. Anterior

inter-occlusal record was obtained by keeping right and left posterior temporaries as stop(fig.8)(fig.9). Thus 3 segmental intra occlusal records obtained were used to mount the mandibular cast. Wax pattern was fabricated with anterior mandibular segment following conditions 1 & 2. All the wax patterns were cast(fig.10) and bisque trial was done in the patient's mouth. After correcting the interferences the restorations were glazed and luted. PFM definite restorations were cemented using GIC type-1 luting cement (fig.11). A group functional type of occlusal scheme was provided.

#### **Phase IV**

Oral hygiene instructions were given and follow up was done at regular intervals. Anterior metal ceramic crowns were satisfactory both aesthetically and functionally at the end of one year of clinical service and the patients oral hygiene was satisfactory. Psychology of the patient was found to have greatly improved due to aesthetic outcome. Restorations were intact without discoloration or carious lesions.

#### **Discussion:**

Treatment plan for AI cases is dependent on upon certain factors such as age, socio-economic status of patients, type and severity of AI and intraoral condition at the time of treatment planning. In the past such cases were radically treated with multiple extraction and construction of complete denture. Such an approach has deleterious influence on psychological health of patients. With advances in fixed prosthodontics for management of mutilated dentition, such cases can be conservatively treated. In this case, the patient presented with a decreased vertical dimension and increased freeway space so it was

decided to increase VD by 3 mm. The severely attrited anteriors resulted in loss of anterior guidance so as to protect the posterior teeth from excursive movements. The posterior teeth attrition resulted in the loss of occlusal plane and decreased vertical dimension. So in order to restore function and health of the worn-out dentition, the Hobo's Twin stage procedure was planned. There is some difference of opinion on whether to work simultaneously on both arches or individually on different segments of the arch. Those who go for the segmental approach state that it takes less time and is comfortable to patients.

Earlier gnathologists laid utmost importance to condylar guidance, and anterior guidance determination was done by dentist. Thus, anterior guidance and condylar path were considered independent factors. However, recent concepts reveal that anterior guidance influence the working condylar path and even changes when lateral component of incisal path deviates from optimal orbit, thus supporting the hypothesis that anterior guidance and condylar path are dependent factors.

Normally, anterior guidance is  $5^{\circ}$  steeper than condylar path in sagittal plane. Hence when mandible is protruded, the anterior teeth guide it downward, creating posterior disclusion. Similar disclusion is seen laterally because of steeper lingual inclination maxillary canine. The angular difference between anterior guidance and condylar path assists posterior disclusion, but is not solely accountable. The residual amount can be attributed to cusp shape factor. However since CG, AG and cusp shape factor remain integral to Hobo's approach so this procedure cant be performed in cases of patient with abnormal curve of Spee, abnormal curve of Wilson or having rotated or inclined tooth.

**Conclusion :**

This clinical report describes the interdisciplinary cooperation between Periodontist, Oral Surgeon, Endodontist and Prosthodontist for the oral rehabilitation of a young female patient affected by hypoplastic type of AI. Restoration of aesthetics and function with meticulously done metal ceramic restoration based on concept of hobo's twin stage technique resulted in improved oral health impact profile

**References :**

1. Sabatini C, Guzmán-Armstrong S. *A conservative treatment for Amelogenesis Imperfecta with direct resin composite restorations: A case report.* J Esthet Restor Dent. 2009; 21(3):161-170.
2. Lau EC, Mohandas TK, Shapiro LJ, Slavkin HC, Snead ML, *Human and mouse amelogenin gene loci are on the sex chromosomes.* Genomics. 1989 Feb; 4(2):162-8.
3. Takagi Y, Fujita H, Katano H, Shimokawa H, Kuroda T. *Immunochemical and biochemical characteristics of enamel proteins in hypocalcified amelogenesis imperfecta..* Oral Surg Oral Med Oral Pathol Oral Radiol Endod. 1998 Apr; 85(4): 424-30.
4. Crawford PJ, Aldred MJ. *X-linked amelogenesis imperfecta. Presentation of two kindreds and a review of the literature.* Oral Surg Oral Med Oral Pathol. 1992 Apr; 73(4): 449-55.
5. Witkop CJ, Sauk JJ. Heritable Defects of Enamel. In: Stewart R, Prscott G. *Oro Facial genetics.* St. Louis: C. V. Mosby Company, 1996; 151-226
6. Sari T, Usumez A. *Restoring function and esthetics in a patient with amelogenesis imperfecta: a clinical report.* J Prosthet Dent. 2003 Dec; 90(6): 522-5.
7. Winter GB, Lee KW, Johnson NW. *Hereditary amelogenesis imperfecta. A rare autosomal dominant type.* Br Dent J. 1969 Aug 19; 127(4): 157-64.
8. Witkop CJ Jr. *Partial expression of sex-linked recessive amelogenesis imperfecta in females compatible with the Lyon hypothesis.* Oral Surg Oral Med Oral Pathol. 1967 Feb; 23(2): 174-82.
9. Witkop C J, Kuhlmann W, Sauk J. *Autosomal Recessive Pigmented Hypomaturation Amelogenesis Imperfecta. Report of a Kindred.* Oral Surg Oral Med Oral Pathol 1973; 36 (3), 367-382.

10. Haug RH, Ferguson FS. *X-linked recessive hypomaturation amelogenesis imperfecta: report of case*. J Am Dent Assoc. 1981 Jun; 102(6): 865-7.
11. Seow WK. *Clinical diagnosis and management strategies of amelogenesis imperfecta variants*. Pediatr Dent. 1993 Nov-Dec; 15(6): 384-93.
12. Seow WK. *Clinical diagnosis and management strategies of amelogenesis imperfecta variants*. Pediatr Dent. 1993 Nov-Dec; 15(6): 384-93.
13. Coffield KD, Phillips C, Brady M, Roberts MW, Strauss RP, Wright JT. *The psychosocial impact of developmental dental defects in people with hereditary amelogenesis imperfecta*. J Am Dent Assoc. 2005 May; 136(5): 620-30.