

## Case Report

# Hollow Denture: Prosthodontic Rehabilitation for Acquired Partial Maxillary Ridge defect –A case report

**Ketan Sapariya<sup>1</sup>, Pritesh Vora<sup>2</sup>, Bhagyashri Bhalani<sup>3</sup>, Sameer Chauhan<sup>4</sup>, Rajesh Sethuraman<sup>5</sup>,  
Kavita Gupta<sup>6</sup>**

<sup>1,2,3,4</sup> Post graduate student, Department of Prosthodontics, K. M. Shah Dental College Sumandeep Vidyapeeth, Piparia, Waghodia, Vadodara, Gujarat

<sup>5</sup> Professor & Head, Department of Prosthodontics, K.M. Shah Dental College, Sumandeep Vidyapeeth, Piparia, Waghodia, Vadodara, Gujarat

<sup>6</sup> Reader, Department of Prosthodontics, K. M. Shah Dental College .Sumandeep Vidyapeeth, Piparia, Waghodia, Vadodara, Gujarat

### ARTICLE INFO



#### Keywords:

Maxillectomy, Nasopharyngeal  
angiofibroma, hollow denture, Interim  
obturator

### ABSTRACT

Maxillectomy, the partial or total removal of the maxilla in patients suffering from benign or malignant neoplasms, creates a challenging defect for maxillofacial prosthodontist. In general, there is reduced capacity for remaining teeth and tissue to provide optimal cross arch support, stability and retention. Heavy weight of prosthesis is often a dislocating factor. This present article is case report of prosthetic rehabilitation of compromised Aramany class IV defect with an interim light weight hollow bulb prosthesis for a patient suffering from Nasopharyngeal Angio-fibroma and who has undergone surgical partial maxillectomy in right maxillary region operated before 20 days.

### Introduction

Nasopharyngeal angiofibroma is a rare, highly vascular, benign, locally aggressive tumor, commonly affecting boys of adolescent age. Friedberg first used the term angiofibroma in 1940<sup>1</sup>. The classic triad of epistaxis, unilateral nasal obstruction, and a mass in the nasopharynx suggests a diagnosis of nasopharyngeal angiofibroma and is supplemented by imaging<sup>2</sup>. Examinations such as computed tomography, nuclear magnetic resonance and even nasal endoscopy can clearly establish the extent of the tumor, its pattern of spread, and consequently, surgical planning. A biopsy is recommended only in cases of diagnostic uncertainty. Pathologically, it is characterized by haphazardly arranged vascular

channels surrounded by dense paucicellular fibrous tissue. The condition is most commonly treated by surgical excision and surgical approach is chosen according to the disease stage. Radiotherapy is usually reserved to patients with intracranial extension of disease where complete surgical excision may not be possible<sup>3</sup>.

Patients undergoing surgery alone without closure or obturation of the surgical defect face numerous problems in phonetics and mastication, in addition to the functional deficit, there is a marked effect on aesthetics without the presence of a prosthesis. Basic prosthodontic principles should be followed during the fabrication of prosthesis, while taking extreme care of resilient and unsupported

\* Corresponding author: Dr.Ketan H. Sapariya, Post graduate student, Department of Prosthodontics, Crown and Bridge, K. M. Shah Dental College and Hospital, Sumandeep Vidyapeeth, Vadodara, Gujarat. +91-8141929466 ketan.h.sapariya@gmail.com

tissues. The defect, in conjunction with the remaining structures should be used to provide retention, stability and support to the prosthesis. Thus the prosthesis itself, which may be both bulky and heavy, places considerable stress on the abutment teeth. Heavy weight of prosthesis is often a dislocating factor. This can be achieved by making the prosthesis as light as possible<sup>4,5</sup>.

In the present case report a compromised Aramany<sup>6</sup>class IV maxillectomy defect was treated with an interim hollow bulb obturator.

### Case Report

A 22 year old female patient reported to the Department of Prosthodontics in K.M.Shah Dental College, SV. With chief complains of swelling in right side of face associated with nasal block since 12 months and bleeding and pus discharge from right nostril since 1 week. The patient treatment report revealed that she was suffering from nasopharyngeal angiofibroma of maxillary right alveolar ridge extending from 18 to 21 regions. CT scan images and histopathology reports confirms diagnosis (Fig 1). CT scan revealed bony expansion of 4.3×3.7×3.7 cms involving right maxillary sinus associated central soft tissue, component extension 'vide supra' likely neoplastic activity, which was confirmed by histopathology report. It shows thin walled vessels of varying caliber in a mature connective tissue dense stroma.

The tumor was operated upon 20 days ago in the Department of Oral and Maxillofacial Surgery K.M. Shah Dental College, SV and then referred to Department of Prosthodontics for rehabilitation.

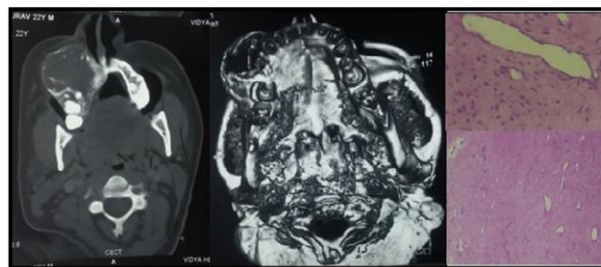


Fig 1: Computed tomography and Histopathology report of patient with nasopharyngeal angiofibroma

On intraoral examination, Class IV Aramany maxillectomy defect was found on the right side associated with depressed cheek, nasolabial fold, and lack of lip support. OPG shows loss of bone support in right maxillary region (Fig.2).The patient was rehabilitated with an interim hollow bulb prosthesis for period of approximately 6 months and later will be replaced by definitive prosthesis replacing teeth 17 to 21.

### Procedure:

Maxillary and mandibular impressions were made using irreversible hydrocolloid (DPI, Imprint).

The impressions were poured using ADA type III gypsum dental stone (Neelkanth, Jodhpur,India).

A custom made acrylic special tray was fabricated and border moulding was done with low fusing greenstick compound. Tray adhesive (Medicept) was applied over custom tray before final impression.

The final impression was taken with PVS material light body (Honigum-DMG America). The Master cast was then poured with Die stone (Neelkanth, Jodhpur,India)(fig.3)

Wax occlusal rim was made and jaw relation was recorded and trial of the waxed-up Prosthesis was done (Fig.4). Wrought wire circumferential was made on tooth number 22 and 27 to minimize horizontal forces on abutment. And buccal surface of all remaining abutment teeth was also covered to enhance additional

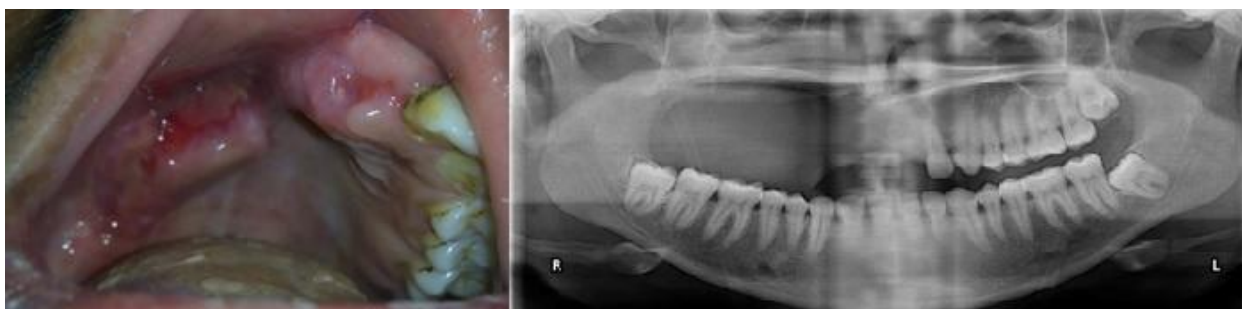

Fig 2: Right sided maxillectomy clinically and radiographically (OPG)

retention from abutment teeth. The bulb was extended in to the ridge area to make it to bulge in zygomatic buttress area to restore the lost support. Once satisfactory esthetic and phonetics was achieved, the prosthesis was processed.

In order to make a lightweight prosthesis, hollowing of the prosthesis was done. After Dewaxing (Fig.5), piece of modelling wax was adapted over defect area with 3 stops, then thin plate of self-cure acrylic resin (DPI) was made over wax sheet (Fig.6). A PVS putty was placed in to acrylic plate and flask was closed (Fig.7). After setting of putty it was trimmed and highpoints was removed. Then another half of acrylic shim was made over putty, and then putty was removed and both half of acrylic shim was joined together with cold-cure acrylic resin. The shim was placed in to water container to verify that it is hollow floating shim (Fig.8).

Then packing was done along with shim placed over defect ridge area with crosslinked high strength PMMA resin (Lucitone-Dentsply) and curing was done (Fig.9).

The prosthesis was finished and polished and insertion was done. It was again verified as hollow denture by placing it in water container as it floats in water (Fig.10). After insertion of prosthesis, post-operative

oral hygiene and denture hygiene instructions was given to patient.

### Discussion

Nasopharyngeal angiofibroma is a classical example of a benign vascular tumor which is slow growing, locally aggressive in nature. A clinical triad of unilateral nasal obstruction, recurrent spontaneous epistaxis and nasal drainage is diagnostic criteria of nasopharyngeal angiofibroma. Various treatment modalities like cryotherapy, sclerosing therapy, hormonal treatment, radiotherapy, chemotherapy, embolization and surgery are used to treat nasopharyngeal angiofibroma now a days<sup>7,8</sup>.

Post-surgical management of patient creates a challenging defect for maxillofacial prosthodontist as patients experiences difficulties in mastication, phonetics, and deglutition. In general, there is reduced capacity for residual teeth and tissue to provide optimal cross arch support, stability and retention. The patient presented here, long span defect was present on right side of maxilla with presence of left side of teeth. Remaining all teeth was used as abutment by using heat cure resin extension on buccal region of remaining teeth. Wrought wire circumferential clasps were incorporated to minimize the horizontal forces acting on the abutments. In addition a cervically

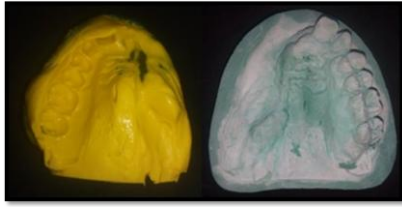


Fig.3: Polyvinyl siloxane final impression and master cast

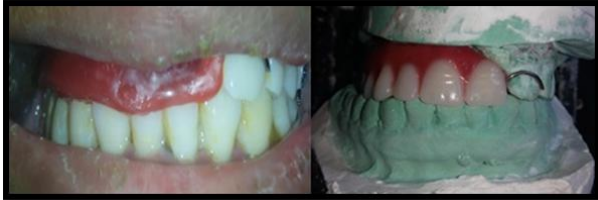

Fig.4: Jaw relation record and trial denture



Fig.5 : After dewaxing

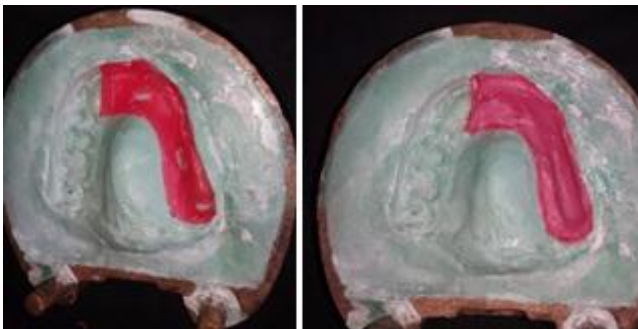


Fig.6:Modeling wax adaptation on defect region with stoppers and acrylic plate

scalloped acrylic buccal flange was designed around teeth of contralateral side of the defect to provide improved retention.

The prosthesis was made hollow with the main objective to minimize the weight. Light weight had also been considered for maxillary resection prosthesis by Chalian and Barnett in 1972<sup>9</sup>, they explained a




Fig.7: Silicone putty and Acrylic shim fabrication

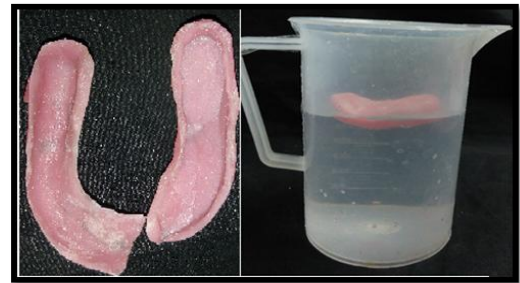

Fig.8: Hollow acrylic shim after removal of putty and two parts joined together and verified in water jar

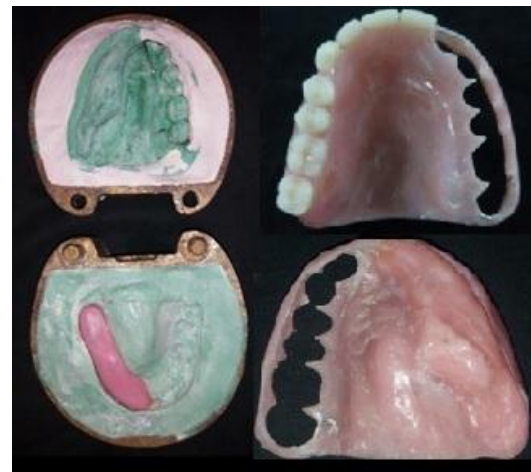

Fig.9: Final packing with Heat cure acrylic along with hollow shim and finished polished hollow floating denture

simple technique for fabricating a single-piece, hollow obturator prosthesis. Tanaka et al in 1977<sup>9</sup> simplified the fabrication process for a lightweight obturator, Holt R.A.1981<sup>10</sup> using silicone putty and Worley and Kniejski 1983<sup>9</sup> described a method for the fabrication of a closed hollow obturator while controlling the thickness of the hollow portion<sup>5</sup>. However in our case we have used a method that combined the putty technique of Holt R.A.<sup>10</sup> and the hollow shim technique of Kniejski et al.<sup>9</sup> These original

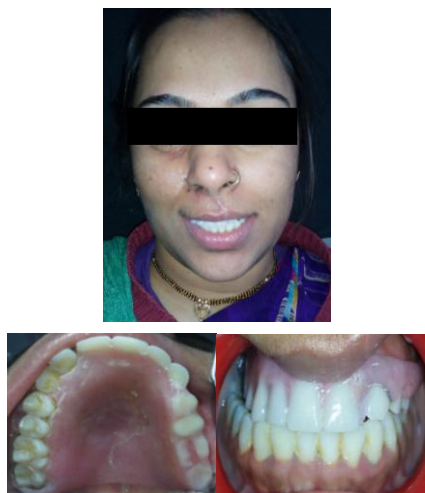

Fig.10: Placement of prosthesis intra-orally

technique had the disadvantage of removal of putty or salt through making a large access hole in prosthesis and acrylic shim which was to be sealed with autopolymerising resin. So in this combined technique we removed putty at stage of packing and hollow shim was placed over defect and heat cure acrylic packing was done covering the hollow shim. This was found to be more advantageous with favorable results of hollowness and non-exposure of acrylic resin towards fitting or polished surfaces of the prosthesis.

In the present case, an interim obturator was constructed. Periodic relines impressions and/ or definitive obturators will be required to accommodate tissue changes after healing is completed. Patient accommodation is usually slow and difficult, after the initial obturator has been provided. Additional procedures should be spaced after 3-6 months apart. The patient should be informed that the interim prosthesis is a functional and esthetic compromise that has functional and retention as limitations. A more definitive prosthesis can address to these limitations.

## CONCLUSION

Maxillofacial defects are highly individual and require the clinician to call upon all his knowledge and experience to fabricate a functional prosthesis. A simplified technical approach for the treatment of a patient with palatal defect of and other supportive structure has been presented. The technique presented offers a method of obtaining a detailed impression of the defect and promptly provides the patient with a light weight, easy-to-use and flexible tissue-tolerant obturator. The procedure was carried out giving utmost importance to functional, psychological & esthetic needs of the patient.

## ACKNOWLEDGEMENT

Department of Oral and Maxillofacial surgery, K.M. Shah Dental College and Hospital, SV, for Surgical Support.

## REFERENCES

1. Friedberg SA (1940) Vascular fibroma of the nasopharynx (nasopharyngeal fibroma). Arch Otolaryngol 31:313–326
2. Marshall AH, Bradley PJ. Management dilemmas in the treatment and follow-up of advanced juvenile nasopharyngeal Angiofibroma. ORL J Otorhinolaryngol Relat Spec 2006;68:273-8.
3. Moorthy PNS, Reddy BR, Qaiyum HA, Srivalli M, Srikanth K (2010) Management of juvenile nasopharyngeal angiofibroma: a five year retrospective study. Indian J Otolaryngol Head Neck Surg 62(4):390–394
4. Thota KK, Tella S, Anulekha A, et al. A Prosthodontic Rehabilitation of a Partial Maxillectomy Patient with Hollow Bulb

- Obturator. Indian Journal of Dental Advancements 2010;2(4):383-6.
5. Reddy KN, Aparna IN, Hegde V. Rehabilitation of a compromised maxillectomy defect with a definitive hollow bulb obturator. J Indian Prosthodontic Soc. 2008 Oct 1;8(4):221-4.
  6. Aramany M.A: Basic principles of obturator design for partially edentulous patients. Part I: Classification. J Prosthet Dent 1978; 40:351.
  7. Martins MB, Lima FV, Mendoca CA, Jesus EP. Nasopharyngeal Angiofibroma: Our experience and literature review. Int Arch Otorhinolaryngol. 2013;17:14-9.
  8. Janaki MG, Nimala S, Rajeev AG. Nasopharyngeal angiofibroma treated with radiotherapy. J Cancer Res Ther. 2007;3(2):100-1.
  9. G Anne et al. Wispy Prosthesis: A Novel Method in Denture Weight Reduction. J Clin Diagn Res. 2016 Apr;10(4):ZC31-4.
  10. Holt RA. A hollow complete lower denture. J Prosthet Dent. 1981;45(4):452-54.