

Case Report

Modified Circummandibular wiring technique in the management of displaced pediatric mandibular parasymphysis fracture -An alternative to bone awl -A Case Report

Veena Shivanna¹, Shashidhara Kamath K², Manjunath K S³, Arun P Devakar⁴

¹ Assistant professor, Department of Pedodontics, Sri Hasanamba Dental College And Hospital, Vidyanagar, Hassan

² Reader, Department of Oral and maxillofacial surgery, Sri Hasanamba Dental College And Hospital, Vidyanagar, Hassan

³ Professor and Head, Department of Oral and Maxillofacial Surgery, Sri Hasanamba Dental College And Hospital, Vidyanagar, Hassan

⁴ Post graduate student, Department of Oral and Maxillofacial Surgery, Sri Hasanamba Dental College And Hospital, Vidyanagar, Hassan

ARTICLE INFO



Keywords:

Mandibular fractures, parasymphyseal fracture, osteogenic, Circummandibular wiring

ABSTRACT

Mandibular fractures in children are rare due to thick adipose tissue, resiliency of bone, protective and care taking nature of the parents.¹ These fractures occur due to different etiology including self fall, or trauma.²The treatment options are controversial as any surgical intervention in young children may misguide the jaw growth or may even cause damage to the developing young permanent teeth. More conservative approaches are opted due to anatomic complexity and the high osteogenic potential of the mandible in growing children.³ This case report documents one such modification of treatment objective of mandibular parasymphyseal fracture in a 9 year old boy.

Introduction

Facial injuries are the most alarming situations in pediatric patients. While facial fractures in pediatric population compromise less than 15% of overall facial fractures in the general population, mandibular fractures are among the most common in pediatric patients. The incidence of mandibular fracture in children ranges from 0.6% to 1.2%.The most typical causes of fracture in children were fall(64%),traffic incidents(22%),and sports-related accidents(9%).⁴The treatment options for the traumatic injuries in pediatric patients is controversial as any surgical intervention in children may even cause damage to the developing

young permanent teeth. Treatment of mandibular fractures in children depends on the fracture site and the stage of skeletal and dental development displaced mandibular fractures need to be reduced and immobilized.⁵Various modifications are done for closed reduction of parasymphyseal fractures of mandible. This article reveals one such modification.

Case Report

A 9 yr old boy by name sagar reported to the department of Pedodontics and Preventive dentistry Sri Hasanamba dental college and hospital, Hassan with a chief complaint of pain in lower jaw. History

* Corresponding author: *Dr. Veena Shivanna Assistant professor Department of Pedodontics Sri Hasanamba dental college and hospital Vidyanagar, Hassan*

revealed fall from auto previous day evening. There was a history of bleeding intraorally for which the

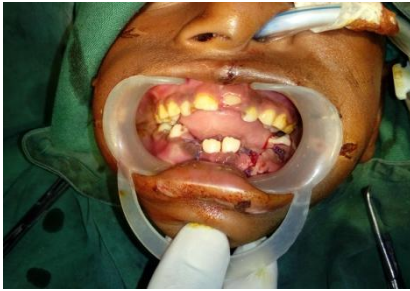

Fig -1 preoperative

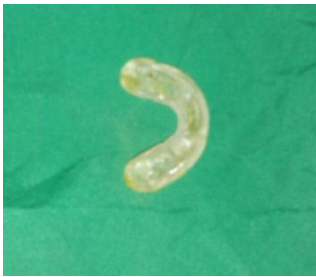

Fig-2

patient had consulted local hospital and primary sutures were placed. Patient was conscious, well oriented to time, place and person but he was uncooperative. There was no history of convulsions, vomiting and bleeding from ear and nose. The patient's medical history was noncontributory, and he was not under any medication.

Extraoral examination revealed asymmetry due to diffused facial oedema. There was limited mouth opening because of pain and possible muscle spasm. Abrasion wound on right side of the face in mild swelling seen over right cheek region and lower lip. Step defect and tenderness present with respect to right parasymphysis region. Tenderness also present with respect to left preauricular region. On Intraoral examination, sutures were placed in the labial vestibule with respect to 42, 43, 32, 33 region. Step defect and tenderness present with respect to left parasymphysis region.

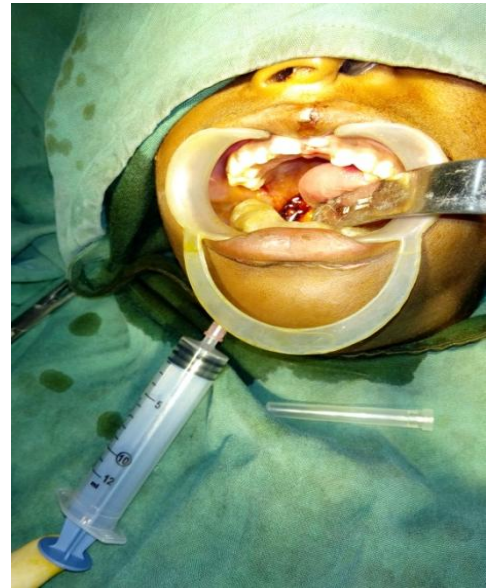


Fig -3 using 18 gauge needle for wire insertion

Mobility evident w.r.t the fractured segments in the right parasymphysis region. Occlusion was not satisfactory on both the sides. Avulsion seen wrt 72, 73 82, 83. Periosteal breach seen irt 83, 84 region. Tongue laceration seen in middle third of tongue. (Fig 1) Radiological examination revealed fracture line running wrt right parasymphysis region between 32 and 33.

Management

Impressions of both arches were made with alginate impression material under diazepam oral sedation. An acrylic cap splint was the constructed on the model of the patient's arches after reducing the fracture on the models. (Fig 2) For reinforcement, a stainlesssteel wire of 26 gauge was incorporated in the splint for additional strength .Under strict aseptic conditions, patient was intubated with nasotracheal tube no. 6 and anaesthesia was achieved. Site was prepared and drapping was done in the usual manner. The dislocated segments were reduced by bidigital pressure and were

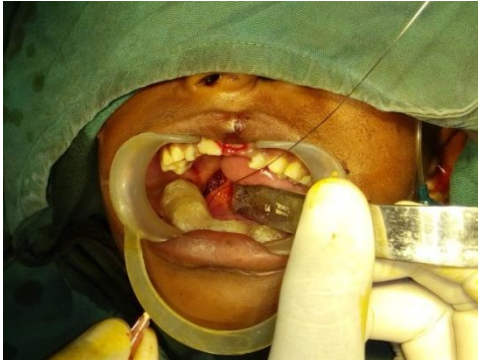


Fig -4

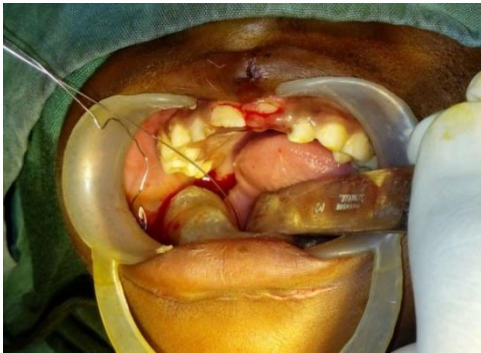

Fig -5

stabilized using bridle wire between the fractured segments. Cap splint was then positioned wrt the lower arch. 18 gauge needle was passed extraorally from below the lower border of the mandible wrt 83 and 84 region on to the lingual side of the oral cavity.(Fig 3) From cannula of needle 26 gauge stainless steel wire was passed and cannula was then removed. Now one end of 26 gauge wire was outside and another lingually. (Fig 4)Then the needle was reinserted intraorally through the buccal vestibule and taken out through the same point extraorally.(Fig 5) Then the wire end already present extraorally was reinserted into the needle and taken out on to the buccal side. The same procedure was done on the opposite side molar region and also in central incisor region. (Fig 6) Postoperative antibiotic treatment was started for 1week. Soft diet, avoidance of physical activities, and antibacterial mouth rinse were prescribed.

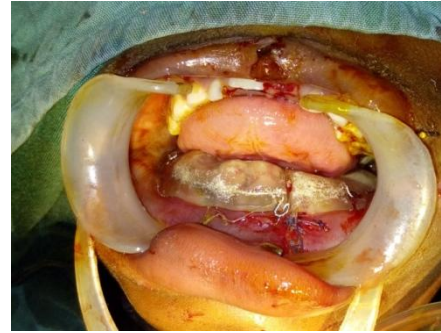

Fig -6 post operative

Postoperative monitoring was performed on a weekly basis and was favorable in both healing and function. No signs of complications were observed during the healing period.

Discussion

Fractures of the pediatric facial skeleton have special characteristics, and specific knowledge is necessary for their diagnosis, management, and follow-up. To understand the differences between pediatric and adult facial fracture patterns, a familiarity with the processes of facial growth and development is essential. Facial growth, paranasal sinus development, dentition, and bone structure all affect the pattern of facial fractures in children⁶. The areas of pediatric mandible that are most frequently fractured are in condyles, subcondylar, and angle regions (80%), and the symphysis/parasymphyseal area (15% to 20%) fractures of the body of the mandible are rare in pediatric population⁷. Factors to be considered in the definitive treatment of the dento-alveolar injury include (1) age and cooperation of the patient; (2) duration between trauma and treatment; (3) location or extent of the injury; (4) injury to primary or permanent dentition; (5) stages of root development; (6) presence of fracture of supporting bone; and (7) periodontal health of remaining teeth(10)⁸Among the commonly used treatment options, acrylic cap splints are ideal. They avail support not only from the adjacent teeth but

also from bone. They are easy to fabricate and are economical. Routinely, they are used in stabilizing mandibular fractures, as they can be stabilised by the use of circum-mandibular wire. Conventionally, circummandibular wiring is performed with a mandibular awl, but the wound created when using a spinal needle is inconspicuous compared with that created when using an awl. When the awl travels through the tissue, with the wire crimped, the twisted end of the wire causes trauma to the surrounding soft tissue because of its sharpness and thickness. Repeated use of an awl causes it to lose its sharpness. When using an awl, the crimped wire, which is potentially contaminated by oral fluids, is made to pass around the mandible. Using spinal needle the section of wire exposed to the oral cavity never touches the tissue, but the tip of the needle is exposed to the oral cavity and enters the tissue. Fracture healing was uneventful and complications such as postoperative swelling and haematoma were not observed⁹. This was a displaced fracture rarely seen in children with both the fracture segments separated and mobility in both the fracture segments on bimanual manipulation. This technique provided efficient stability and patient tolerated the treatment well. According to the extensive literature search, there are a limited number of articles regarding treatment of pediatric mandibular fracture with fixation of the splint by circummandibular wires.¹⁰ Although this treatment involved minimal operative manipulation, the technique should be applied by an experienced surgeon only.

Conclusion

The majority of mandibular fractures can be managed conservatively in children. While the basic principles for mandibular fracture treatment are the same as for

the adult, certain anatomical features of the pediatric mandible warrant special attention. For the proper treatment, mixed dentition, unerupted teeth, the shapes of teeth and ongoing growth in the mandible should be carefully considered. Although there is no clear consensus about the optimal method for fixation of mandibular fractures; effective, simplest and less invasive method is the best method. The results of the fractured treatment presented in this case report verified the usefulness of modified technique of horizontal stabilization along with circummandibular wiring using cap splint in case of parasymphysis fracture.

References

1. Sardana D, Gauba K, Goyal A, Rattan V. Comprehensive management of pediatric mandibular fracture caused by an unusual etiology. *Afr J Trauma* 2014;3:39-42
2. Singh et al. Open cap splint fixation with circummandibular wiring still best method in management of pediatric mandibular fracture. www.journalofdentofacialsciences.com, 2014; 3(4):55-58
3. Duddu MK, Muppa R, Bhupatiraju P, Dandempally A. Cap Splint –A definitive Treatment Modality for pediatric mandibular fractures-A case report. *Indian journal of dental sciences*.2012;5(4)
4. A case report. Jain p, Yeluri R, gupta S, Lumbini P. Management of pediatric mandibular parasymphyseal fracture with acrylic closed cap splint: *Annals of dental speciality* 2015 : 3 (1).
5. Khairwa A, Bhat M, Sharma A, Sharma R. Management of Symphysis and parasymphysis mandibular fractures in children treated with MacLennan splint: Stability and Early results *Int J Clin Pediatr Dent* 2015;8(2): 127-132.
6. Alcalá-Galiano A, Arribas-García JJ, Martín-Pérez MA, Romance A, Montalvo-Moreno JJ, Juncos JMM. Pediatric Facial Fractures: Children Are Not Just Small Adults. *Radiographics* 2008; 28: 441-461.
7. A. Baumann, M. J. Troulis, and L. B. Kaban, "Facial trauma II. Dentoalveolar injuries and mandibular fractures," in *Pediatric Oral and Maxillofacial Surgery*, pp. 445–461, Saunders, Philadelphia, Pa, USA, 2004.
8. G. H. Blakey III, R. L. Ruiz, and T. A. Tuarey, "Management of facial fractures in growing patient," in *Oral and Maxillofacial Trauma and Endodontics*, R. J. Fonseca and R. V. Walker, Eds., vol. 2, pp. 1003–1041, WB Saunders, Philadelphia, Pa, USA, 1997.
9. S. Thomas, V. Yuvaraj: Atraumatic placement of circummandibular wires: A technical note. *Int. J. Oral Maxillofac. Surg.* 2010; 39: 83–85.
10. Sodhi SPS, Brar G, Brar RS, Bhardwaj J, Jain A. Modified Circummandibular Wiring Fixation Using Acrylic Splint For The Treatment Of Displaced Mandibular Parasymphysis Fracture: A Case Report. *J Stomatognathic Sci* 2015; 5(1):10-13.