

## Case Report

# Prosthodontic Management of Ectodermal Dysplasia Patient With an Overdenture -A Case Report.

**D.R.Prithviraj<sup>1</sup>, S.K.Vishwanath<sup>2</sup>, K.Sounder Raj<sup>3</sup>, Akash Patel<sup>4</sup>, Shruti Saraswat<sup>5</sup>**

<sup>1</sup> Dean cum Director, Government Dental College and Research Institute, Bangalore

<sup>2</sup> Associate professor, Department of Prosthodontics, Government Dental College and Research Institute, Bangalore

<sup>3</sup> Head of Department, Department of Prosthodontics, Government Dental College and Research Institute, Bangalore.

<sup>4,5</sup> Post graduate Student, Government Dental College and Research Institute, Bangalore

### ARTICLE INFO



#### Keywords:

Ectodermal dysplasia, Prosthetic rehabilitation, Overdenture, Hypodontia, removable prosthesis.

### ABSTRACT

Ectodermal dysplasia is a hereditary disorder associated with abnormal development of embryonic ectodermally-derived organs including teeth, nails, hair and sweat glands. Affected patients need dental prosthetic treatments during their developmental years. This clinical report describes the prosthetic rehabilitation of a 13-year-old girl with ectodermal dysplasia. Oral rehabilitation was accomplished with removable acrylic prostheses. Treatment had major impacts on self-esteem, masticatory function, speech and facial esthetic.

### Introduction

Ectodermal dysplasia (ED) is a large, heterogeneous group of inherited disorders that are characterized by primary defects in the development of two or more tissues derived from the embryonic ectoderm. ED has been related to more than 170 genetic syndromes and occurs in approximately 1 in 100,000 live births. The syndrome involves overlapping features, thereby complicating a definitive classification. According to the state of sweat glands involvement, two major groups are distinguished: (1) Hypo-hidrotic or anhydrotic (Christ-Siemens-Touriane syndrome) in which sweat glands are either absent or significantly reduced in number; (2) Hydrotic

(Clouston syndrome) in which sweat glands are normal. Dentition and hair are involved similarly in both types but hereditary patterns of nails and sweat glands involvement are different. Hydrotic ectodermal dysplasia has an autosomal dominant inheritance and Hypohidrotic ectodermal dysplasia (HED) has an X-linked recessive inheritance and is the most common form of ED syndrome affecting men more severely and frequently<sup>1</sup>.

Patients with HED have absent or decreased sweating because of lack of sweat glands producing extremely high fevers because their skin cannot control temperature properly. The skin is thin with light colouring. Hair may be absent or very thin. After puberty hair growth improves in

\* Corresponding author: *Dr.Akash Patel, 12/harivilla bungalows, Nr J.K.park, Gota road, chandlodia, Ahmedabad. Gujarat-382481.*  
E-mail: [akash25490@gmail.com](mailto:akash25490@gmail.com) Mobile no: 9904523067, 8105695858.

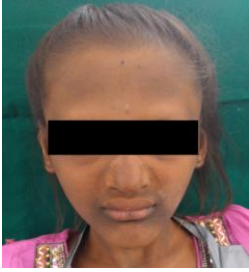

Figure 1: Pre-operative Frontal view

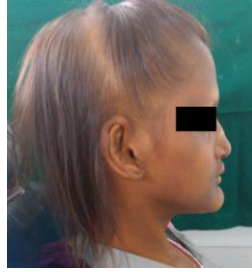

Figure 2: Pre-operative Lateral view

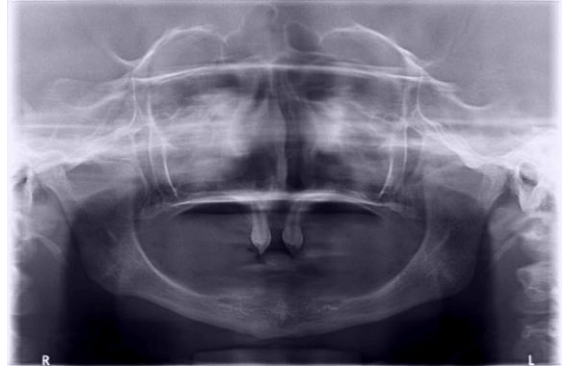


Figure 4: Orthopantomogram.

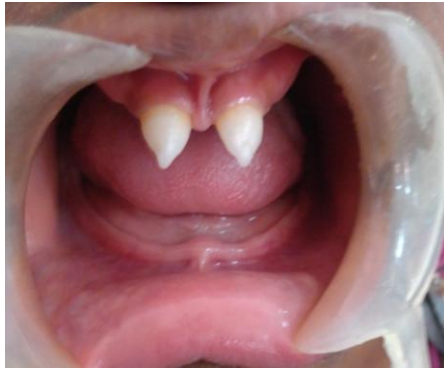

Figure 3: Pre-operative Intraoral view

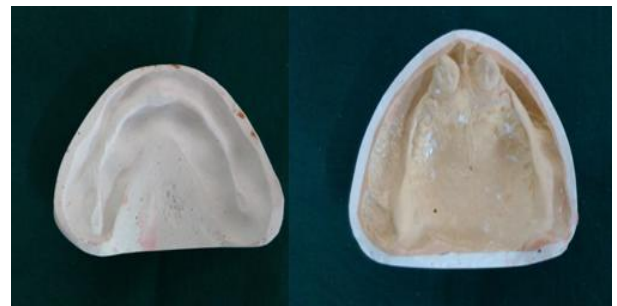

Figure 5: Primary Casts obtained from Alginate impression

some patients. The eyebrows, eyelashes, and other body hair may also be absent or sparse. Fingernails and toe nails may show faulty development and be small, thick or thin, brittle, discolored, cracked, and/or ridged. Extraoral manifestations include frontal bossing, depressed nasal bridge, protuberant lips, and hypotrichosis.

The dental characteristics include anodontia or hypodontia of the primary and/or permanent teeth, hypoplastic conical teeth, and underdevelopment of the alveolar ridges.<sup>3,4</sup> When teeth are missing the alveolar bone in which they are ordinarily embedded does not develop well, leading to a reduced vertical dimension and a typical aged appearance in the face.<sup>5,6</sup> The deviation from normal facial growth of HED subjects tends to lessen with age when rehabilitated with functional and prosthetic appliances<sup>7</sup>. The Prosthodontic

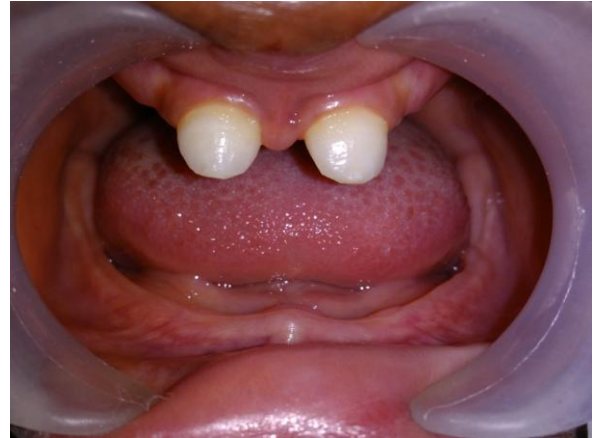

Figure 6: Sharp conical tips were reduced  
 rehabilitation of ED patients must be on an individual basis, considering each patient's growth and developmental characteristics. Many treatment approaches have been reported and may include single crowns, fixed partial dentures (FPD), complete dentures (CD), removable partial dentures

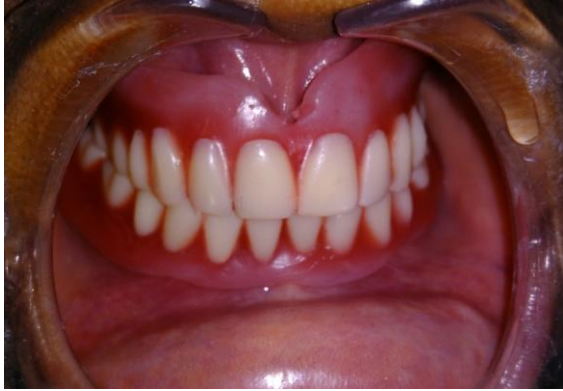

Figure 7: Trial Denture

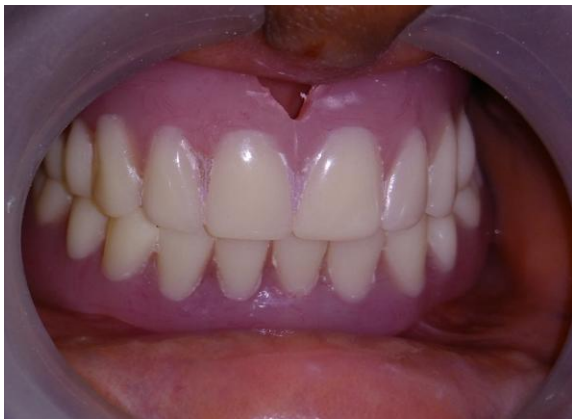

Figure 8: Final Prosthesis

(RPD), overdentures (OD), and implant retained prostheses. A removable prosthesis is often the treatment of choice for young patients with ED.<sup>9</sup> This article presents the early prosthetic rehabilitation for a child with hereditary ectodermal dysplasia associated with severe oligodontia in primary and permanent dentition.

### Case Report

A 13-year-old girl came to department of prosthodontics, GDCRI Bangalore with chief complaint of inability to masticate and unesthetic appearance. She desired replacement of her missing teeth. The patient gave history of lack of sweating, dryness of skin, and raised body temperature. Extraoral examination revealed sparse hair, frontal bossing, depressed nasal bridge,



Figure 9: Post-operative Frontal view

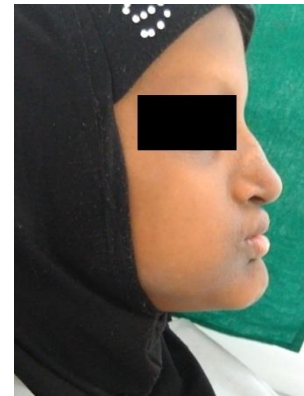

Figure 10: Post-operative Lateral view

prominent supra orbital ridges, sunken cheeks, hyperpigmented skin around the eyes, protuberant lips, and decreased lower facial height. Nails appeared normal.

Intraoral examination revealed cone-shaped teeth were present in 11 and 21 region with underdeveloped complete edentulous mandibular alveolar ridge. There was reduced vertical bone height and loss of vestibular depth in the lower jaw. According to the history given by patient's father, only two permanent teeth were erupted after the exfoliation of the respective deciduous teeth. The radiographic findings also confirmed the clinical diagnosis. OPG revealed absence of other teeth bud and open apices in relation with 11 and 21.

Treatment plan included making complete over-denture for the upper and lower jaws to improve appearance, function and speech. Primary impressions were made with irreversible hydrocolloid impression material as it is comfortable and can be easily removed from undercut area. Casts were prepared with type III dental stone. Teeth were modified and sharp conical tips were reduced. Custom trays were prepared, and border moulding was done with green stick compound material. The final impressions of the maxillary and mandibular arches were made with zinc oxide eugenol paste. Maxillo-mandibular relation was recorded using temporary base and wax rim, and the master casts were mounted on the articulator. Monoplane teeth were selected and arranged. Try-in was done. After laboratory processing, the over-dentures were delivered to the patient. Prosthetic rehabilitation significantly improved the patient's appearance, masticatory efficiency, speech, and swallowing. The young girl tolerated the CD very well. Maintenance, aspiration precautions, and oral hygiene instructions were given to the patient and her parents. The patient has been advised for fluoride varnish application (every 6 months) and adjustments of the CD.

### **Discussion**

Oral rehabilitation of patients with ectodermal dysplasia is necessary to improve sagittal and vertical skeletal relationships during craniofacial growth and development as well as esthetics, speech, and masticatory efficiency.<sup>1</sup> The most common treatment plan is removable prosthesis. Implant-supported denture is also suggested as the ideal reconstruction modality for adolescents over

18 years. When implant therapy is indicated, the main problem is insufficient bone; if bone atrophy progresses in these already alveolar deficient patients, implant placement may not be possible without bone grafting.<sup>11</sup> In this case implant therapy was not the treatment choice due to ongoing growth and development and insufficient alveolar bone support.

Early prosthetic treatment is generally recommended from the age of 5 years. With regard to child cooperation, dentures can also be fabricated as early as 3 to 4 years of age. Positive effects include more self-confidence, facial esthetics, speech and masticatory function improvement.

However, removable partial or complete dentures require regular adjustments and should be replaced when a decreased vertical dimension of occlusion and an abnormal mandibular posture are detected due to growth. Retention and stability for the prostheses are also difficult to obtain. The dryness of the oral mucosa, immature maxillary tuberosities and under-developed alveolar ridges cause difficulty in obtaining adequate retention and stability of the complete denture. This can be counteracted by the impression technique, occlusal scheme, ensuring a broad distribution of occlusal load and complete extension of the denture base. Although the atypical conical anterior teeth may not be suitable for removable partial denture stability, they may be used as abutments for overdentures.<sup>10-12</sup>

### **Conclusion**

Management of clinical manifestations associated with ectodermal dysplasia presents a unique challenge for prosthodontists and pedodontists.

Treatment of young edentulous patients with removable partial or complete denture is an acceptable, easily available and cost effective modality, which improves function, speech, esthetics and psychosocial condition. However, its long term success depends on regular recall appointments and meticulous maintenance of oral hygiene.

## References

1. Tarjan, K. Gabris, and N. Rozsa. Early prosthetic treatment of patients with ectodermal dysplasia: a clinical report. *Journal of Prosthetic Dentistry*.2005; 93(5): 419–424.
2. S. A.Wiśniewski, A. Kobiela, W. H. Trzeciak, and K. Kobiela. Recent advances in understanding of the molecular basis of anhidrotic ectodermal dysplasia: discovery of a ligand, ectodysplasin A and its two receptors. *Journal of Applied Genetics*. 2002;43(1): 97–107.
3. Itthagarun and N.M. King. Ectodermal dysplasia: a review and case report. *Quintessence International*. 1997;28(9):595–602.
4. M. A. Pigno, R. B. Blackman, R. J. Cronin Jr., and E. Cavazos. Prosthodontic management of ectodermal dysplasia: a review of the literature. *Journal of Prosthetic Dentistry*. 1996;76(5):541–545.
5. T. J. Vergo. Prosthodontics for pediatric patients with congenital/ developmental orofacial anomalies: a long-term follow-up. *Journal of Prosthetic Dentistry*. 2001;86(4):342–347.
6. J. Hickey and M. Salter. Prosthodontic and psychological factors in treating patients with congenital and craniofacial defects. *Journal of Prosthetic Dentistry*. 2006;95(5):392– 396.
7. Dellavia, F. Catti, C. Sforza, D. G. Tommasi, and V. F. Ferrario. Craniofacial growth in ectodermal dysplasia: an 8 year

- longitudinal evaluation of Italian subjects. *Angle Orthodontist*. 2010;80(4):733–739.
8. J. A. Hobkirk, F. Nohl, B. Bergendal, K. Storhaug, and M. K. Richter. The management of ectodermal dysplasia and severe hypodontia. International conference statements. *Journal of Oral Rehabilitation* 2006; 33(9):634–637.
  9. K. A. Vieira, M. S. Teixeira, C. G. Guirado, and M. B. D. Gavião. Prosthodontic treatment of hypohidrotic ectodermal dysplasia with complete anodontia: case report. *Quintessence International* 2007;38(1):75–80.
  10. Lo Muzio L, Bucci P, Carile F, Riccitiello F, Scotti C, Coc-cia E, et al. Prosthetic rehabilitation of a child affected from anhydrotic ectodermal dysplasia: a case report. *J Contemp Dent Pract* 2005;6:120-6.
  11. Imirzalioglu P, Uckan S, Haydar SG. Surgical and prostho-dontic treatment alternatives for children and adolescents with ectodermal dysplasia: a clinical report. *J Prosthet Dent* 2002;88:569-72.
  12. Somayeh Hekmatfar, Karim Jafari, Raziye Meshki, Samaneh Badakhsh. Dental Management of Ectodermal Dysplasia: Two Clinical Case Reports. *J Dent Res Dent Clin Dent Prospect* 2012; 6(3):108-112.