

Case Report

Esthetic Rehabilitation of a 3 years old patient with mutilated anterior teeth

Shoeb Mujawar¹, Garima Tiwari²

¹ Reader, Department of Pediatric and Preventive Dentistry, ACPM Dental College, Sakri Road, Dhule

² Post-graduate student, Department of Pediatric and Preventive Dentistry, ACPM Dental College, Sakri Road, Dhule

ARTICLE INFO



Keywords:

General Anaesthesia, Rampant caries,
Fibre post in pedodontics.

ABSTRACT

Dental caries has been reported to affect humans since prehistoric times, its prevalence being greatly increased in modern times worldwide; an increase strongly associated with dietary changes. Rampant caries is burrowing in nature with early pulpal involvement and gross destruction affecting most teeth in children. This causes decreased masticatory efficiency, difficulty in speech, compromised esthetics, development of abnormal tongue habits and subsequent malocclusion & psychological problems. It is a challenging task to restore dental health in young children with grossly decayed teeth affected with rampant caries. This case report documents the esthetic rehabilitation of a 3 year old under general anesthesia.

Introduction

General anesthesia is the most effective way of behaviour management in an uncooperative and emotionally immature patient as the other techniques usually fail under these circumstances. Growing awareness among parents has increased the necessity and demand for effective material and technique use for their children.² However, 40% parents of children with incisor lesions indicate a previous awareness of potential cariogenicity. The majority (89%) attempt substitution of water, but in 68% of these cases the child rejects it.³

Pediatric dentists provide oral care and solve dental problems for infants, children, adolescents and young persons with special health care needs. Majority of children can be adequately treated with non-pharmacologic behaviour modification techniques such as tell-show-do technique. However, some children who have extensive dental problems cannot cooperate due to lack of psychological or emotional maturity and/or mental, physical or medical disabilities, and their dental treatment needs to be completed with pharmacological behaviour management, such as nitrous oxide/oxygen sedation or

general anesthesia. This case report describes rehabilitation of a 3 year old patient with rampant caries treated by pulpectomy, fiber post placement & composite build up to restore the normal functions and aesthetics.

CLINICAL CASE REPORT

A 3 year old NRI female patient reported to our institute with the chief complaint of severely decayed upper front teeth. She experienced continuous pain in those teeth. On intra oral examination, crown portions of all upper anterior teeth were grossly destructed. Radiographic examination revealed pulpal involvement with 51, 52, 61, and 62. Treatment of pulpectomy with 51, 52, 61, 62 followed by placement of fiber posts and later composite core build up was planned. In view of the multiple treatment modalities to be undertaken and the less age of the patient, treatment was planned under general anaesthesia.

Parents were explained and informed about the procedure and written informed consent was obtained to carry out the entire treatment under General Anesthesia in a hospital setup. Prior to the

* Corresponding author: *Dr. Garima Tiwari, Mailing address- 68/B, Vaibhav Nagar, Jamnagiri Road, Dhule-424001 (Maharashtra) India, Email address: garimakaid@gmail.com, Mobile Number: 919552192346*

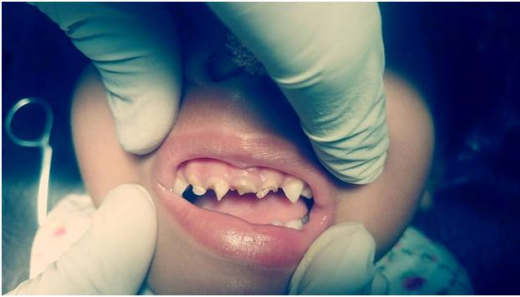

Figure 1-Pre-operative grossly decayed deciduous upper anterior teeth

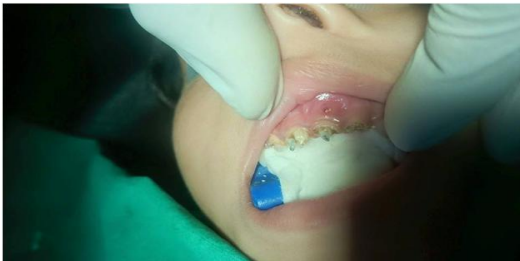

Figure 2- Placement of fibre-posts in the obturated canals.

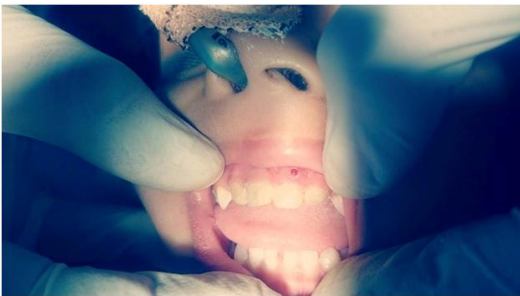

Figure 3- Composite build up of upper anterior teeth

procedure, patient was kept Nil-by-mouth for six hours and intravenous fluids were maintained. The patient was taken under general anaesthesia and intubated through nose. Throat pack was placed and intermittent suction was maintained to prevent aspiration. Access was gained into the root canals of 51, 52, 61 and 62 using arotor handpiece with simultaneous suction. Working length was determined using apex locator. The canals were enlarged till #25 K-file upto the working length. Biomechanical preparation was performed using rotary Ni-Ti files (Protaper system) upto F3 with EDTA and sodium hypochlorite irrigation. The canals were then flushed with normal saline and later copious irrigation was done in the canals using chlorhexidine. Then the canals were dried using absorbent points and obturated with Metapex obturating material. Fiber post was selected to support the restoration as it adapts well to the root canal anatomy. The fibre post which fitted most snugly to the canal wall was selected for each of the teeth. The level of fiber

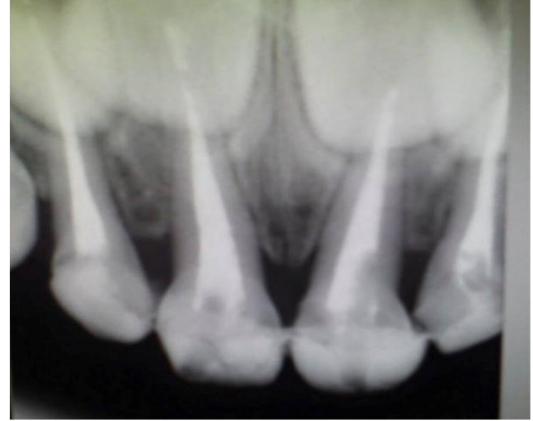


Figure 4- Post-operative radiograph showing Obturation of canals, placement of Fibre posts and Composite Build-up

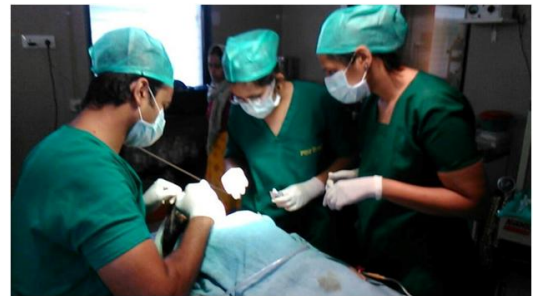

Figure 5- Treatment under General Anaesthesia.

post was kept till the crest of the alveolar bone so that it would exfoliate along with the teeth. The approximate level of fibre post insertion in the canal upto the crest of alveolar bone was verified radiographically pre-operatively. The fibre post was luted using 3M Glass Ionomer luting cement. Core build up was done using 3M light cure Composite resin. The occlusion was checked. After removal of occlusal interferences, final finishing and polishing of the restoration was performed using Shofu Composite polishing kit.

Suction was maintained throughout the procedure. After completion of procedure the throat pack was removed and the child safely extubated. Post operative photograph & IOPA were made to verify the success of the procedure. The patient was admitted in the Day-care for observation. Home care instructions, including oral hygiene measures and diet counseling were given to the parents. Patient was recalled after one week to analyse the pulpal treatment and restoration. The patient and her parents were satisfied with the esthetic rehabilitation.

Clinical and radiographic assessment of the treatment was done after one, three, six and nine months which showed excellent results. The teeth were firm with no discomfort and radiographically, normal

physiologic resorption was noted. All the normal functions of the mouth were restored satisfactorily and the child was happy and confident than ever before.

DISCUSSION

Dental treatment under General Anaesthesia is an expensive treatment and requires skill and perfection. It is a choice of treatment in children who are extremely uncooperative and unable to accept dental treatment on chair, also in the medically compromised patients. The aim of dental treatment under GA is to restore the child's oral health in a single visit allowing behaviour modification methods to be introduced more readily afterwards. In this case report, the teeth were grossly decayed. There was minimal tooth structure to support any restorative build up post-pulpectomy; therefore, use of crowns was not the restoration of choice in this case. Post and Core restoration has been reported to restore tooth structure. Fiber posts and other available options such as threaded posts, nickel-chromium cast post, preformed and cast metal posts have been utilized earlier.⁴ The use of metal post needs the use of an opaque resin to mask the post and could pose additional problems during the course of exfoliation. The advantage of the fiber post over metal is that it does not impart its own color from the composite restoration; easy to manipulate and fits very well in the root canal. Composite does not bond with the metal whereas bonding with the fiber post is quite appreciable. This provides better mechanical retention and support for the restorative material. The use of the fiber post thus, shows optimum benefits in this type of cases; hence was chosen for treatment in this case.

SUMMARY

Procedure carried under GA provides extensive complete oral rehabilitation in a short period of time with immediate relief of pain and restoration of the lost structures.

REFERENCES

1. Enger DJ, Mourino AP. A survey of 200 paediatric dental general anesthesia cases. *J Dent Child* 1985;52:36-41.
2. Johnsen DC. Characteristics and background of children with "nursing caries". *Pediatr Dent* 1982;4:218-24
3. Harrison MG, Roberts GJ. Comprehensive dental treatment of healthy and chronically sick children under intubation general anaesthesia during a 5-year period. *Br Dent J* 1998;184:503-6.
4. El-Bialy WB, Al-Rashid BA, El-Tanani H. Extraction of teeth under general anaesthesia for outpatient children and mentally retarded patients in Kuwait. *Egypt Dent J* 1992;4:257-62.
5. Ripa LW. Nursing Caries: A comprehensive review. *Pediatr Dent* 1988;10:268-82.
6. Mortada A, King NM. A simplified technique for the restoration of severely mutilated primary anterior teeth. *J Clin Pediatr Dent* 2004; 28:187-92.
7. Rifkin A. Composite post crowns in anterior teeth. *J Dent Assoc S Afr* 1983; 38:225-7.
8. Usha M, Deepak V, Venkat S, Gargi M. Treatment of severely mutilated incisors: challenge to the pedodontist. *J Indian Soc Pedod Prevent Dent* 2007;25: S34-6