

Case Report**A Holistic Approach for the Management of Lobular Capillary Haemangioma using ErCr:YSGG Laser****Devashish¹, Vinod Chandel², Nishant Khurana³, Shruti Kanwar⁴**¹ Consultant Paediatric Dentist at Advanced Dental and Medical Care, Chandigarh² Consultant Prosthodontist at Advanced Dental and Medical Care, Chandigarh³ Senior Lecturer, Dept. of Conservative dentistry & Endodontic, PCDS & RC, Bhopal, Madhya Pradesh⁴ Post Graduate student, Dept. of Conservative dentistry & Endodontic, ITS Dental College, Ghaziabad

ARTICLE INFO



Keywords:

ErCr:YSGG, Lobular Capillary Hemangioma, Pyogenic granuloma, Erbium lasers

ABSTRACT

Statement of problem: Lobular Capillary Hemangioma (LCH) is a sessile or pediculate mass with or without ulceration zones. Oral health may be compromised due to problems in oral functions like chewing, swallowing, tongue movements, esthetics and repeated trauma.**Purpose:** In a young patient treatment necessitates a minimally invasive and painless procedure. This case report describes the management of Lobular Capillary Hemangioma using ErCr:YSGG laser in a 15 years old female patient.**Materials and Methods:** The patient presented with a growth on the floor of the mouth on left side which interfered with the tongue movement. The growth was excised using ErCr:YSGG laser.**Results:** Healing post excision was uneventful and painless, within 1 month there was continuity of the mucosa of the floor of the mouth without any sign of recurrence at 1 year follow-up.**Conclusion:** ErCr:YSGG laser excision in a young adolescent is an effective procedure for the management of an intra-oral soft tissue overgrowth.**Introduction**

Lobular Capillary Hemangioma (LCH) also known as Pyogenic Granuloma is a benign lesion characterized by sub-mucous vascular proliferation arranged in lobules and clusters of central capillaries surrounded by smaller ramifying tributaries[1]. The term pyogenic granuloma is a misnomer[1]. It is neither infectious nor granulomatous [1]. LCH is seen as a smooth or lobulated sessile or pediculate mass with or without ulceration zones on the area [2]. It has a higher predilection for females 1.5: 1 ratio and is seen frequently in the second and third decades of life [3,4]. The colour depending on the vascularity of the growth can vary from red, reddish purple to pink [2]. Older lesion may look like fibroma [1]. The gingiva is the

most common site followed by lips, tongue, buccal mucosa and palate [2]. A haemorrhage may occur spontaneously or after a small trauma [5]. The size of the lesion may vary, with the mean size of the lesion being 7.3 mm[6].The final diagnosis is possible only after histopathologic examination. It can be treated by several techniques, steroid therapy, surgical excision, sclerotherapy, curettage, cryotherapy with liquid nitrogen, laser surgery or a combination of methods [4,6-7]. The present case of LCH has been treated using the ErCr:YSGG laser which is a photon liberation based hydrokinetic system in an air-water spray, which causes strong explosions in the water

* Corresponding author: **Dr. Vinod Chandel**, Advanced Dental and Medical Care, SCO-156, 1st floor, Sector 37-C, Chandigarh, Pin - 160036
Email id: vc4173@gmail.com Contact no: +919815131898

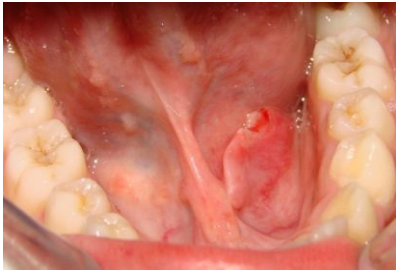

Fig 1: Pre-op intra oral image



Fig 2: Laser settings

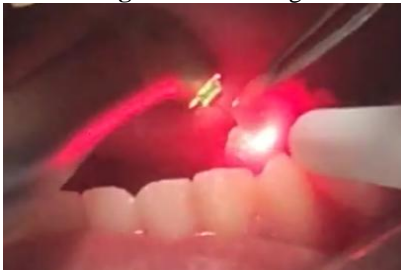

Fig 3: Lesion excision using ErCr:YSGG laser

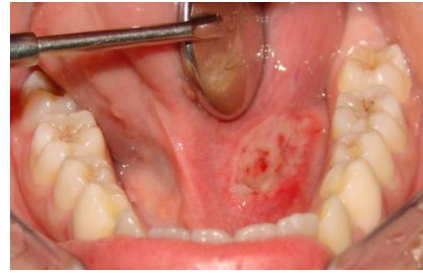

Fig 4: Immediately post-op

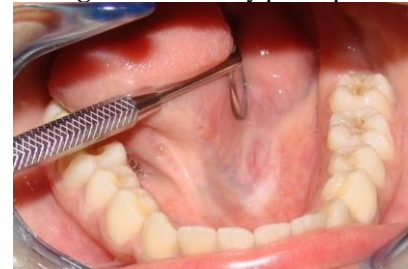

Fig 5: 3 month follow up

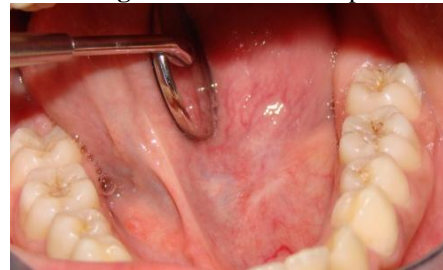


Fig 6: 1 year follow up

droplets. The delivery system is optical fiber based that ends in a sapphire crystal tip. The hand piece is similar to that of a conventional hand piece. Cutting effectiveness is attained when the targeted tissue in the range of 1-1.5 mm from the tip [14].

CASE REPORT

A 15 year-old girl presented to the section of Paediatric dentistry in our clinic with swelling and discomfort on the left side beneath the tongue. The patient noticed it 2 months back and since then it has grown gradually to the present size. There was difficulty during tongue movements. While no difficulty was felt during swallowing and chewing. There was no history of trauma or bleeding from the mouth. Past dental, medical and family histories were

non-contributory. On physical examination, she appeared to be healthy and, with all her vitals being within normal limits. Clinical examination showed the child in permanent dentition with good oral hygiene. A sessile reddish growth of size 7x2mm was noted on the left side of the floor of her mouth (fig 1), covered with normal mucosa, with a small ulceration (1.5 x 1 mm). On palpation, the mass was soft, non-painful with consistently compressible. The growth was localized on the floor of the mouth, above the mylohyoid muscle, not attached to the lower jaw or to any salivary gland.

With the above findings a provisional diagnosis of LCH with a differential diagnosis of irritational fibroma was made and it was then decided to remove the mass with the help of ErCr:YSGG laser (Waterlase

MD technology, Biolase Technology; Cromwell Irvine, CA, USA) . The laser settings for the surgery were 1.75 W, 15% water, 25% air in continuous contact mode (Fig 2). Coagulation was achieved and laser bandaging was done by setting the laser at 0.50 W, 0% water and 0% air using a total of 10 pulses. The mass was completely excised along with a section of the mucosa of the floor of the mouth under topical anesthesia jelly (procaine applied 15 minutes before the procedure) without rupturing. This excised tissue measuring 8 x 3 x 2 mm and was sent for histopathological examination (fig 3 & 4). The postoperative discomfort was minimal and the patient was advised to take analgesics only on s.o.s basis, no antibiotics were prescribed.

On Histopathological examination of the excised mass sections of focally hyperplastic, epithelium with sub-epithelium showing lobules of capillary-sized blood vessels with intervening stroma with moderate inflammatory cell infiltrate was seen. This is consistent with the clinical diagnosis of Lobular capillary Haemangioma. At 48 hours and 1 week follow-ups healing was uneventful. At 3 months and 1 year follow-up the patient is well and has no complications or sign of recurrence, the mucosa in the area is normal and margins merge to the floor of the mouth (fig 5 & fig 6).

DISCUSSION :

The most common site of Lobular capillary Hemangioma is gingival region although in the present case it was floor of the mouth. The female patient of 15 years (2nd decade) is consistent with the preponderance reported in the literature [3,4]. The lesion did not show much difference in colour of mucosa with that of normal oral mucosa, as happens in older lesions. These lesions report commonly with

ulceration as was the present case. The clinical examination of the lesion suggested the provisional diagnosis of Lobular capillary Hemangioma, which was also confirmed by histopathologic examination.

The application of laser technology has been on the rise in the field of dentistry. It has been successfully used in clinical procedures, including operations and restorations of temporary and permanent teeth, pulp and periodontal treatments, and surgery. The uses of lasers in children and adolescents have been fully reviewed [15,16]. In recent years, the use of ErCr:YSGG lasers in dentistry has increased[9,17]. The wavelength of the ErCr:YSGG laser is 2,780 nm, which lies in the mid-infrared part of the electromagnetic spectrum. The energy produced by the ErCr:YSGG laser shows good absorption by water and, to a lesser extent by, hydroxyapatite. Since water is present in all the dental tissues, the ErCr:YSGG laser can be used for many dental procedures. The water contained in enamel, dentin, cementum, bone, and soft tissue absorbs the energy produced by the ErCr:YSGG laser, and the result is ablation of the target tissue. The water content of Enamel is approximately 3% and that of dentin is 12%. Bone (15%) and Cementum (15%) have a slightly higher water content compared with dentin, and soft tissue (70%) has the highest water content [14]. The requirement of laser energy is less to ablate soft tissue than enamel [17]. So this is a versatile laser which can be used for both hard and soft tissue application with alterations in output settings [14,17]. This laser is thus very useful in oral surgical procedures, as it involves a reduction in the amount of local analgesia and in the duration of intervention, the ease of technique, and haemostatic effect produced by the laser that enhances visibility of the surgical area[18]. This laser reduces

bleeding, has a low inflammatory response, reduces the chances of infection and pain, has a sealing effect of the local lymphatic tissues thereby reduces post-surgical edema [12,19]. In the present case the use of laser eliminated the need for sutures and minimizes post-surgical scarring. These cumulative effects further reduce the requirement of medication [18]. In the past the various soft tissue procedures for which this laser has been used; have been crown lengthening, exposure of an unerupted molar, lingual and maxillary frenectomies, fibroma removal, gingivectomy, gingival troughing for impressions, and the elimination of gingival pigmentation, excision of a pyogenic granuloma and for a pulpotomy[9]. Literature supports that the use of lasers can alleviate fear and psychological stress during the dental visit [9,10]. This laser has been successfully used in the past for the excision of pyogenic granuloma mostly from the gingiva [9,11,13]. To the best of our knowledge this is the first case reported for excision of LCH from the floor of the mouth where precision was required because of the high vasculature in the area.

CONCLUSION

The present case shows that a soft tissue growth such as a LCH can be effectively treated using ErCr:YSGG laser excision. The ErCr:YSGG laser can emerge as a treatment of choice for painless minor oral surgical procedures.

References

- 1) Rubin E, Reisner HM, editors. Essentials of Rubin's pathology. 6th ed. Lippincott Williams & Wilkins; 2014. p.667
- 2) Neville BW, Damm DD, Allen CM, Bouquot JE. Oral and Maxillofacial Pathology. 2nd ed. Philadelphia: W.B. Saunders Co.; 2004. p. 444-9
- 3) Toida M, Hasegawa T, Watanabe F, et al. Lobular capillary hemangioma of the oral mucosa: Clinicopathological study of 43 cases with a special reference to immunohistochemical characterization of the vascular elements. Pathol Int 2003;53: 1-7
- 4) Lin RL, Janniger CK. Pyogenic granuloma. Cutis 2004;74:229-33
- 5) Jafarzadeh H, Sanatkhanani M, Moshtasham N. Oral pyogenic granuloma: A review. J Oral Sci 2006;48: 167-75.
- 6) Pagliai KA, Cohen BA. Pyogenic granuloma in children. Pediatr Dermatol 2004;21:10-3.
- 7) Al-Khateeb T, Ababneh K. Oral pyogenic granuloma in Jordanians: A retrospective analysis of 108 cases. J Oral Maxillofac Surg 2003;61: 1285-8.
- 8) Olivi G, Genovese MD. Laser restorative dentistry in children and adolescents. children Eur Arch Paediatr Dent. 2011 Apr;12(2):68-78.
- 9) Boj JR, Poirier C, Hernandez M, Espassa E, Espanya A. Case series: Laser treatments for soft tissue problems in children Eur Arch Paediatr Dent. 2011 Apr;12(2):113-7.
- 10) Gontijo I, Navarro RS, Haypek P, Ciamponi AL, Haddad AE. The applications of diode and Er:YAG lasers in labial frenectomy in infant patients. J Dent Child (Chic). 2005;72(1):10-5

- 11) Licata ME, Albanese A, Giannatempo G, Dioguardi M, Campisi G. Minimally invasive approach to eliminate pyogenic granuloma using Er, Cr: YSGG laser. *Ann Stomatol (Roma)*. 2013 Oct 24;4(Suppl 2):25. eCollection 2013.
- 12) Boj J, Galofre N, España A ,et al. Pain perception in pediatric patients undergoing laser treatments. *J Oral Laser Appl* 2005a;5:85-89
- 13) Er,Cr: YSGG laser assisted excision of pregnancy tumor. *Journal of oral laser applications* 2010 Vol-1 Pg 171-174
- 14) Hadley J, Young DA, Eversole LR, Gornbein JA. A laser-powered hydrokinetic system: for caries removal and cavity preparation. *The Journal of the American Dental Association*. 2000 Jun 30;131(6):777-85.
- 15) Martens LC. Laser physics and a review of laser applications in dentistry for children. *European Archives of Paediatric Dentistry*. 2011 Apr 1;12(2):61-7.
- 16) Olivi G, Genovese MD, Caprioglio C. Evidence-based dentistry on laser paediatric dentistry: review and outlook. *European Journal of Paediatric Dentistry*. 2009 Mar 1;10(1):29.
- 17) Boja JR. The future of laser pediatric dentistry. *J Oral Laser Appl* 2005b; 5:173-177
- 18) Boj JR, Poirier C, Hernandez M, Espasa E, Espanya A. Review: laser soft tissue treatments for paediatric dental patients. *European archives of paediatric dentistry*. 2011 Apr 1;12(2):100-5.
- 19) Ryu SW, Lee SH, Yoon HJ. A comparative histological and immunohistochemical study of wound healing following incision with a scalpel, CO2 laser or Er, Cr: YSGG laser in the Guinea pig oral mucosa. *Acta Odontologica Scandinavica*. 2012 Dec 1;70(6):448-54.