

Case Report

Dentitia Praecox - Natal Teeth: A Case Report and Review

Akash Ardeshana¹, Seema Bargale², Anuradha Karri³, Bhavna Dave⁴

^{1,3} Post Graduate Student, ^{2,4} Professor, Department of Pedodontics & Preventive Dentistry,
K.M. Shah dental college and hospital, Sumandeep Vidyapeeth, Vadodara, Gujarat, India

ARTICLE INFO



Keywords:

Natal teeth, Pre-deciduous teeth,
Prevalence, Treatment

ABSTRACT

Occurrence of natal and neonatal teeth is rare anomalies. Natal teeth present at birth where as neonatal teeth erupt within thirty days of life. Exact etiology for this condition is unknown. Different factors like heredity, environmental toxicant, endocrine disturbances, and superficial position of tooth germ are associated with etiology. Prevalence is different in different population. Natal and neonatal teeth are usually present as pair and most commonly seen in mandibular central incisor region. There are various problem associated with natal and neonatal teeth, like pain on suckling, mobility of the teeth, ulceration on ventral surface of tongue and refusal to feed. The decision of treatment plan is based on several factors. If it is part of normal dentition without any complication, maintain in the mouth is the first treatment choice. Extraction is performed if these teeth are extremely mobile to avoid the chance of aspiration. Here we present a case of 8 day old baby with natal teeth and discuss the literature review of its quadrant wise distribution, prevalence clinical features, treatment plane and complication.

INTRODUCTION

The First primary tooth erupt in the oral cavity approximately at the six-months of age.¹ The presence of teeth at birth or within a month post-delivery is a rare condition. Massler and Savara have divided these teeth into two groups based on the time of eruption: natal teeth those are present at birth and neonatal teeth those that erupt during the neonatal period (past 30 days of life).² Teeth erupting beyond the natal period of thirty days (i.e. erupting within 1-3.5 months) are often referred to as early infancy teeth.³ this article gives a review of natal and neonatal teeth with the proper case discussion.

Historical Background and Myth:

Natal and neonatal teeth were first documented by Titus Livius, in 59 BC. Gaius Plinius Secundus (the Elder), in 23 BC, believed that a splendid future

awaited male infants with natal teeth.³ In Poland, India, and Africa, superstition existed generally for a long time, and in many African folks children born with teeth were murdered soon after birth because it was believed to bring misfortune.⁴ In China, children were born with natal teeth considered a bad omen. And believed that when these natal teeth would start to bite one of the parents would die.⁵

In England, infants born with natal teeth were considered intended to be famous soldiers, while those born in Franc and Italy were considered future defeater of the world.¹ Synonyms such as such as pre-deciduous teeth, congenital teeth, , precociously erupted teeth, premature teeth, dentitia praecox or foetal teeth have been used to refer this condition.⁶

* Corresponding author: Dr. Akash Ardeshana, A-10, Vrundavan society, behind the AS Bajaj, Vrundavan char rasta, Waghodia road, Vadodar. Email: drakash.002@gmail.com. Mobile no:+919427131555

Etiology

Exact etiology of natal and neonatal teeth is unknown. It has been related to various factors. Hereditary transmission of an autosomal dominant gene appears to be an important factor. Mayhall JT (1965)⁷ conducted study on Alaskan Tlingit Indians and he found the prevalence of natal or neonatal teeth was 9% and out of them 62% relatives of newborn's were also affected. Massler and Savara (1950) studied 24 cases in which 10 cases associated with hereditary factor.⁸

Maternal exposure to environmental toxins: Alaluusua S et al (2002)⁹ reported that the Children born to mothers accidentally exposed to polychlorinated biphenyl (PCBs), polychlorinated dibenzofuran (PCDF), polychlorinated dibenzo-p-dioxin (PCDD) have obviously had increased prevalences of natal teeth. In the Taiwan in Yusheng accident, 13 of 128 new born had the natal teeth where the compounds like PCD and PCDF had transplacentally exposed to mothers.⁹

Endocrine disturbances, nutritional deficiency, e.g., hypovitaminosis, febrile status superficial position of the tooth germ have also associated with natal and neonatal teeth. Superficial localization of the dental follicles is the most acceptable theory which is related to hereditary factor.⁸

Syndromes associated with natal teeth

The syndromes include Adrenogenital syndrome, Cleft lip and palate, Craniofacial dysostosis, Epidermolysis bullosa simplex, Ellis-van Creveld syndrome, Craniosynostosis syndromes, Hallerman-Streiff syndrome, Van der Woude syndrome, Jadassohn-Lewandowsky syndrome, Ectodermal dysplasia,

Multiple steacystoma, Wiedeman-Rautenstrauch syndrome, Pfeiffer syndrome, , Steatocystoma multiplex, Rubinstein-Taybi syndrome, Sotos syndrome, Pierre- Robin syndrome, Polydactyly type II, Walker-Warburg syndrome, and Pallister-Hall syndrome.^{10 11}

Prevalence

Prevalence of natal reported by different other for different population. It is range from 1:11 to 1:30000 depending on the type of the stud. The highest prevalence is found in the only study that relies on personal examination of patients.⁸ Bodenhoff and Gorlin (1963)¹² have reviewed early prevalence studies from 1876 to 1958 showed the mean prevalence was 1 in 6000 births.⁹ There was no difference in prevalence between males and females. However, Almeida CM et al (1996)¹³ reported a 66% prediction for female compare to 31% proportion for males.

Kana A (2013)¹⁴ reviewed the literature of prevalence studies by the different authors are mentioned in the table 1.

Classification

Spoug and Feasby (1966)¹⁵ classified natal and neonatal teeth according to degree of maturity:

1. A mature natal or neonatal tooth is one which is nearly or fully developed and has relatively good prognosis for maintenance;
2. The term immature natal or neonatal tooth on the other hand implies a tooth with incomplete or substandard structure; it also implies a poor prognosis.

According to appearance of tooth, Hebling (1997)¹⁶ classified natal and neonatal teeth into four clinical categories:¹⁶

1. Shell-shaped crown poorly fixed to the alveolus by the gingival tissue and absence of a root
2. Solid crown poorly fixed to the alveolus by the gingival tissue and little or no root
3. Eruption of the incisal margin of the crown through the gingival tissues
4. Edema of the gingival tissue with an unerupted but palpable tooth.

Clinical Characteristics

The most frequently affected teeth are the lower deciduous central incisors (85%), followed by the maxillary incisors (1%), mandibular canines and molars (3%), and maxillary canines and molars (1%).¹⁷ double in 61% of cases¹⁸ and correspond to teeth of the normal primary dentition in 95% of cases, while 5% are supernumerary.¹⁹

Some rare reports are available in the literature about the involvement of natal molars and canines.²⁰ According to Bodenhoff and Gorlin (1963),¹² 85% of the teeth involved are lower incisors, 11% are upper incisors, 3% are lower canines and molars, and only 1% are upper canines and molars. Tay (1970)¹⁹ reported a case of natal teeth in which a second upper molar and a lower canine were involved. Sogi S (2011)²¹ reported multiple natal teeth in anterior maxilla and multiple elevation in posterior part of maxillary and mandibular arch.

Table 2 show the quadrant wise distribution of natal and neonatal teeth from review articles of Mhaske S et al (2013)³ who overviewed the sixty literatures and Moura LF et al (2014)²² reviewed 23 cases.

The natal teeth or neonatal teeth present usually with variable size and shape. It may range from small, conical and may also look like normal teeth. The appearance of these teeth are mainly reliant on the degree of maturity, but most of the time they are small, loose, hypoplastic and discolored as in our case here.³ They may show enamel hypomineralization/hypoplasia and a small root formation indicative of an immature nature. The majority of natal teeth may reveal a brown-yellowish-/whitish-opaque colour and most of the time are attached to the soft tissue pad above the alveolar ridge.¹¹

Case Report

An 8 day-old female infant was referred to the department of Paedodontics and preventive Dentistry for K.M Shah Dental College and Hospital with complaint of teeth in the lower jaw since birth. On medical examination baby was pre term twin with 1.4 kg weight. Intraoral examination revealed two crown of the teeth in the mandibular anterior region [Fig 1], which are yellowish brown in color and manifesting the grade II mobility. The crown size was normal and resemble to primary incisor.

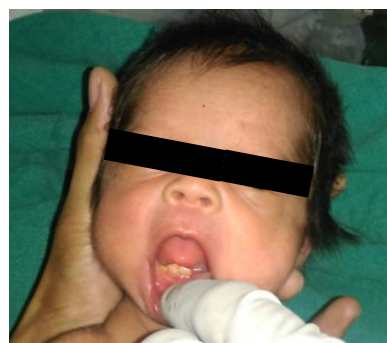

Fig 1: 8 days old infant with two mandibular natal teeth

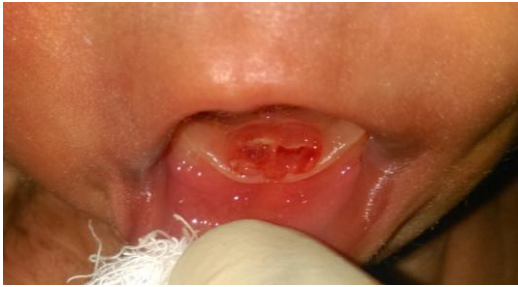

Fig 2: Post extraction socket of the mandibular natal teeth with control of bleeding

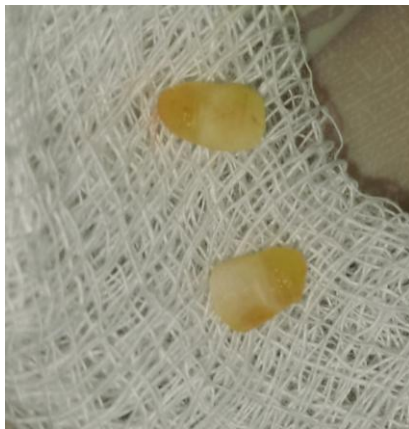

Fig 3: Natal teeth showing absence of root formation

The appearance of gingiva was normal. There was no ulceration found on ventral surface of tongue. There was no association of any soft tissue and hard tissue abnormality. There was no relevant familial history of any similar oral manifestation. Child was normal without association of any syndrome. A diagnosis of natal tooth in mandibular anterior region was given.

As tooth was grade II mobile extraction of natal tooth was the treatment of choice. A pediatrician was consulted and vitamin K was administered intramuscularly (0.5-1 mg) as a part of instantaneous medical care to prevent hemorrhage. The teeth were extracted under topical local anesthesia with the help

of sterile gauze piece [Fig 2]. The extracted teeth had a crown but were completely absent of roots [Fig 3]. The patient was reevaluated after 7 days and the healing was uneventful.

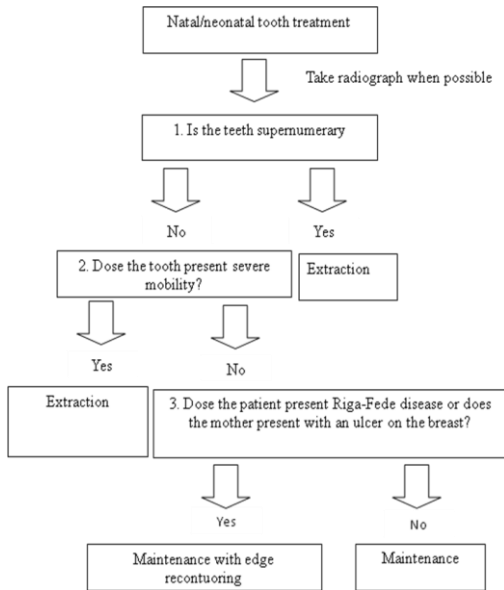
H & E stained section of this case show tooth like structure in the formative stage circumscribed by eosinophilic material suggestive of enamel. Underlying the enamel a dentinoid layers was seen. Deeper areas show immature cells (primitive). There were numerous capillaries surrounded by endothelial cells. There was evidence of extravasated RBC in certain areas.

Differential Diagnosis

The clinical differential diagnosis of natal and neonatal teeth should include dental lamina cysts, which are pale, yellowish-white, circumscribed lesions located in the alveolar ridge of newborns, hamartoma and lymphangioma (if the natal tooth occurs in the posterior mandible).¹ Supernumerary teeth may be differentiated from the normal sequence of deciduous teeth using occlusal or intraoral periapical radiographs, but the difficulty of properly positioning the film in the mouth of a newborn limits its application. Moreover, during this phase of growth and development, primary teeth are undergoing initiation of crown calcification, a situation that complicates the radiographic interpretation. As such, it may be best to defer the radiographic examination.²²

Treatment

Treatment decision flowchart described by Moura LF et al (2014)²²



The decision of treatment plan is base on several factors like: degree of mobility, inconvenience during suckling, interference with breastfeeding, and if the tooth is supernumerary or is part of the normal dentition.¹⁰ If these erupted teeth have been diagnosed as part of the primary dentition, maintenance in the mouth is the foremost treatment option apart from if they become a source of injury to the baby. If the teeth are well implanted, these teeth should be left in the arch.²³

Allwright (1958)¹⁷ and Matins et al (1998) were recommended smoothening the incisal edges of the teeth to prevent the injury to the maternal breast.²⁴ Feeding splint was the option reported by Bjuggren G. (1973).²⁵ Goho (1996)²⁶ was suggested to cover the incisal portion of the tooth with composit resin.²⁴. Tomizawa et al (1989)²⁷ reported two cases of treatment of Riga-Fede disease by covering the incisal margin with photopolymerizable resin, which aided rapid healing of the ulcers on the ventral surface of the tongue .

Table 1: Prevalence of natal and neonatal teeth

Authors	Prevalence	No. of children in the sample	Race
Puech, 1876	1:30000	60000	
Allwright (1958) Allwright (1958)	1: 3,400	6,817	
Gordon and Langley (1970)	1:100	407	American Indian
Mayhall JT (1967) ⁷	1:11.25	90	Tlinget Indians
Jarvis and Gorlin (1972)	1:100	1,571	Eskimo
Kates et al. (1984)	1: 1,397	18,155	
King and Lee (1989)	1:1,324	22,500	Asian
Rusmah (1991)	1:2,325	9,600	
To(1991)	1:1,118	53,678	Asian
De Almeida and Gomide (1996)	1:50	1,019 (unilateral Cleft lip and palate)	Brazilian
Alaluusua et al. (2002)	1:1,013	34,457	
Abid et al (2003)	1: 523	523	
Liu and Huang (2004)	1:140	420	Asian
Mohammadzadeh and Mokhtari (2005)	1.2:1,000	3,298	

Freudenberger et al. (2008)	2.3:100	2,182	
George et al. (2008)	3:1,038	1,038	Indian

Many of natal and neonatal teeth show indication of hypomineralization, and there is limited surface of enamel for bonding of resin. These factors, combined with difficulty of adequate moisture control, and limited access may not achieve proper retention of the resin. If the restoration fails, the composite resin could also be swallowed or inhaled. Both of these treatment regimes present practical difficulties considering the age of the children involved.⁸

When they impede with feeding or when they are extremely mobile with a risk of aspiration, extraction of natal teeth is indicated.²³ If the treatment of natal teeth is required extraction, this procedure should not cause any difficulties as these teeth can be removed with a forceps or even with the fingers.²⁸ However it can be delayed till the child is 10 days of age or more for appropriate blood levels of vitamin K.¹⁰ During this waiting period commensal flora of the intestine to become established and to produce vitamin K, which is necessary for the production of prothrombin in the liver.⁴

If it is not possible to wait then it is advisable to evaluate the need for administration of vitamin K with a pediatrician, if the newborn was not medicated with vitamin K immediately after birth. Vitamin K (0.5-1.0 mg) is administered intramuscularly to the baby as part of immediate medical care to prevent hemorrhagic disease of the newborn.⁴ Once extraction is performed, it is necessary to remove the underlying dental papilla

Table 2: Quadrant wise distribution of natal and neonatal teeth

Site	Natal	Neonatal
Maxillary anterior	8	
Maxillary posterior	10	
Mandibular anterior	68	6
Mandibular posterior	11	

and Hertwig's epithelial root sheath during the extraction of natal tooth/teeth which prevent the development of root structure that could continue if these structures are left in situ.¹⁰

In the non-extraction cases, the mothers should be counseled and explain the importance of oral hygiene using a fluoridated toothpaste and regular dental visits because infants have frequently access to breast-feeding, which is a risk factor for the development of early childhood caries. In addition to that, natal and neonatal teeth are especially at risk for the development of caries because they have immature and hypoplastic enamel, the enamel-dentin junction is irregular, and the tubules are more cellular and numerous.²²

Complication

1. The foremost complication from neonatal teeth is ulceration on the ventral surface of the tongue caused by tooth's sharp incisal edge. The lesion was first described by an Italian physician Antonio Riga, in 1881. It has been subsequently been known as "Riga-Fede disease"⁵
2. The teeth are loose and movable in the early stages, possible risk of the infant inhaling the

tooth into his/her lungs if the tooth becomes dislodged during nursing.⁸

3. Difficulty in feeding or refusal to feed due to pain.
4. Kinirons in 1985 reported sublingual ulceration due to sucking.²⁴
5. Ulceration to the nipple of the mother and interference with breast feeding. Hals, Zhu, and King; and Walter et al. reported that there is no association between injury to mother's nipple and the presence of the natal teeth since the tongue is interposed between these teeth and the nipple during breastfeeding.⁸
6. Kamboj M and Chougule R (2009)²⁹ reported swelling and pus associated with the chin due to presence of natal teeth.

Conclusion

On the basis of literatures we conclude that natal and neonatal teeth are rare condition. Mandibular central incisors are most commonly affected tooth. In our case, we chose the extraction of the teeth as the teeth were extremely mobile. It is also to understand clinical features and appropriate treatment plan for natal and neonatal teeth. Parents counseling and periodic follow up is required to observe the status of developing dentition.

References

1. Leung AK, Robson WL. Natal teeth: a review. *Journal of the national medical association.* 2006 Feb; 98(2): 226.
2. Massler M, Savara BS. Natal and neonatal teeth: a review of twenty-four cases reported in the literature. *The Journal of pediatrics.* 1950 Mar 31; 36(3): 349-59.
3. Mhaske S, Yuwanati MB, Mhaske A, Ragavendra R, Kamath K, Saawarn S. Natal and neonatal teeth: an overview of the literature. *ISRN pediatrics.* 2013 Aug 18; 2013.
4. Cunha RF, Boer FA, Torriani DD, Frossard WT. Natal and neonatal teeth: review of the literature. *Pediatric Dentistry.* 2001 Dec; 23(2): 158-62.
5. Deep SB, Ranadheer E, Rohan B. Riga-Fede Disease: Report of a case with literature review. *Journal of Academy of Advanced Dental Research.* 2011 May; 2(2).
6. Singh D, Agrawal S. Natal tooth: a case report and review. *Guident.* 2013 Jan; 6(2).
7. Mayhall JT. Natal and neonatal teeth among the Tlinget Indians. *Journal of dental research.* 1967 Jul; 46(4): 748-9.
8. Rao RS, Mathad SV. Natal teeth: Case report and review of literature. *Journal of oral and maxillofacial pathology.* 2009 Jan; 13(1): 41.
9. Alaluusua S, Kiviranta H, Leppäniemi A, Hölttä P, Lukinmaa PL, Lope L, Järvenpää AL, Renlund M, Toppari J, Virtanen H, Kaleva M. Natal and neonatal teeth in relation to environmental toxicants. *Pediatric research.* 2002 Nov; 52(5): 652-5.
10. Malki GA, Al-Badawi EA, Dahlan MA. Natal Teeth: A Case Report and Reappraisal. *Case reports in dentistry.* 2015 Feb; 4:2015.
11. Mohamed M, Ashok Kumar KR, Keswani K, Babaji P. Natal Teeth: Review of literature and a case report. *Indian Journal of Dental Sciences.* 2013 Jun; 5(2).
12. Bodenhoff J, Gorlin RJ 1963 Natal and teeth: folklore and facts. *Pediatrics* 49:1087– 1093.

13. Machado de Almeida C, Ribeiro Gomide M. Prevalence of natal/neonatal teeth in cleft lip and palate infants. *The Cleft palate-craniofacial journal*. 1996 Jul; 33(4): 297-9.
14. Kana A, Markou L, Arhakis A, Kotsanos N. Natal and neonatal teeth: a systematic review of prevalence and management. *Eur J Paediatr Dent*. 2013 Mar; 14(1): 27-32.
15. Spouge JD, Feasby WH. Erupted teeth in the newborn. *Oral Surg Oral Med Oral Pathol*. 1966; 22:198-208.
16. Hebling J, Zuanon ACC, Vianna DR. Dente Natal- Acase of natal teeth. *OdontolClin*. 1975; 7:37 – 40.
17. Allwright WC. Natal and neonatal teeth. *British Dent J* 1958; 105: 163-172.
18. Howkins C. Congenital teeth. *Br Dent Assoc*. 1932; 53: 402-405.
19. Tay WM. Natal canine and molar in an infant. *Oral Surg Oral Med Oral Pathol*. 1970; 29: 598-602.
20. Ruschel HC, Spiguel MH, Piccinini DD, Ferreira SH, Feldens EG. Natal primary molar: clinical and histological aspects. *Journal of oral science*. 2010; 52(2): 313-7.
21. Sogi S, Hugar SM, Patil S, Kumar S. Multiple natal teeth: a rare case report. *Indian Journal of Dental Research*. 2011 Jan; 22(1): 169.
22. Moura LF, Moura MS, Lima MD, Lima CC, Dantas-Neta NB, Lopes TS. Natal and Neonatal Teeth: A Review of 23 Cases. *Journal of Dentistry for Children*. 2014 May; 81(2): 107-11.
23. Toledo AO. Crescimento e desenvolvimento: noções de interesse odontopediátrico. In: *Odontopediatria: Fundamentos Para a Prática Clínica*. São Paulo: Premier; 1996:17-40.
24. Aneundi RT, Sudha P, Kaveri H, Sadanand K. Natal and neonatal teeth: A report of four cases. *J Indian Soc Pedo Prev Dent*. 2002; 20: 86–92.
25. Bjuggren G. Premature eruption in the primary dentition--a clinical and radiological study. *Sven Tandlak Tidsskr*. 1973 Jul; 66(4): 343-55.
26. Goho C. Neonatal sublingual traumatic ulceration (Riga-Fede disease): reports of cases. *ASDC J Dent Child*. 1996 Sep-Oct; 63(5):362-4.
27. Tomizawa M, Yamada Y, Tonouchi K, Watanabe H, Noda T. Treatment of Riga-Fede's disease by resin-coverage of the incisal edges and seven cases of natal and neonatal teeth. *Shoni shikagaku zasshi. The Japanese journal of pedodontics*. 1988 Dec; 27(1): 182-90.
28. Bodenhoff J. Natal and neonatal teeth. *Dental Abstr*. 1960; 5:485- 488.
29. Kamboj M, Chougule R. Neonatal Tooth—How Dangerous Can it Be? *Journal of Clinical Pediatric Dentistry*. 2009 Sep 1; 34(1): 59-60.

Source of Support: Nil Conflict of Interest: None