

Case Report

Management of A Case with Few Remaining Natural Teeth with A Splinted Coping Magnet Retained Overdenture

Vishnu Manohar ¹, VR Thirumurthy ², YA Bindhoo ³, Anjana Kurien ⁴

¹Post Graduate Student, ² Professor and Head, ³ Reader, ⁴ Professor, Department Of Prosthodontics, Crown And Bridge Including Implantology, Sri Ramakrishna Dental College, Coimbatore

ARTICLE INFO



Keywords:

Magnetic overdenture, Few remaining teeth, Overdenture, Splinted coping, Intraoral magnets, Magnetic attachment

ABSTRACT

Magnets have become very popular in dentistry. The advent of biocompatible magnets that are highly corrosion resistant and have retentive forces that can aid denture retention in compromised cases have warranted their use in prosthodontic rehabilitation. Clinical conditions where only a few natural teeth remain are cases where an overdenture is indicated. This option would help to preserve the roots in the alveolar process thereby delaying the resorption and thus avoiding early loss of anterior facial height. The presence of periodontally weak teeth can be utilized to our advantage by means of splinting them and incorporating a single magnetic keeper in the cast coping. The use of a magnetic attachment in such cases would serve to minimize the lateral load on the teeth and ensure long term service of the retained roots in ridge preservation. This case report details the stepwise fabrication of the full arch magnetic overdenture which was made with a cast metal denture base in the upper jaw.

Introduction

Few remaining natural teeth especially in the anterior region present a clinical dilemma, whether or not to extract, considering that they may always not withstand the load that any overlying prosthesis would exert. The incidence of such cases is quite high due to the reluctance of individuals in getting compromised anterior extracted, in comparison with the posteriors. In such conditions, endodontic therapy would be warranted to allow rehabilitation with some form of attachment retained overdenture prosthesis for rehabilitation.

Now, when this scenario is further complicated by the presence of mobility of the anterior teeth, the clinical judgment becomes difficult. In this case report, a similar condition was encountered where the remaining anterior teeth were grade II mobile and root canal treated. Magnets have been used in such cases to produce excellent results ¹⁻³. There is a multitude of commercially available magnets that can be used in this scenario ⁴.

Clinical report:

A male patient, aged 54, reported with chief complaint of Multiple Mobile and missing teeth and difficulty in speech and mastication. He had multiple upper teeth and lower teeth extracted following mobility. He was a smoker for the past 20 years, 5-7 cigarettes per day. Extraoral examination revealed mouth opening to be of 45mm and the temporomandibular joint was normal and asymptomatic. Intraoral examination revealed root canal treated upper anteriors (11,12,13,21) which were periodontally weak and presented mobility of Grade 1. The alveolar support of lower anteriors was severely compromised, displaying Grade 3 mobility of 31,32,41,42. Generalized recession (grade 2) was observed in the lower arch (Fig. 1). The case was diagnosed as *Kennedy's Class I partially edentulous maxillary arch*.

The treatment options presented to the patient were extraction of the mobile anterior teeth 11,12,13,21 and conventional complete denture; Implant supported overdenture and tooth supported overdenture. History of chronic smoking and unwillingness of the patient to quit the habit ruled out long term success of any Implant supported option.

To preserve the upper anterior teeth and consequently the alveolar bone, the roots were retained. Post spaces were prepared; and a splinted single unit coping connecting the cast posts of the teeth (11,12,13,21) was planned with a magnetic keeper, and a maxillary magnetic overdenture was decided as the treatment plan.

Oral prophylaxis and sub-gingival scaling was done in relation to the upper anterior region to eliminate periodontal pathology. Diagnostic impressions and tentative jaw relation were made to assess the amount of reduction of the anterior teeth. Following resolution, the crowns of 11, 12, 13 and 21 were sliced 2 mm above the cement-enamel junction and prepared with subgingival finish lines and crown ferrules (Fig. 2). The rationale for this choice is that the placement of a sub-gingival margin and reduction of the coronal tooth structure would provide the necessary surface area for retention and also preserve the inter-arch space in the anterior region for the replacement of upper anteriors in the final denture prosthesis. Post space preparation was then done to a depth not more than $2/3^{\text{rd}}$ of the root length. The apical seal of 5mm was left undisturbed. Parallelism was achieved between the four post spaces that required additional post space preparation in width for two teeth. A single path of draw was achieved. This was ensured by means of four tapering burs placed in their respective tapered post space preparations to verify the parallelism intra-operatively. Once adequate depth was achieved, impression of the post spaces was made with tooth picks

roughened and coated with light bodied impression material and picked up with a putty wash impression in

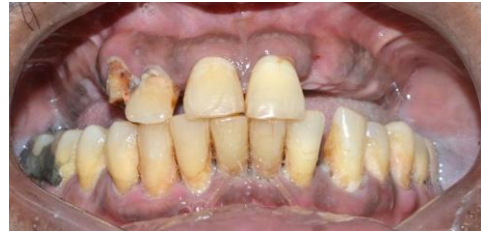

Fig. 1: Pre-operative intraoral view

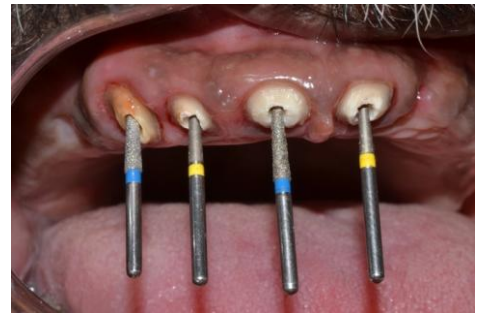

Fig. 2: Post space preparation of upper anteriors with tapering burs used to evaluate parallelism

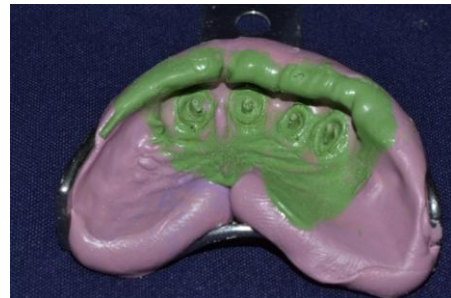

Fig. 3: Post- space impression made with details of the preparation margins and reduced teeth

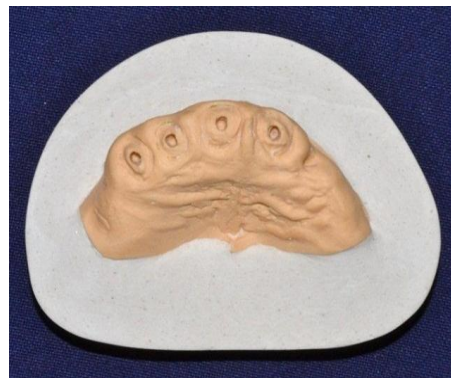

Fig. 4: Cast of the prepared teeth and their post spaces

the anterior region (Fig. 3). This was done for fabrication of the copings over the remaining anterior teeth. The copings over these posts were waxed up only to a thickness of 1mm over the coronal tooth structure and were splinted by connectors. The entire pattern was waxed up as a single unit. The magnetic attachment planned was then incorporated. The magnetic keeper was then attached over the coping region of 11 (Fig. 4,5). The pattern was then cast in metal. The copings obtained thus had the posts of the four teeth splinted to each other by their copings joined with bars. The magnetic keeper was also incorporated in this unit (Fig. 6).

This single unit splinted casting was tried for fit intra-orally (Fig. 7). The upper arch was border molded with putty on account of presence of a severe anterior labial undercut and secondary impression made with light bodied elastomer. The metal copings were picked up in the secondary impression (Fig. 8). Master cast was poured (Fig. 9). A metal denture base was planned for the upper complete denture since the patient was insistent on preserving the thermal sensations as much as possible over the palatal region.

To fabricate a metal denture base, the alveolar ridge was relieved by means of spacer wax. The internal finish line was established (Fig. 10). In the region of the keeper, additional relief was required between it and the metal mesh for incorporation of the magnet. For visualizing the required amount of relief, the magnet was placed over the keeper picked up on the master cast and additional spacer wax adapted over the magnet (Fig. 11). It would be picked up in the denture with auto-polymerizing acrylic resin later during insertion. The master cast was then duplicated and a refractory cast poured. The metal framework was designed and waxed up. It was sprued and cast in metal (Fig. 12).

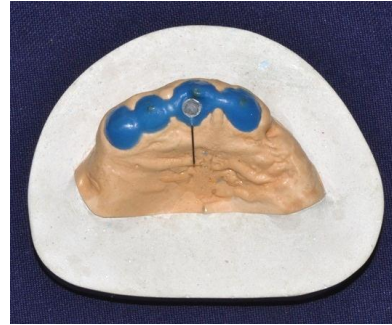


Fig. 5: Single unit Wax pattern with the patterns of the post spaces with the copings splinted. The magnetic keeper was incorporated into the design



Fig. 6: The cast copings with the keeper incorporated into the splinted single unit restoration

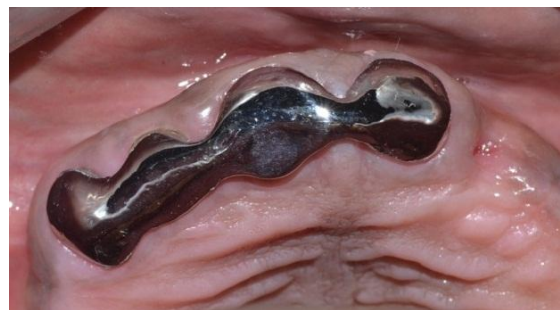

Fig. 7: The casting tried for fit intra-orally

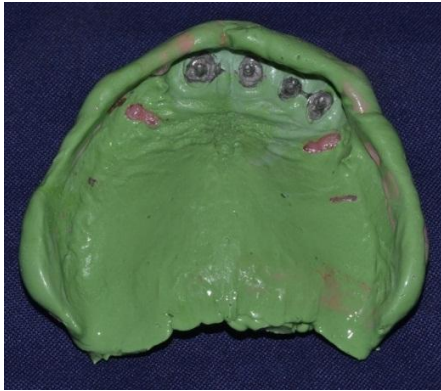

Fig. 8: The casting picked up in the secondary impression of the upper arch

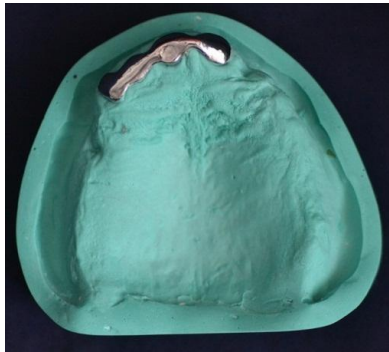


Fig. 9: The working cast for the fabrication of the cast metal framework.

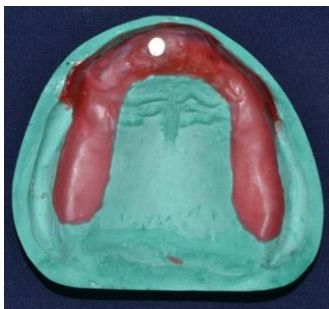

Fig. 10: The magnetic metal was placed over the keeper to verify the amount of clearance needed for acrylic in that region

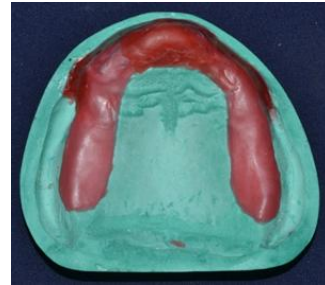

Fig. 11: Additional relief in the anterior region applied before duplicating the cast in refractory material



Fig. 12: the cast metal framework fabricated was verified for clearance over the magnetic metal placed on the keeper

By this time, the mobile lower anterior teeth were extracted and a partial denture was fabricated for the lower anterior teeth. The metal denture base was cast and tentative jaw relation was completed. Esthetic wax trial was done (Fig. 13a, 13b). The magnetic metal was then picked up in the upper complete denture using auto-polymerizing acrylic resin (Fig. 14,15).

Discussion:

In the case presented in this article, mobility of the upper anterior teeth would have called for extraction and complete upper denture prosthesis. Considering the advantage of retaining the anterior teeth in preserving the anterior facial height and reducing ridge resorption, they were not extracted. Instead, following endodontic

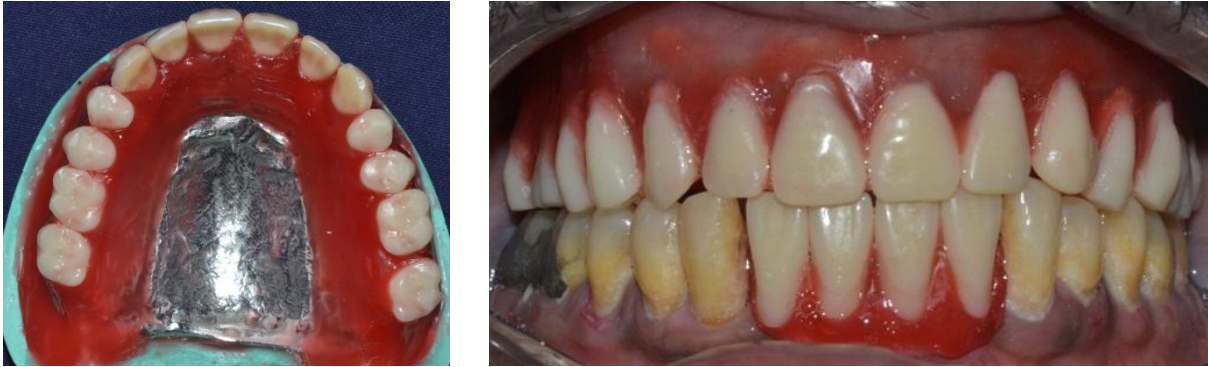

Fig. 13 (a,b): Esthetic wax trial done with the metal denture base incorporated inside upper arch trial denture

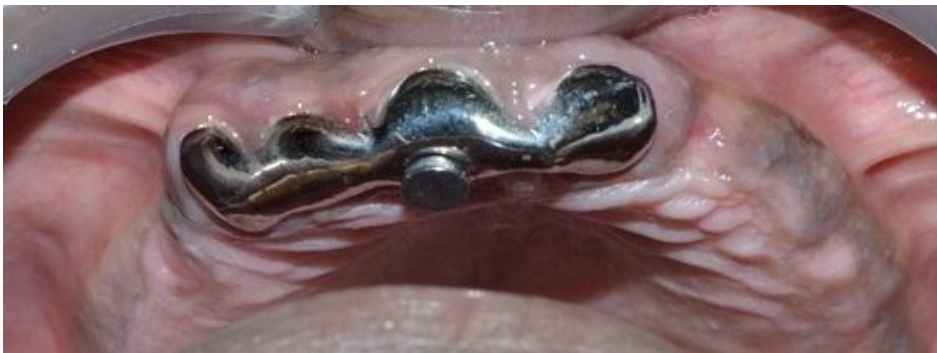

Fig. 14: the magnetic metal was seated over the keeper intra-orally after cementation of the cast coping and autopolymerizing acrylic was used to pick it up in the processed upper complete denture prosthesis

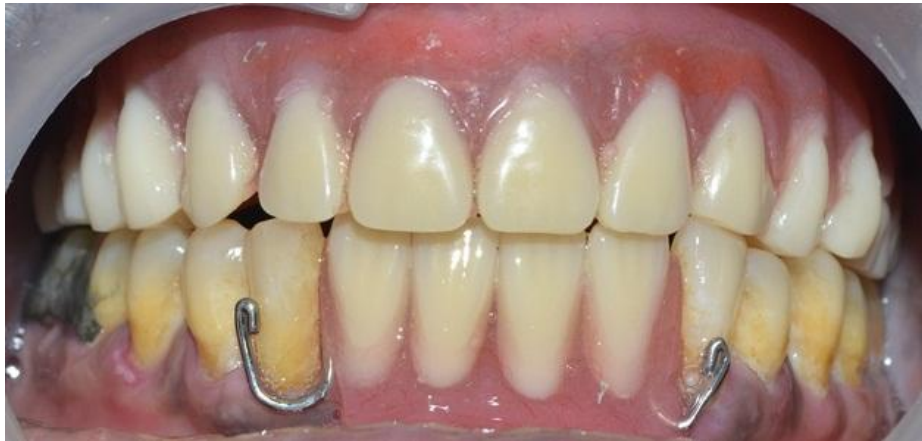

Fig. 15: Rehabilitated appearance of the patient with the magnetic overdenture in the upper arch against lower partial denture

therapy, the teeth were permanently splinted by means of a cast coping with post space extensions into the four teeth – 11, 12, 13, 21. A magnetic keeper was incorporated into the pattern of the same, prior to casting.

The rationale behind the choice of the magnetic attachment was as follows- The periodontal status of the remaining anterior teeth implied inability to withstand lateral load, which would lead to failure of their periodontal attachments. A magnetic attachment permitted lateral movement by disengaging as well as sliding movement between the keeper and the magnet. This provided a leeway for the prosthetic movement to occur without creating much stress on the anterior teeth.

Conclusion:

A simple technique for splinting periodontally compromised few remaining natural teeth to preserve the alveolar bone by means of a magnetic attachment retained overdenture is presented in this case report.

References:

1. Anupam P, Anandakrishna GN, Vibha S, Suma J, Shally K. Mandibular Overdenture Retained by Magnetic Assembly: A Clinical tip. *The Journal of the Indian Prosthodontic Society* 2014;14:328-333
2. Gillings BRD. Magnetic retention for complete and partial overdentures, Part I. *J Prosthet Dent* 1981;45:484-491
3. Moghadam BK, Scandrett FR. Magnetic retention for overdentures. *J Prosthet Dent* 1979;41:26-29.
4. Riley MA, Walmsley AD, Harris IR. Magnets in prosthetic dentistry. *J Prosthet Dent* 2001;86:137-142.