

Review Article

Interproximal Enamel Reduction in Orthodontic Treatment: A Review

Abhishek Choudhary¹, Ankit K Gautam², Ajay Chouksey³, Medha Bhusan⁴, Mukta Nigam⁵,
Manali Tiwari⁶

¹Post Graduate Student, Department of Orthodontics, Peoples Dental Academy, Bhopal, India

²Post Graduate Student, Department of Pedodontics, Peoples college of Dental Sciences & Research centre, Bhopal, India

³Department of Periodontics, Government Dental College, Indore, India

^{4,5,6}Post Graduate Student, Department of Conservative and Endodontics, Peoples Dental Academy, Bhopal, India

ARTICLE INFO



Keywords:

Interproximal enamel reduction,
Interproximal enamel reduction
techniques, Interdental stripping, Air-
rotor stripping, Orthodontic treatment

ABSTRACT

Interproximal enamel reduction is a part of orthodontic treatment for gaining a modest amount of space in the treatment of crowding. Nowadays interproximal enamel reduction has become a viable alternative to the extraction of permanent teeth, and helps to adjust the Bolton Index discrepancy. This review article discusses about the various interproximal enamel reduction techniques, indications, contraindications and complications.

Introduction

In orthodontic treatment the main goal of orthodontist is to create a balance among occlusal relationships, dental and facial esthetics, and thus achieving a long-term treatment stability. But in many patients it is difficult to achieve these ideals because the excess tooth material often interferes with the correct alignment of the teeth in the arch. Dental crowding in the anterior region is one of the most common findings in orthodontic patients. Several methods are suggested for relieving dental crowding such as transverse arch expansion, proclination of the anterior teeth, distalization of the teeth in the arch, extraction of the tooth, or interproximal enamel reduction. The age of the patient, facial profile and amount of crowding determines the choice of the treatment strategy. In 1944, Ballard first used

interproximal enamel reduction for the anterior segment.¹ It is a clinical procedure that involves the reduction, anatomic re-contouring, and protection of interproximal enamel surfaces of permanent teeth. For patients with mild to moderate crowding (4-8 mm), Interproximal enamel reduction (IER) is an alternative to dental extraction.² It is irreversible procedure therefore careful examination is mandatory prior to the treatment.

INDICATIONS FOR INTERPROXIMAL ENAMEL REDUCTION

IER should be carried out only in patients with low caries risk profile and good oral hygiene to avoid increased susceptibility to caries. The main indications for IER in the treatment of adults are crowding, when the lack of space in the dental arch is 4 to 8 mm,³ Bolton

* Corresponding author. Dr. Abhishek Chowdhary, Department of Orthodontics, Peoples Dental Academy, Bhopal, India. Email: dr.abhi2013@gmail.com

Index discrepancy, the ability to safely obtain sufficient space for tooth movement without the need for extractions, changes in tooth shape, macrodontia, normalization of gingival contour and elimination of black gingival triangles, enhancement of retention and stability after orthodontic treatment,⁴ and correction of the Curve of Spee.

CONTRANDICATIONS FOR INTERPROXIMAL ENAMEL REDUCTION

IER should not be carried out in patients with a high risk for caries and poor oral hygiene to avoid the risk of development of caries. The major contraindications are when crowding is more than 8 mm per arch, active periodontal diseases, enamel hypoplasia, hypersensitivity to cold, and multiple restorations, round-shaped premolar⁵ and young patients with large pulp chambers.

METHODS OF INTERPROXIMAL ENAMEL REDUCTION

It is important to know how much of the enamel can be reduced before performing IER. This can be done by projecting a line from the cervical line vertically to the occlusal plane because dentin is projected in a straight line from the cervical line. Studies revealed that the enamel is slightly thinner in the distal than in the mesial surfaces. Another way of measuring enamel thickness is using special gauges, up to the accuracy of one-tenth of a millimeter. Only after knowing the thickness of the interdental enamel, a clinician can decide how much of enamel can be removed. Fillion et al recommended not to remove more than 0.3 mm of the enamel from the upper incisors, 0.6 mm – from the upper posterior teeth, 0.2 mm – from the lower incisors, and 0.6 mm – from the mesial surface of the lower posterior teeth. Chudasama and Sheridan⁶ claimed that interdental

enamel is thinner on the upper lateral incisors and lower incisors, so only 0.5 mm should be removed from these contact points. Sheridan and Ledoux claimed that 6.4 mm of space can be gained by interproximal enamel reduction of eight proximal surfaces of the premolars and molars. Stroud *et al.* considered that it is possible to achieve 9.8 mm by applying the same procedure.

PROCEDURE-

Before performing IER all the teeth in the arch should be levelled and aligned, because after levelling and aligning it can easily be judged that whether correct occlusion can be achieved or not. After the alignment, separators should be used to create space between teeth, this improves visibility and access to the contact point. All the teeth should not be stripped during a single appointment. IER is performed with water or air cooling. Anatomy of the teeth is changed during IER and thus it is important to place the contact point between the teeth in the correct anatomical location, and to restore tooth contours to the original form to the greatest possible extent.

While selecting materials for IER, it is important to decide which instrument and soft tissue guards are needed to be used. IER materials are broadly classified as manual and rotary. Each of them have their own advantages and disadvantages.

Clinically most accepted IER techniques include-

1. The air-rotor stripping technique (ARS) with fine tungsten-carbide or diamond burs and diamond coated strips.
2. Hand-piece or contra-angle-mounted diamond- coated disks.
3. Handheld or motor-driven abrasive metal strips.

The choice of IER technique depends on the severity of crowding and position of teeth in the arch. The commonly used materials for the purpose are:

A-Metal abrasive strip- It is a manual instrument for anterior teeth enamel reduction. The strip can be used in an operator's hand, the Mathew haemostat, or in special strip holder. It can be used when the teeth are so rotated that a disk is not appropriate & for re-contouring teeth after IER. But sometimes it may become impractical, unproductive, and time-consuming when used for buccal teeth and leaves a part of strip lodged between the teeth.

B-Diamond disks- They are abrasive diamond-coated disks available in varying thicknesses and grits, similar to strips. They can be single/double-sided and are used with contra angled handpiece (Fig:-1). It provides the smoothest enamel surface with polishing after IER, but if not used properly may leave deep undercuts on the enamel and sometimes can become dangerous while working in close proximity to a patient's tongue, cheeks and lips.

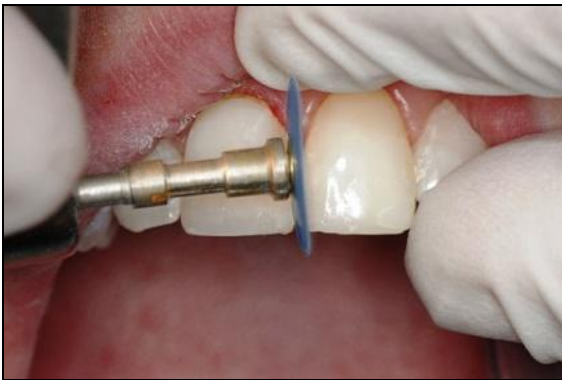

Fig:-1 Inter proximal enamel reduction with Diamond Disk

C-Air-rotor stripping (Burs) - It was first described by Sheridan as an alternative to extraction or expansion in borderline cases.⁷ While performing ARS it is recommended to use burs with safety-tipped non-cutting

areas to prevent furrows of the proximal walls, this can be done by using conventional burs with squared off tips(Fig:-2).The disadvantage with this technique is that it leaves the roughest enamel surface after IER compared to diamond discs and metal strips.

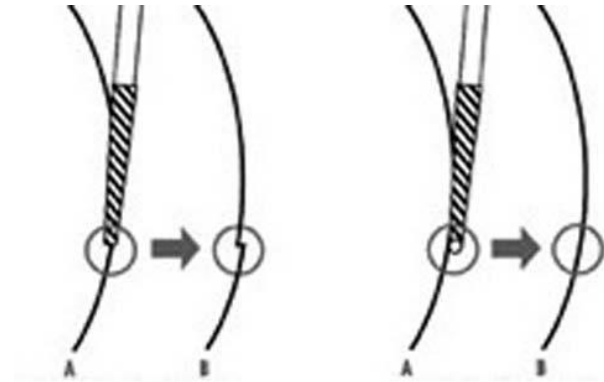


Fig:-2 Bur with a deactivated point

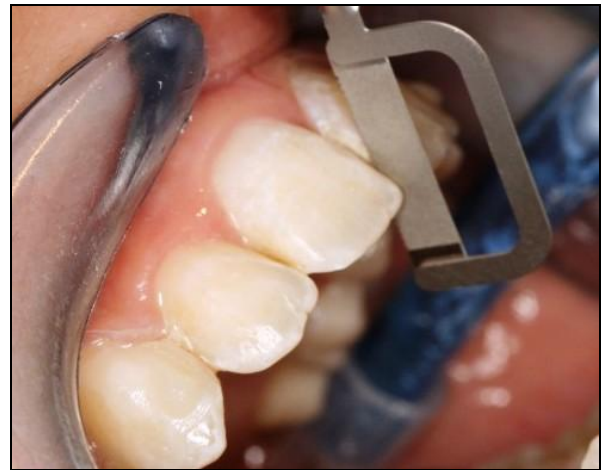

Fig. 3. "Ortho-strip" with a holder

D-Ortho-strips- These are thin, semi-flexible strips used with a holder (Figure 3). Intensive Proxo shapes are flexible thin blades that removes a small amount of the intermolar enamel to provide banding space if separation has not been effective. This technique requires more time than ARS, but the results obtained are more predictable, and the enamel surface obtained is smoother than that achieved when using burs

COMPLICATIONS OF INTERPROXIMAL ENAMEL REDUCTION

Injudicious use of IER can result into hypersensitivity, irreversible damage of the dental pulp, increased plaque retention and risk of periodontal diseases in the stripped enamel areas. Hypersensitivity to temperature changes⁸ depends on various factors such as the age of the patient, severity of crowding, pathological tooth wear, hypersensitivity before treatment, and the amount of the enamel removed. Iatrogenic injuries to the proximal enamel surface can be predisposing factors for periodontal diseases and caries because interdental enamel becomes more sensitive to demineralization. The risk of irreversible pulp damage is highest when a tungsten carbide bur is used for IER for the lower incisors therefore proper cooling techniques should be accompanied with it.

PREVENTIVE MEASURES TAKEN AFTER INTERPROXIMAL ENAMEL REDUCTION

Subsequent re-contouring steps should be performed to protect the enamel from increased risks of caries. Various strategies have been suggested, including 8% stannous fluoride for 4 minutes, fluoride mouth rinses for 45 days and 0.05% neutral sodium fluoride mouth rinses once daily. Some researchers also recommended the use of regular professionally-applied fluoride (1.23% acidulated phosphate fluoride) for 4 minutes together with fluoridated dentifrice daily.⁹ Applying sealant (e.g. fissure sealant) after etching for 20 seconds is another approach, yet it may not last long.¹⁰

CONCLUSION

Interproximal enamel stripping is an effective orthodontic treatment approach to regain space, improve

tooth and gum aesthetics as well as to maintain post-treatment stability. Nevertheless, clinicians should choose appropriate indications by balancing between its benefits and risks. With cautious pre-treatment planning, appropriate performance and post-treatment protection, IER possesses unique advantages in facilitating better treatment outcome in a more conservative and physiological way without harming dental or periodontal tissue.

REFERENCES

1. Rao V, George AM, Sahu SK, Krishnaswamy NR. Surface roughness evaluation of enamel after various stripping methods by using profilometer. *Arch Oral Sci Res* 2011;1:190-7.
2. Frindel C. Clear thinking about interproximal stripping. *J Dentofacial Anom Orthod* 2010;13:187-99.
3. Zachrisson BU, Minster L, Ogaard B, Birkhed D. Dental health assessed after interproximal enamel reduction: Caries risk in posterior teeth. *Am J Orthod Dentofacial Orthop* 2011;139:90-8.
4. Zachrisson BU, Nyoygaard L, Mobarak K. Dental health assessed more than 10 years after interproximal enamel reduction of mandibular anterior teeth. *Am J Orthod Dentofacial Orthop* 2007;131:162-9.
5. Jadhav S, Vattipelli S, Pavitra M. Interproximal enamel reduction in comprehensive orthodontic treatment: a review. *Indian J Stomatol* 2011;2:245-8.
6. Chudasama D, Sheridan JJ. Guidelines for contemporary air rotor stripping. *J Clin Orthod* 2007;41:315-20.
7. Jarjoura K, Gagnon G, Nieberg L. Caries risk after interproximal enamel reduction. *Am J Orthod Dentofacial Orthop* 2006;130:26-30.
8. Baysal A, Uysal T, Usumez S. Temperature rise in the pulp chamber during different stripping procedures. *Angle Orthod* 2007;77:478-82.

9. Rogers GA, Wagner MJ. Protection of stripped enamel surfaces with topical fluoride applications. *Am J Orthod.* 1969; 56(6): 551-9
10. Sheridan JJ, Ledoux PM. Air-rotor stripping and proximal sealants. An SEM evaluation. *J Clin Orthod.* 1989; 23(12): 790-4.

How to cite this article:

Choudhary A, Gautam AK, Chouksey A, Bhusan M, Nigam M, Tiwari M. Interproximal Enamel Reduction in Orthodontic Treatment: A Review .*JOADMS* 2015;1(3):123-127.

Source of Support: Nil, Conflict of Interest: None declared