

Case Report

Pyogenic granuloma (lobular capillary hemangioma) of the Tongue: a case report

Harmurti Singh¹, Abhishek Singh², Bharat Shukla³, Gourab Das⁴, Neha Agarwal⁵, Gauravi G. Singh⁶

¹Sr. Lecturer, Career Post Graduate Institute of Dental Sciences & Hospital, Lucknow, India

^{2,3,4} PG Student, Dept. Oral & maxillofacial surgery, Sardar Patel Post Graduate institute of dental & medical sciences, Lucknow, India

⁵PG Student, Department of Pedodontics & Preventive Dentistry, Mahatma Gandhi Dental College, Jaipur, India

⁶Tutor, Dept. Oral & maxillofacial surgery, Sardar Patel Post Graduate institute of dental & medical sciences, Lucknow, India

ARTICLE INFO

Access this article online :



Keywords:

Pyogenic granuloma, lobular capillary hemangioma, Human botryomycosis, Pregnancy tumor

ABSTRACT

Pyogenic granuloma of the oral cavity is a relatively common entity. The most frequent location encountered for oral cavity is the gingiva; Tongue is a rare location for its occurrence. A pyogenic granuloma will present as a soft, fleshy, easily bleeding red mass and may be ulcerated with a fibrinopurulent covering. They may occur at any age and are often stimulated by a foreign object such as the sharp margin of a restoration, calculus, or a foreign body within the gingival crevice. Pyogenic granuloma was first described by Poncet and Dor in 1897 as 'human botryomycosis'.

HISTOLOGICALLY: The lesion consists of loose granulation tissue with a proliferation of capillary vessels and endothelial cells arranged in lobules. Inflammatory infiltrate and fibrous tissue are also present.

TREATMENT: A pyogenic granuloma should be excised with 2-mm margins at its clinical periphery and to a depth to the periosteum or to the causative agent. Any foreign body, calculus, or defective restoration should be removed as part of the excision & recurrence is rare.

Introduction

Pyogenic granuloma is a hyperplastic, non-neoplastic, and inflammatory condition that occurs as a result of trauma, chronic local irritation, bone marrow transplant, hormonal changes, and reactions to grafts^{1,2}. It is also seen in women who are on oral contraceptives and during pregnancy³. Pyogenic granuloma (PG) was first described by Poncet and Dor in 1897 as 'human botryomycosis'⁴. Then the term 'Pyogenic granuloma' introduced by Hartzell⁵ and the term 'lobular capillary hemangioma' referred by some authors⁶. Clinically they usually present as exophytic, friable, red to yellow nodule, or ulcerate red, soft and single nodules that may grow, bleed and may be seen in any size from a few

millimeters to several centimetres⁷⁻⁹. Gingiva is the most common intra oral site in about 75% cases, but lips, mucosa and tongue are also affected¹. The lesion is histologically similar to the granulation tissue except that it is well localized and prolific. It consists of loose granulation tissue with a proliferation of capillary vessels and endothelial cells arranged in lobules. Inflammatory infiltrate and fibrous tissue are also present.¹⁰⁻¹²

Case report:

A 12 year old female child reported to private dental clinic with a chief complaint of growth at front side of tongue. She gave history of that growth since last 4-5 years with no complain of pain. Initially the swelling was

* Corresponding author. Dr. Harmurti Singh, Sr. Lecturer, Career Post Graduate Institute of Dental Sciences & Hospital, Lucknow, India

small; she visited to many clinics for the same problem and took primary medication for the same; But the swelling did not subside and was slowly enlarging without any pain. Patient also felt discomfort while mastication.

On inspection, there was a well defined, solitary pedunculated swelling present on the middle 1/3 of the dorsal surface of the tongue was at the midline, measuring approx 15 mm x 10 mm in size and was oval in shape. The swelling appeared lobular, with overlying mucosa, was yellow in colour intermixed with areas of redness. On palpation, all the inspectory findings were confirmed and the swelling was non tender and fixed.

No relevant history of any systemic disease was found. Routine blood investigations was within normal range. After complete evaluation a provisional diagnosis of pyogenic granuloma was made and was planned for excision biopsy with complete removal of lesion under local anaesthesia.

After securing local anesthesia, growth was gently lifted to make the peduncle visible from both side. A sharp elliptical incision was made around the peduncle to excise the lesion. Hemostasis was achieved and single layer closure was performed with the help of 3-0 silk suture. Excised specimen was preserved and sent for histopathological examination which confirmed the diagnosis Pyogenic granuloma. The patient was recalled after 7 days for suture removal. The patient is currently under follow up without any signs of the recurrence of the lesion. The time of the total follow up till date is 1 year.

Discussion:

Pyogenic granuloma (PG) is a hyperplastic, non-neoplastic, and inflammatory condition that occurs as a result of trauma, chronic local irritation, bone marrow

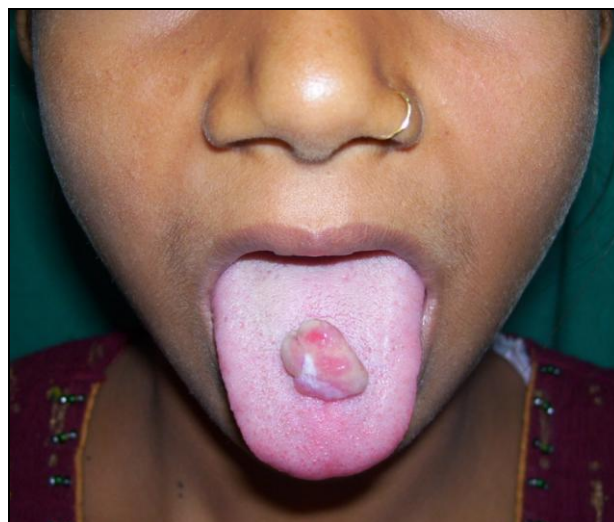


Figure 1: Intra oral photograph showing PG on dorsum of tongue

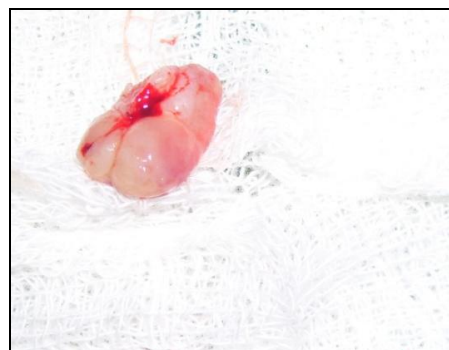


Figure 2: Excised Specimen

transplant, hormonal changes, and reactions to grafts^{1,2}. The rate of occurrence of PG in comparison to other reactive lesion is between 26.8% and 32%^{10,13}. It is seen in all age groups mainly in between 11 and 40 years predominantly at 30 years of age¹⁴. Females are more affected than male in the ratio of 3:2¹⁵.

Clinically PG appears as a small, purplish red to deep red lesion which is sessile or pedunculated. The surface appears as a smooth, lobulated or sometimes warty,

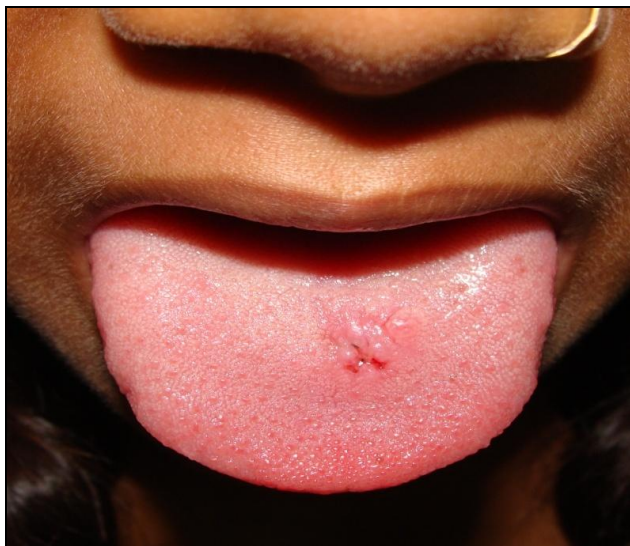

Figure 3: Post operative photograph

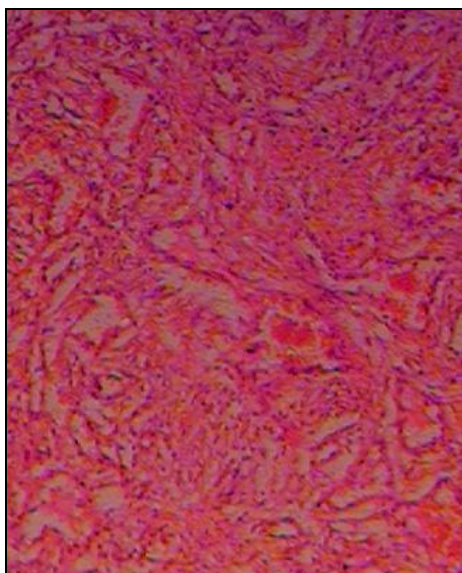


Figure 4: Histopathological features showing proliferation of capillaries with the squamous epithelium and infiltration by inflammatory cells

generally ulcerated having a tendency to bleed on impulsive or minor trauma. Consistency of the lesion is soft and remains painless but in the chronic lesion collagenization occurs resulting in firm consistency. The lesion size usually occurs between 0.5 cm to 2.5 cm and its growth occurs at a very fast rate within weeks or months.¹⁶

The pathogenesis of pyogenic granuloma is that might be occurred as a result of disrupt balance between angiogenesis enhancers and inhibitors¹. There is increase in the level of basic fibroblast growth factor (bFGF) and Vascular endothelial growth factor (VVEGF) and decrease in the level of thrombospondin-1, angiostatin, and estrogen receptors causing formation of pyogenic granuloma.

The lesion is histologically similar to the granulation tissue due to high vascular proliferation except that it is well localized and prolific. It consists of loose granulation tissue with a proliferation of capillary vessels known as non-lobular capillary hemangioma (non-LCH) and endothelial cells arranged in lobules, this type is known as capillary lobular hemangioma (CLH)¹⁷. Inflammatory cell infiltrate like neutrophils, plasma cells, lymphocytes and fibrous tissue are also present¹⁰⁻¹². PG consist of parakeratotic and non keratinized stratified squamous epithelium.³

Immunohistochemically PG consist of angiopoietin-1, angiopoietin-2, Tie2, ephrin B2 and Eph B4¹⁸. Others are like anti CD34 and anti alpha SMA antibodies are also seen.¹⁹

PG histologically and clinically resembles many lesions hence knowing differential diagnosis of PG is also very important. Differential diagnosis include post extraction granuloma, pregnancy tumor, metastatic tumor, kaposi's sarcoma, bacillary angiomatosis, hemangiopericytoma, hemangioendothelioma, leiomyoma, peripheral fibroma, hemangioma, peripheral ossifying fibroma, parulis, peripheral giant cell granuloma, angiosarcoma, Non – hodgkins lymphoma.^{20,21}

A pyogenic granuloma should be excised with 2-mm margins at its clinical periphery and to a depth to the periosteum or to the causative agent. Any foreign body, calculus, or defective restoration should be removed as

part of the excision. Other treatments are also available like cryosurgery with liquid nitrogen spray or cryoprobe, laser surgery with Nd:YAG, CO₂ and flash lamp pulsed lasers cause less haemorrhage as compared to surgical procedures, ethanol or corticosteroids injections and sodium tetradecyl sulphate sclerotherapy are also effective^{1,22}.

Recurrence is rare and is almost always related either to a failure to remove the stimulating factor or to the so-called pregnancy tumor, which may continue or recur because of ongoing hormonal stimulation.

References:

1. Jafarzadeh H, Sanatkhani M, Mohtasham N. Oral pyogenic granuloma: a review. *JOralSci*2006;48:167–75.
2. Pereira CM, de Almeida OP, Correa ME, Souza CA, Barjas-Castro ML. Oral involvement in chronic graft versus host disease: a prospective study of 19 Brazilian patients. *GenDent*2007;55:48–51
3. Bhaskar SN, Jacoway JR. Pyogenic granuloma—Clinical features, incidence, histology, and result of treatment: Report of 242 cases. *J Oral Surg* 24:391, 1966
4. A. Poncet, L. Dor, Botryomycose humaine, *Rev. Chir. (Paris)* 18 (1897) 996.
5. M.B. Hartzell. Granuloma pyogenicum (botryomycosis of French authors). *J. Cutan. Dis.* 22 (1904) 520–523.
6. J. Iwata, H. Sonobe, M. Furihata, E. Ido, Y. Ohtsuki. High frequency of apoptosis in infantile capillary haemangioma. *J. Pathol.* 179 (1996) 403–408.
7. Zain RB, Khoo SP, Yeo JF. Oral pyogenic granuloma (excluding pregnancy tumor)—A clinical analysis of 304 cases. *Singapore Dent J* 20:8, 1995
8. Al-Khateeb T, Ababneh K. Oral pyogenic granuloma in Jordanians: A retrospective analysis of 108 cases. *J Oral Maxillofac Surg* 61:1285, 2003
9. Avelar RL, Antunes AA, Carvalho RWF, et al. Granuloma piogênico oral: Um estudo epidemiológico de 191 casos. *RGO* 56:131, 2008
10. Leyden JJ, Mater GH. Oral cavity pyogenic granuloma. *Arch Dermatol*126: 13 1, 1932

11. Wood NK, Goaz PW. Differential Diagnosis of Oral Lesions (ed 2). St Louis, MO, Mosby, 1980, pp 129-30
12. Swerlick RA, Cooper DH. Pyogenic granuloma (lobular capillary hemangioma) within portwine stains. *J Am Acad Dermatol* 1983;15:627, 1983
13. Kfir Y, Buchner A, Hansen LS. Reactive lesion of the gingiva: A clinopathologic study of 471 cases. *J Periodontol* 1980;51:655-61.
14. Buchner A, Calderon S, Raman Y. Localised hyperplastic lesions of the gingiva: A clinicopathological study of 302 lesions. *J Periodontol* 1977;48:101-4.
15. Skiner RL, Devenport WD Jr, Weir JC, Carr RF. A survey of biopsied oral lesions in paediatric dental patient. *Paediatr Dent* 1986;8:163-7.
16. Patil K, Mahima VG, Lahari K. Extralingival pyogenic granuloma. *Indian Journal of Dental Research* 2006; 17:199-202.
17. Hamid J, Majid S, Nooshin M. Oral pyogenic granuloma: A review. *J Oral Sci* 2006;48:167-75.
18. Yan K, Jin YT, Lin MT. Expression of Tie2, angiopoietin-1, angiopoietin-2, ephrin B2, and Eph B4 in Pyogenic granuloma of human gingiva implicates their role in inflammatory angiogenesis. *J Periodontol Res* 2000;35:165-71.
19. Sato H, Takeda Y, Satoh M. Expression of the endothelial receptor tyrosine kinase Tie2 in lobular capillary hemangioma of the oral mucosa: An immunohistochemical study. *Journal of Oral Pathology and Medicine* 2002; 31:432-438.
20. Fowler EB, Cuenin MF, Thompson SH, Kudryk VL, Bilmann MA. Pyogenic granuloma associated with guided tissue regeneration. A case report. *J Periodontol* 1996;67:1011-5.
21. Amirchaghmaghi M, Farnaz F, Nooshin M, Mozafari PM. Extralingival pyogenic granuloma: A case report. *Cases Journal* 2008; 1:371.
22. Moon SE, Hwang EJ, Cho KH. Treatment of pyogenic granuloma with sodium tetradecyl sulphate sclerotherapy. *Arch Dermatol* 2005;141:644-6.

How to cite this article: Singh H, Singh A, Shukla B, Das G, Agarwal N, Gauravi G S. Pyogenic granuloma (lobular capillary hemangioma) of the Tongue: a case report *JOADMS* 2015;1(3):101-105.
Source of Support: Nil, Conflict of Interest: None declared