

Case Report

Prosthetic Rehabilitation of a Patient with Custom Made Ocular Prosthesis: A Case Report

Prithviraj D R¹, Rachana Srivastava², Satyam Gaur³, Abhishekha Patil⁴, Soundr Raj K⁵, Shruthi DP⁶

¹Dean cum Director, Dept. of Prosthodontics, Govt. Dental college and research institute, Victoria Hospital Campus, Fort, Bangalore, India

^{2,3,4} Post graduate student, Dept. Of Prosthodontics, Govt. Dental college and research institute, Victoria Hospital campus, Fort, Bangalore, India,

⁵Head of the Department, Dept. Of Prosthodontics, Govt. Dental college and research institute, Victoria Hospital campus,

⁶Department of Orthodontics, Dayanand Sagar College of Dental Sciences, Bangalore, India

ARTICLE INFO

Access this article online :



Keywords:

ocular prosthesis, iris, sclera, prosthetic rehabilitation, enucleation

ABSTRACT

Human eyes are the most vibrant component of the facial expression. Loss of the eyes may occur due to several reasons. In few patients, eyes are absent since birth whereas in other patients eyes are removed surgically due to trauma, infection, malignancy and some other conditions which can make the patient physically and emotionally challenged. Prosthodontic rehabilitation of such patients should be done as soon as possible using stock or custom-made ocular prosthesis. The fit and facial esthetics after wearing stock is not satisfactory to the patient hence custom made eye prosthesis should be made. This article describes prosthetic rehabilitation of a patient using custom made eye prosthesis.

Introduction

Eyes are the most important part of our face to be appreciated. The facial impairment due to loss of an eye can make the patient physically, socially and emotionally distressed. Loss of the eyes may be congenital or acquired. The acquired defects include irreparable trauma, malignancy, painful blind eye or sympathetic ophthalmia. Prosthetic rehabilitation of such disabilities should be performed to minimize the psychological trauma in these patients.¹

The ocular prosthesis may be either readymade (stock eye) or custom made. The stock ocular prostheses are available in different sizes and shapes which can be delivered postoperatively or as an intermediate prosthesis.^{2,3} Custom made ocular prosthesis offers better

fit and comfort to the patient compared to the stock eye. These prostheses are fabricated according to the specific anatomy of the individual defect hence there is an improvement in the adaptation of the prosthesis which helps in appreciable mobility, even distribution of pressure over the tissue bed, reduced tissue ulceration and improved facial contours. Size and color of the iris and pupil can be customized according to the individual eye which enhances the esthetics of the ocular prosthesis.⁴

This clinic report demonstrates the technique used for the fabrication of a custom-made ocular prosthesis in a thirty-five-year-old male patient.

Clinical report

A 35-year-old male patient was referred to the Department of Maxillofacial Prosthetics and Implantology at Government dental college and research institute, Bangalore, India for replacement of his missing left eye (fig. 1). The patient gave a history of infection in his left eye 3-years back followed by enucleation of the same. On clinical examination, the socket was healed completely. Intraocular tissue bed was healthy with no sign of inflammation. The patient did not complaint of pain and discomfort. The eyelids were intact with adequate depth of the upper and lower fornices. The patient was wearing a stock eye since few months. The patient was not happy with the fit and esthetics of the eye prosthesis. A custom-made ocular prosthesis was planned for the prosthetic rehabilitation of the patient. The whole procedure was explained to the patient.

Procedure:

1. Before making the impression, the patient was draped and allowed to relax. The eye socket was irrigated with cold saline and petroleum jelly was applied over the eyelids, eyebrows and surrounding soft tissues. Modifications of the overextensions of the stock acrylic tray were made by trimming. The margins of the tray were smoothed and checked in the socket for the proper extension and fit.
2. The irreversible hydrocolloid impression material (Zhermack, Tropicalgin Alginate Impression Material) was mixed and loaded in a 50ml of the disposable syringe. After placing the impression tray into the eye socket, the loaded syringe was attached to the stem of the impression tray. The impression material was injected slowly. The stem of the impression tray should be stabilized while injecting the impression material (fig.2).
3. The patient was asked to perform eye movements. After setting of the impression material, the impression was removed gently from the eye socket, washed and disinfected. The impression surface was checked for the voids and extensions of the borders.
4. "Double alginate technique" was used for the fabrication of the trial ocular prosthesis.⁵ Irreversible hydrocolloid impression material was mixed in thin consistency and poured in a disposable plastic cup. A thin layer of the impression material was applied over the impression surface and it was immersed in the impression material (poured in the cup) completely. The stem of the impression tray should be kept stable until the impression material sets (fig. 3)
5. After setting of the impression material, the alginate mold was removed from the disposable plastic cup along with the impression. The alginate mold was cut partially with the help of a scalpel and blade (fig. 4). The impression along with the impression tray was removed from the alginate mold. The alginate mold was placed back into the plastic cup. The inlay wax was melted and poured into the alginate mold for the fabrication of the wax pattern of the ocular prosthesis (fig. 5)
6. After cooling, the wax pattern was removed from the mold carefully. The wax pattern was shaped and polished for the trial procedure.
7. The trial of the wax pattern was done to check the border extensions, shape, convexity, and fit (fig. 6).

Minor adjustments were done with the help of modeling wax.

- An aluminum button was selected according to the iris size of the right eye. The patient was asked to look slightly medially and downward and an aluminum button was placed over the wax pattern in the normal gaze position (fig.7). The position of the

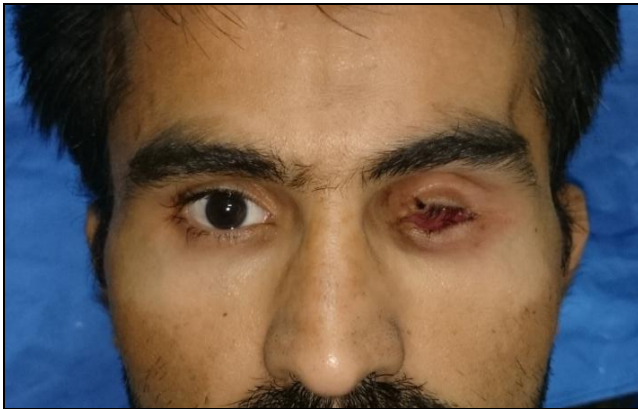

Figure.1 Preoperative photograph

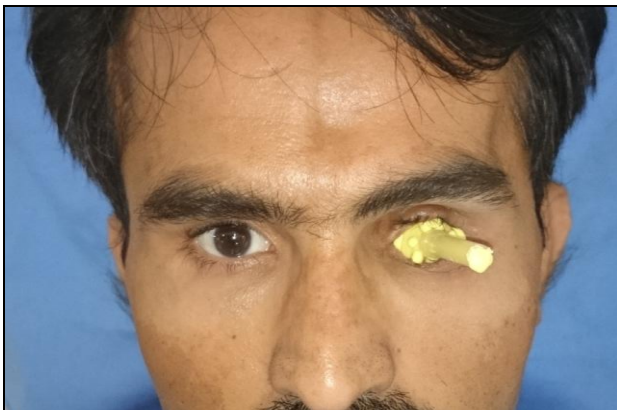

Figure.2 Irreversible hydrocolloid impression of the eye socket using stock tray

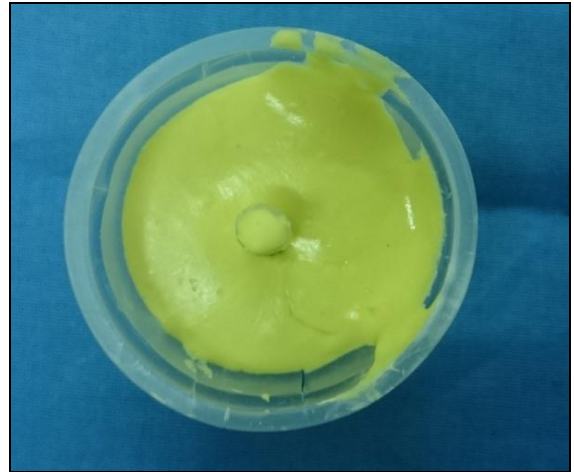


Figure.3 Impression suspended into a plastic cup

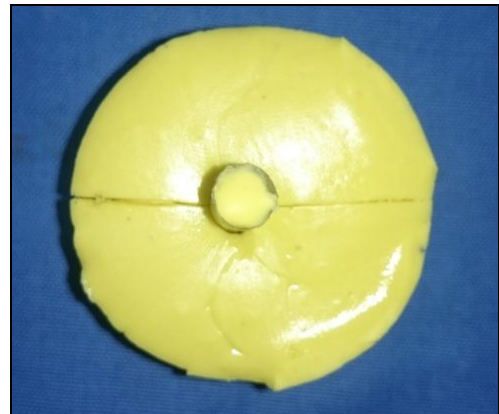


Figure.4 Incision of the mold to retrieve the impression

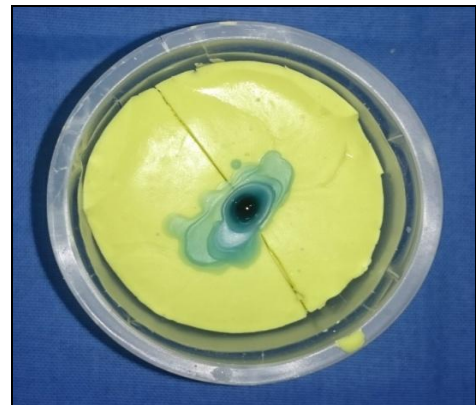


Figure.5 Filling of the mold space with the wax

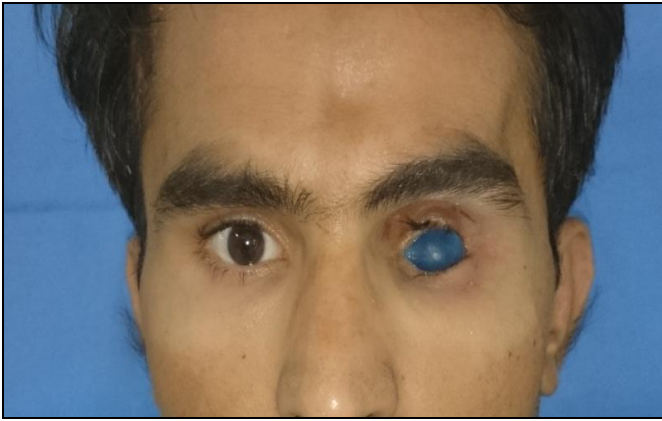


Figure.6 Trial of the wax pattern

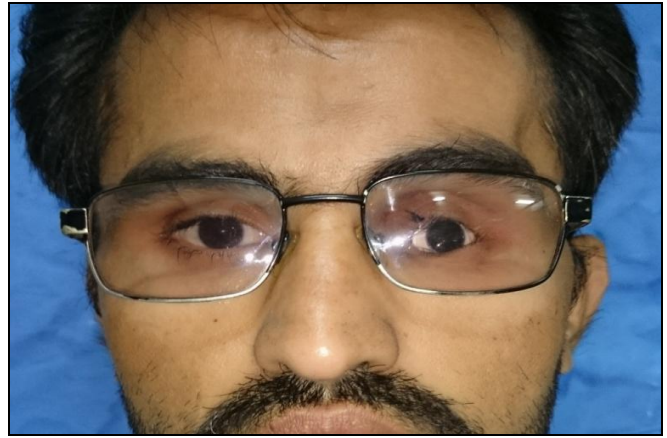

Figure.9 Postoperative photograph




Figure.7 Attachment of the aluminum button to the wax pattern

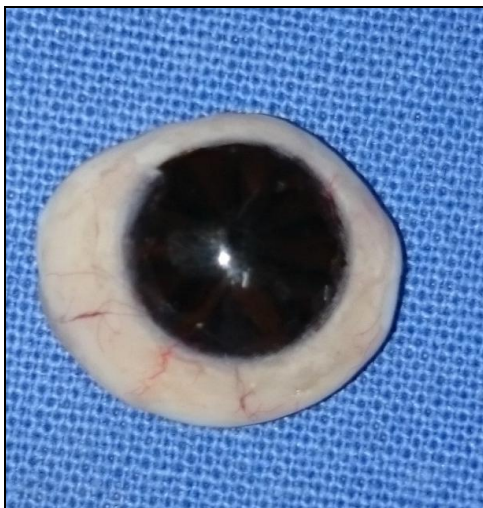

Figure.8 Finished eye prosthesis

aluminum button was checked by watching the movement of the stem attached to the aluminum button and comparing to the natural eye movement.

9. The wax pattern was flaked along with the aluminum button. An iris button (ethylcellulose iris disc) corresponding to the size of the aluminum button was selected and painted according to the patient's right eye. After dewaxing the aluminum button was replaced with iris button and the rest of the mold space was filled with white colored heat cure acrylic material.
10. After completion of the curing, the prosthesis was removed. 1.0mm of the acrylic was trimmed from the scleral surface for the addition of the clear acrylic layer.
11. The sclera part of the prosthesis was colored according to the color of the patient's natural eye. Red woolen fibers were used to simulate blood vessels in the eye. The color of the prosthesis was checked after putting a drop of water over the scleral surface.

12. The prosthesis was heated in water and boiled for 2 minutes for the polymerization of the colors used for sclera painting. After boiling the prosthesis, it was cooled at room temperature. This cycle was repeated for 10-15 times.
13. The prosthesis was placed in the mold and packed with a thin layer of clear acrylic using the same flask. A thin layer of cellophane sheet was placed between the prosthesis and the clear acrylic to protect the colors from the monomer. After 10 minutes, the cellophane sheet was removed and final closure of the flask was done.
14. After curing, finishing and polishing of the prosthesis was done (fig. 8). Disinfection of the prosthesis was performed using 0.5% chlorhexidine and 70% isopropyl alcohol for 5 minutes. The final prosthesis was inserted into the left eye socket of the patient (fig.9).
15. Post insertion instructions were given to the patient regarding the insertion and removal of the prosthesis. The patient was advised to keep the prosthesis in water or contact lens soaking solution at room temperature. Use of mild soap or detergent was advised for the cleaning of the prosthesis.⁶
16. Periodic recall appointments were scheduled after 1 week, 3 weeks and one month after the insertion of the prosthesis.

Discussion

The prime goal of an ocular prosthesis is to restore the esthetics and psychological well-being of the patient. Stock and Custom made ocular prosthesis are the two

treatment modalities available for the prosthetic rehabilitation of an ophthalmic eye socket. Custom made ocular prosthesis is a good alternative compared to stock eye prosthesis. There are several disadvantages associated with stock eye prosthesis such as poor fitting and esthetics of the prosthesis, poor eye movements and irritation of the soft tissue due to poor adaptation of the prosthesis. Custom made eye prosthesis is used to overcome these shortcomings of the stock eye prosthesis.⁷ Although fabrication of a custom made eye prosthesis is a time-consuming procedure, it provides the better fit, retention and comfort to the patient. The iris and sclera are customized according to the natural eye of the patient hence it produces more esthetics and satisfaction to the patient.⁸

Summary

The custom made eye prosthesis is acceptable functionally and esthetically to the patients. The lifelike appearance and the ability to perform eye movements help to restore the mental health and confidence of the patient.

References

1. Artopoulou II, Montgomery PC, Wesley PJ, Lemon JC. Digital imaging in the fabrication of ocular prostheses. *J Prosthet Dent* 2006; 95: 327-30.
2. Goel BS, Kumar D. Evaluation of ocular prosthesis. *J All India Ophthalmol Soc.* 1969; 17: 266 - 9.
3. Kale E, Mese A, Izgi AD. A technique for fabrication of an interim ocular prosthesis. *J Prosthodont* 2008; 17: 654-61.
4. Ow RK, Amrith S. Ocular Prosthetics: Use of tissue conditioner material to modify stock ocular prosthesis. *J Prosthet Dent* 1997; 78: 218-22.

5. Mathews MF, Smith RM, Sutton AJ et al. The ocular impression: a review of literature and presentation of an alternate technique. *J Prosthodont* 2000; 9: 210-6.
6. Parr GR, Goldman BM, Rahn AO. Postinsertion care of the ocular prosthesis. *J Prosthet Dent*. 1983; 49: 220-4.
7. Cain JR. Custom ocular prosthesis. *J Prosthet Dent* 1982; 48: 690-4.
8. Gupta RK, Padmanabhan TV. Prosthetic Rehabilitation of a Post Evisceration Patient with Custom Made Ocular Prosthesis: A Case Report. *J Indian Prosthodont Soc* 2012; 12: 108-12.

How to cite this article:

Prithviraj D R , Srivastava R, Gaur S, Patil A, Raj S K, Shruthi DP. Prosthetic Rehabilitation of a Patient with Custom Made Ocular Prosthesis: A Case Report *JOADMS* 2015; 1(3):70-75.

Source of Support: Nil,

Conflict of Interest: None declared