

## Case Report

### Treatment of Skeletal Class II Malocclusion with Twin-block

Prasad V Bonde<sup>1</sup>, Veerendra V Kerudi<sup>2</sup>, Neeraj Patil<sup>3</sup>, Siddhesh G Dolas<sup>4</sup>, Harshal A Patil<sup>5</sup>

<sup>1,4,5</sup> Post Graduate Student, <sup>2,3</sup> Professor, Department Of Orthodontics, ACPM Dental College, Dhule, Maharashtra, India

#### ARTICLE INFO

Access this article online :



Keywords:

Twin block, Functional appliance

#### ABSTRACT

Aim of this case report was to see the effect of twin block in permanent dentition phase. Functional appliances can be used successfully in growing patient with Class II malocclusion. It is dependent on patient's compliance. It also simplifies the fixed appliance phase. A 14-year-old boy was treated with twin block appliance. The design of appliance and treatment results were demonstrated in following case report. In permanent dentition, twin block produce similar effect as in mixed dentition phase. With proper case selection and good patient cooperation, we can obtain a significant result with twin block appliance.

#### Introduction

Class II malocclusion, one of the most commonly observed problem in orthodontics, affects approximately one-third of the patients seeking orthodontic treatment.<sup>1,3</sup> Patients with Class II malocclusions can exhibit maxillary protrusion, mandibular retrusion, or both, together with abnormal dental relationships and profile discrepancy.<sup>4</sup> According to McNamara,<sup>5</sup> mandibular retrusion is the most common characteristic of this malocclusion.

In growing patients with Class II malocclusions due to mandibular retrusion, removable and fixed functional appliances are used to stimulate the mandibular growth by forward positioning of the mandible.<sup>6-9</sup> In 1982, Clark described the twin block appliance. In United

Kingdom, it was one of the popular functional appliances. Many evidences suggest that it may be considered as one of the most successful appliances for the treatment of skeletal Class II malocclusions.

The following is a case report of 14-year-old boy treated with twin block appliance.

#### CASE REPORT

A 14-year-old boy came to the department having a chief complaint of upper front teeth placed forwardly. On extra-oral examination, the patient has a convex profile, incompetent lips with an interlabial gap of 4 mm, acute nasolabial angle, receded chin position and deep mentolabial sulcus, and average growth pattern. On intra-oral examination, it showed class 2 molar relation

\* Corresponding author. Dr. Prasad V. Bonde, New Area Ward, Bhusawal, Maharashtra-425201 Ph no : +918308824399

and canine relation bilaterally, overjet of 9.5 mm, overbite of 4 mm and upper and lower midline coincide with the facial midline. The pretreatment intra-oral and extra-oral photographs are shown in Figure 1.

The case was diagnosed as Class II skeletal malocclusion with mandibular deficiency. Cephalometric analysis shows skeletal class 2 sagittal relationship and average growth pattern and mandibular retrusion. Evaluation of patient's cervical radiograph indicated that he had considerable amount of growth remaining. In addition, patient was showing positive visual treatment objective (VTO). The pretreatment radiographs of the patient are shown in Figure 2.

### TREATMENT OBJECTIVES

1. Reduction of profile convexity and lip incompetence.
2. Correction of molar and canine relation
3. Achievement of normal overjet and overbite.

### TREATMENT PLAN

As the patient had skeletal and dental Class II relationship and cervical radiograph indicated that he had considerable amount of growth remaining, growth modification was planned using functional appliance followed by fixed orthodontic appliance for final detailing of occlusion. Twin block was fabricated for a patient as shown in figure 3. As to prevent further proclination of lower incisors, incisal capping was done. After 13 months period of wear, the significant improvement was noted in profile and lip competency. Significant correction in molar and the canine relation was obtained along with significant reduction in overjet and overbite. Post-functional intra-oral and extra-oral photographs are shown in Figure 4. The post-functional radiographs are shown in Figure 5.

**Table 1 : Pre- and post- functional appliance cephalometric measurements**

Variables	Pretreatment	Post functional appliance
<b>Skeletal Variables</b>		
SNA (°)	82	82
SNB (°)	78	81
ANB (°)	4	1
FMA (°)	31	30
IMPA (°)	104	103
<b>Dental Variables</b>		
U1-L1 (°)	107	113
U1-SN (°)	119	117
U1-NA (mm)	12	11
U1-NA (°)	37	35
LI-NB (mm)	8	7
LI-NB (°)	33	32
<b>Soft Tissue Variable</b>		
Nasolabial angle (°)	109	107

### DISCUSSION

Class II malocclusion might have any number of a combination of skeletal and dental component. Hence, identifying and understanding etiology and expression of Class II malocclusion and identifying differential diagnosis helpful for its correction and to select treatment planning whether functional, orthodontic or surgical.<sup>10</sup>

Clark's twin block is a functional appliance, which effectively modify occlusal inclined plane which induce favorably directed occlusal force by causing a mandibular displacement.<sup>11,12</sup> It allows masticatory function. Patient can wear appliance full time with little discomfort. Other

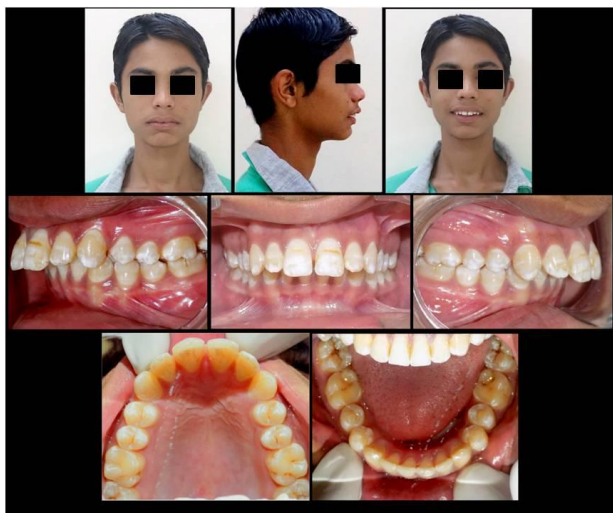

Fig 1- The pretreatment intra-oral and extra-oral photographs

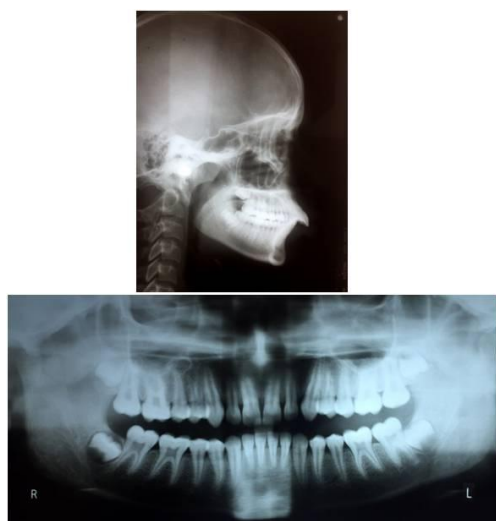


Fig 2- The pretreatment radiographs

advantages include esthetic, easy to repair. It is suitable for mixed dentition as well as deciduous dentition.<sup>13</sup> There were several studies where they have documented the ability of twin block to produce significant skeletal as well as dentoalveolar changes which in combination correct Class II malocclusion.<sup>14,15</sup>



Fig 3- Twin Block Appliance

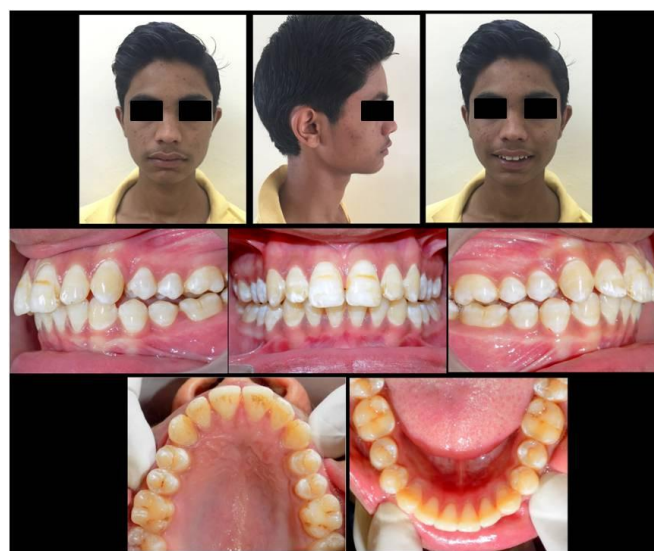

Fig 4 - The post functional intra-oral and extra-oral photographs

Here, comparison of pre-treatment and post-treatment lateral cephalogram showed SNA remained unchanged, and SNB increased by 3°. ANB angle reduced up to 3°. Inclination of maxillary incisors remains same and length of the mandible is increased by 3mm. The values of selected parameters before and after functional appliance therapy are shown in Table 1.

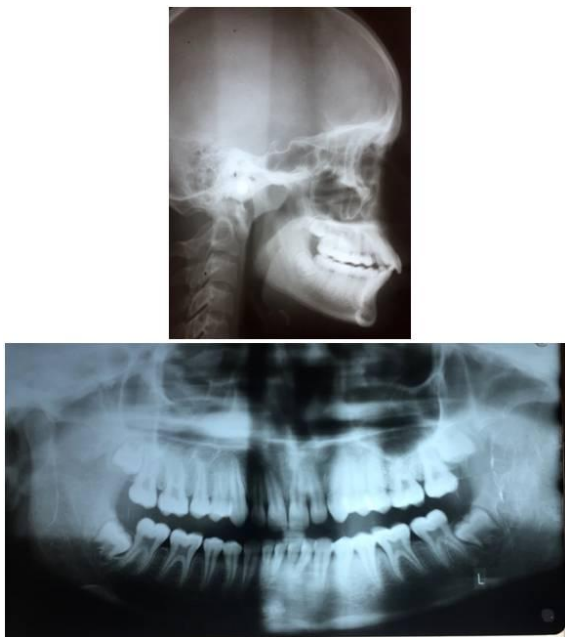


Fig 5- The post-functional radiographs

## CONCLUSION

Effect of twin block depends upon patient's compliance and case selection. Use of this appliance during growing phase with good patient co-operation produce the skeletal effect, and some dentoalveolar effect is also there.

## REFERENCES

1. Proffit WR, Fields HW Jr, Moray LJ. Prevalence of malocclusion and orthodontic treatment need in the United States: estimates from the NHANES III survey. *Int J Adult Orthodon Orthognath Surg.* 1998; 13:97–106.
2. Gelgor IE, Karaman AI, Ercan E. Prevalence of malocclusion among adolescents in central Anatolia. *Eur J Dent.* 2007; 1:125–131.
3. Celikoglu M, Akpınar S, Yavuz I. The pattern of malocclusion in a sample of orthodontic patients from Turkey. *Med Oral Patol Oral Cir Bucal.* 2010; 15:e791–e796.
4. Arici S, Akan H, Yakubov K, Arici N. Effects of fixed functional appliance treatment on the temporomandibular joint. *Am J Orthod Dentofacial Orthop.* 2008; 133:809–814.
5. McNamara JA Jr. Components of Class II malocclusion in children 8–10 years of age. *Angle Orthod.* 1981; 51:177–202.
6. Karacay S, Akin E, Olmez H, Gurton AU, Sagdic D. Forsus Nitinol Flat Spring and Jasper Jumper corrections of Class II division 1 malocclusions. *Angle Orthod.* 2006; 76:666–672.
7. Jones G, Buschang PH, Kim KB, Oliver DR. Class II nonextraction patients treated with the Forsus Fatigue Resistant Device versus intermaxillary elastics. *Angle Orthod.* 2008; 78:332–338.
8. Gunay EA, Arun T, Nalbantgil D. Evaluation of the immediate dentofacial changes in late adolescent patients treated with the Forsus FRD. *Eur J Dent.* 2011; 5:423–432.
9. Oztoprak MO, Nalbantgil D, Uyanlar A, Arun T. A cephalometric comparative study of Class II correction with Sabbagh Universal Spring (SUS(2)) and Forsus FRD appliances. *Eur J Dent.* 2012; 6:302–310.

10. Sharma NS. Management of growing skeletal class II patient: A case report. *Int J Clin Paediatr Dent* 2013; 6:48-54.
11. Clark WJ. The twin block traction technique. *Eur J Orthod* 1982; 4:129-38.
12. Clark WJ. The twin block technique: a functional orthopedic appliance system. *Am J Orthod Dentofacial Orthop* 1988; 93:1-18.
13. Al-Anezi SA. Class II malocclusion treatment using combined Twin Block and fixed orthodontic appliances - A case report. *Saudi Dent J* 2011; 23:43-51.
14. Trenouth MJ. A comparison of twin block, Andresen and removable appliances in the treatment of Class II Division 1 malocclusion. *Funct Orthod* 1992; 9:26-31.
15. Trenouth MJ. Cephalometric evaluation of the Twin-block appliance in the treatment of Class II Division 1 malocclusion with matched normative growth data. *Am J Orthod Dentofacial Orthop* 2000; 117:54-9.

**How to cite this article:** Bonde PV, Kerudi V V, Patil N, Dolas S G, Patil H A. Treatment of Skeletal Class II Malocclusion with Twin-block. *JOADMS* 2015;1(3):57-61.  
Source of Support: Nil, Conflict of Interest: None declared