

**Short Communication****Clinical and Imaging Evaluation of Third Molars: A Review**Shikha mandal<sup>1</sup>, Mayank Pahadia<sup>2</sup>, Shashank Sahu<sup>3</sup>, Aditya Joshi<sup>4</sup>, Deep Suryawanshi<sup>5</sup>, Alpana Tiwari<sup>6</sup><sup>1</sup> Private Practitioner<sup>2</sup> Post Graduate Student, Dept of Oral Medicine and Radiology, SAIMS Dental College, Indore, India<sup>3</sup> Post Graduate Student, Dept of Pedodontics, RCDS & RC Bhopal, India<sup>4,5</sup> Post Graduate Student, Dept of Orthodontics, RCDS & RC, Bhopal, India<sup>6</sup> Post Graduate Student, Dept of Oral Medicine and Radiology, Peoples Dental Academy, Bhopal, India

## ARTICLE INFO



Keywords:

Third molar, CBCT, Panoramic Imaging

## ABSTRACT

Third Molars are thought to have once been essential for early human ancestors in order to efficiently chew and digest the food necessary for normal human diet and development. Due to evolutionary changes and societal advancements, human diets gradually became less plant based, jaw sizes became smaller and the functional requirement and need for the third molars reduced drastically. Although third molars have similarities with other teeth, they are significantly different in many ways. They have less functionality and a greater frequency of disease process than other teeth. Successful evaluation and management of third molars requires a comprehensive history and physical examination in conjunction with an appropriate radiographic analysis. Clinical examination can be important aids for the treatment planning as well as preoperative medical management and the importance of imaging modalities in the management of third molars, facilitating surgical planning and overall patient education cannot be overstated.

**Introduction**

Third Molars are thought to have once been a necessity for early human ancestors in order to efficiently chew and digest the cellulose that comprised the plant foliage, which was an integral part of the dietary intake.

Due to evolutionary changes and societal advancements, human diets are less plant based, jaw sizes have become smaller and the functional requirement and need for the third molars has become minimal.<sup>1</sup>

Although third molars have similarities with other teeth in the dental, especially the molars, they are significantly different in many ways. They have less functionality and a greater frequency of disease process than other teeth.

Third molars are termed “Wisdom” teeth from the British theory that as these teeth generally erupt in the late teen years or early 20s, it may refer to the concept that complete cognitive development of the human brain does not occur until approximately the same age.

**Clinical Evaluation***History*

A complete history should be obtained before the physical examination, starting with a patient’s chief complaint and history of present illness, which guide the examination and ultimately the treatment.

Furthermore, this step triages patients, differentiating elective from more urgent patients, such as one with an odontogenic abscess. For instance, does the patient have pain, drainage, or swelling? As with any surgical patient, a patient’s past medical history, past surgical history, medications, allergies, and social history should be thoroughly obtained. A past anesthesia history should be discussed as well. Significant comorbidities, anticoagulation, specific medication allergies, and severe dental phobia may alter the treatment algorithm and is critical to patient safety and care.

\* Corresponding author. Dr. Shashank Sahu, Dept. of Pedodontics, Rishiraj College of Dental Sciences, Bhopal, India. Email: shashank30.sahu@gmail.com

### *Physical Examination*

#### *General*

A thorough head and neck examination should be completed as part of the third molar evaluation.

The Temporomandibular joint should be assessed to evaluate for any pretreatment findings of TMDs, such as clicking, popping, crepitus, laxity, and tenderness to palpation.

Such information is important so as to take necessary precaution if surgery is planned and to document pre-existing conditions and avoid attributing any TMDs to surgical removal of the third molars.

Next, the examination should evaluate for signs of infection, such as edema, erythema and any asymmetry, and the neck should undergo palpation to assess for any lymphadenopathy.

Intraoral examination should include a thorough inspection of the oral cavity and focus on the third molar areas.

#### *Third molar specific*

Clinical examination of the third molar areas should first assess for whether the third molars are visible in the oral cavity and whether the teeth are impacted or simply not present, because third molar agenesis occurs in up to 20% of patients.<sup>2</sup>

Once confirmed present and if not completely impacted, the examination should assess for potential disease states as well as difficulty of access and surgical removal of the third molar teeth.

Examination findings to note as related to third molars:

- Periodontal disease
- Dental caries

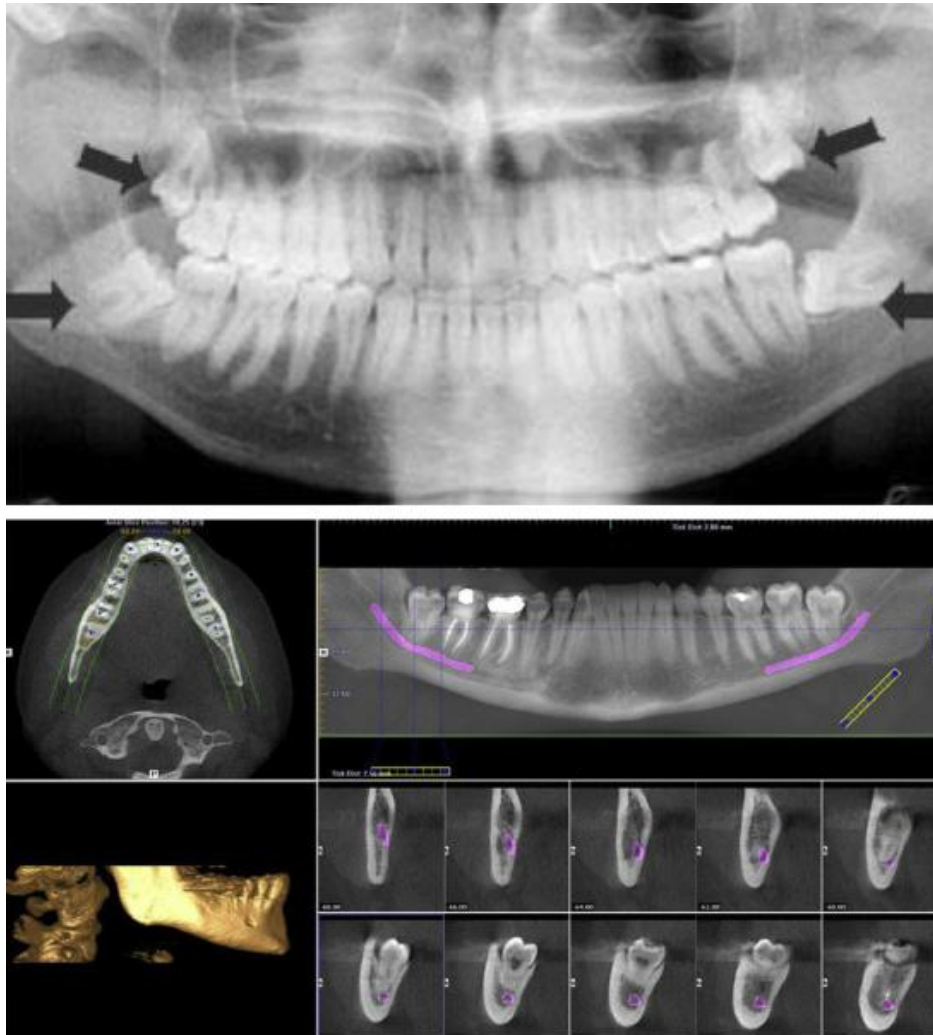
- Pericoronitis
- Second molar or adjacent tooth resorption
- First or second molar caries as a predictor for development of third molar caries<sup>3</sup>
- Associated cysts or tumor growth
- Crowding of anterior dentition
- Presence of an oral prosthesis

Findings to note as related to surgical access and third molar surgery:

- Body mass index
- Trismus
- Cheek laxity
- Macroglossia

#### **Radiographic Analysis**

The management of third molars consists of radiographic evaluation of dentofacial structures and the third molars in particular. Imaging is particularly important because it augments the evaluation by providing further information as to the size, shape, and position of the teeth and their relationship to the surrounding structures. Furthermore, the presence of associated pathology, which has been reported to occur in up to 10% of patients, may be determined.<sup>4</sup> Also, technical considerations regarding the surgical removal may be addressed. Specifically, the relationship of the mandibular third molars to the inferior alveolar canal and the maxillary third molars to the maxillary sinus may be appreciated, providing teaching points for the patient and risk stratification regarding postoperative issues, such as nerve injury, jawfracture, or oral-antral communications. In cases of impaction, which has been reported to occur in more than 50% of patients, imaging may be the only means to evaluate these teeth.<sup>5</sup>



**Figure 1: (Upper) 2-D orthopantomogram demonstrating wisdom teeth. (Lower) 3-D CBCT with particular emphasis on the inferior alveolar can and its relationship to the third molar mandibular teeth. (Courtesy of Department of Oral Medicine and Radiology, Sri Aurobindo College of Dentistry, Indore, Madhya Pradesh, India)**

As for the imaging modality itself, some debate has developed over the use of CT versus the orthopantomogram, which has been the standard imaging technique for evaluating third molars. The primary impetus behind the use of imaging other than the orthopantomogram is an effort to decrease the frequency of inferior alveolar nerve injury after third molar removal. Specifically, nerve injury associated with third molar extraction has been reported to occur in up to 7% percent of patients<sup>6</sup> and it has been suggested that this can be greatly reduced, especially in high risk patients,

via the use of 3-D, enhanced detail imaging, allowing for superior preoperative diagnostic assessment.<sup>7</sup> Furthermore, accuracy of third molar angulation is of importance in surgical planning.

Dudhia<sup>8</sup> reconfirmed the presence of distortional inaccuracies with orthopantomograms or panoramic imaging secondary to projection geometry creating discrepancies in angular measurements. Simply, the panoramic image results in the mandibular third molars appearing less mesially inclined, which can have both treatment planning and surgical implications. Digital

panoramic images offer significantly greater diagnostic precision over conventional panoramic images but ultimately create only a 2-D image of a 3-D anatomic area.<sup>9</sup> As a result, studies, such as the one by Bouquet and colleagues,<sup>10</sup> demonstrated the intuitive conclusion that CT offers increased anatomic precision over orthopantomography but with a significant

neurovascular bundle exposure during extraction of impacted third molar teeth (Fig. 1). Specifically, CBCT scanners use narrow, collimated conical radiation beam geometry coupled to 3-D reconstruction algorithms.

The result is the generation of an accurate and large volume of data in a short scanning interval.<sup>13</sup> In addition, Ghaemini and colleagues<sup>14</sup> reported that CBCT elucidated the 3-D relationship of the third molar root to the mandibular canal and allowed for buccolingual appreciation of the inferior alveolar nerve (see Fig. 1). Furthermore, even MRI has been proposed by Tymoflyeva and colleagues<sup>15</sup> as an alternative imaging option for impacted teeth because it results in volumetric morphology while eliminating ionizing radiation, which is especially important in younger patients.

#### Radiographic Assessment of Surgical Difficulty of Removal of Impacted Third Molars

Orthopantomogram specific<sup>16</sup>:

- Root number
- Root morphology
- Tooth position
- Second molar relation
- Size of follicular sac
- Periodontal ligament space

increase in radiation exposure and cost. The advent of cone-beam CT technology (CBCT) has resulted in imaging with decreased radiation exposures and intraoffice practicality versus the medical-grade CT scanners.<sup>11</sup>

Tantanapornkul and colleagues<sup>12</sup> demonstrated the CBCT to be superior to panoramic imaging in predicting

Panoramic radiographic risk factors for inferior alveolar nerve injury<sup>17</sup>:

- Diversion of the inferior alveolar canal
- Darkening of the third molar root
- Interruption of the cortical white line

#### Classification systems

Evaluation of third molars historically includes radiographic classification systems based on third molar angulation, the relationship to the anterior border of the ramus, and the relationship to the occlusal plane.

Such systems allow for more clear communication amongst clinicians as well as further assessment of surgical difficulty and specific surgical techniques for removal.

#### Angulation

Archer (1975)<sup>18</sup> and later Kruger (1984)<sup>19</sup> pioneered the angulation classification based on the radiographic position of the third molars. The angulations include:

- Mesioangular—least difficult removal and most common for mandibular third molars
- Distoangular—least difficult removal for maxillary third molars
- Vertical—most common for maxillary third molars
- Horizontal
- Buccal version

- Lingual version
- Inverted

#### *Relationship to the Anterior Border of the Ramus*

The Pell and Gregory classification originated in 1933 and was designed to assess impacted third molars, with particular focus on the relationship to the ramus and the occlusal plane (Fig. 2)<sup>20</sup>.

The relationship to the ramus is based on the amount of the impacted tooth that is covered by bone of the mandibular ramus. This suggests the potential likelihood of eruption as well as surgical difficulty with removal. Simply, as the third molar becomes increasingly covered by the ramus, the surgical difficulty increases. Three classes exist:

Class 1: The distance between the second molar and the anterior border of the ramus is greater than the mesiodistal diameter of the crown of the impacted tooth, so that its extraction does not require bone removal from the region of the ramus.

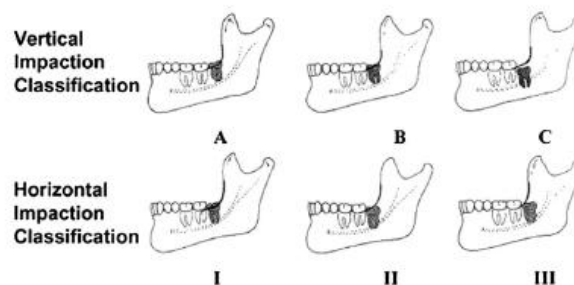
Class 2: The distance is less and the existing space is less than the mesiodistal diameter of the crown of the impacted tooth.

Class 3: There is no room between the second molar and the anterior border of the ramus, so that the entire impacted tooth or part of it is embedded in the ramus.

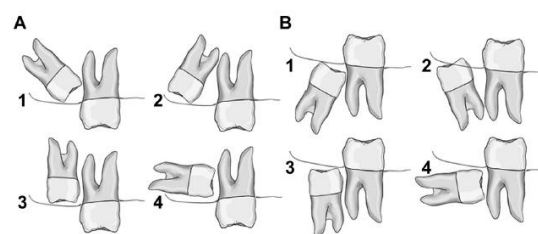
#### *Relationship to the Occlusal Plane*

The occlusal plane analysis was also created by Pell and Gregory to address the depth of impaction or amount of overlying bone with application to further assessment of surgical extraction difficulty.<sup>19</sup>

Similar to the relationship to ramus classification, the relationship to the occlusal plane exists in 3 forms and deeper impactions are typically more difficult to surgically remove:



**Figure 2: Composite Pell and Gregory classification of third molar impactions, addressing third molar relationship to the mandibular ramus as well as depth of impaction.**



**Fig. 3. Angulation classification of impacted teeth. (A) Maxillary third molar impactions: mesioangular (1), Distoangular (2), Vertical (3) and Horizontal (4). (B) Mandibular third molar impactions : mesioangular (1), distoangular (2), Vertical (3), and Horizontal (4).**

Class A: The occlusal surface of the impacted tooth is at the same level as, or a little below, that of the second molar.

Class B: The occlusal surface of the impacted tooth is at the middle of the crown of the second molar or at the same level as the cervical line.

Class C: The occlusal surface of the impacted tooth is below the cervical line of the second molar.

Furthermore, a composite relationship of angulation, ramus relationship, and depth of impaction can provide a surgical extraction difficulty index, as described by Pederson (Table 1).<sup>21</sup>

**Table 1: Pederson's difficulty index for impacted mandibular third molar removal as a composite of angulation, depth of impaction, and ramus relationship**

<u>Classification</u>	<u>Value</u>
Spatial relationship	
Mesioangular	1
Horizontal/transverse	2
Vertical	3
Distoangular	4
Depth	
Level A: high occlusal level	1
Level B: medium occlusal level	2
Level C: deep occlusal level	3
Ramus relationship/space available	
Class I: Sufficient Space	1
Class II: Reduced Space	2
Class III: No Space	3
Difficulty Index	
Very Difficult	7-10
Moderately Difficult	5-6
Slightly Difficult	3-4

#### *Other Methods*

Winter lines, root division, and WHARFE (Winter's classification, Height of the mandible,

Angulation of second molar, Root shape and morphology, Follicle development, Exit path)

assessment are additional radiographic-assisted techniques for third molar evaluation and subsequent management (Fig. 3).<sup>22</sup>

#### **Summary**

Successful third molar management requires a comprehensive history and physical examination in conjunction with an appropriate radiographic analysis. Clinical examination can guide treatment options as well as perioperative medical management and the imaging modality is essential in the management of third molars, facilitating surgical planning, informed consent, and overall patient education.

#### **References**

1. Johnson GB. Evidence for evolution. Txtwriter Inc; 2006.
2. Vastardis H. The genetics of human tooth agenesis: new discoveries for understanding dental anomalies. *Am J Orthod Dentofacial Orthop* 2000;117(6):650–6.
3. Shugars D, Elter J, Jacks M, et al. Incidence of occlusal dental caries in asymptomatic third molars. *J Oral Maxillofac Surg* 2005;63:341–6.
4. Guven O, Keskin A, Akal U. The incidence of cysts and tumors around impacted third molars. *Int J Oral Maxillofac Surg* 2000;29(2):131–5.
5. Bishara S, Andreasen G. Third molars: a review. *Am J Orthod* 1983;83(2):131–7.
6. Khan I, Halli R, Gadre P, et al. Correlation of panoramic radiographs and spiral CT scan in the preoperative assessment of intimacy of the inferior alveolar canal to impacted mandibular third molars. *J Craniofac Surg* 2011;22:566–70.
7. White R. AAOMS white paper on third molar data. Rosemont (IL): AAOMS; 2007:1–25.
8. Dudhia R, Monsour P, Savage N. Accuracy of angular measurements and assessment of distortion in the mandibular third molar region on panoramic

- radiographs. *Oral Surg Oral Med Oral Pathol Oral Radiol Endod* 2011;111:508–16.
9. Ferrus-Torres E, Gargallo-Albiol J, Berini-Aytes L, et al. Diagnostic predictability of digital versus conventional panoramic radiographs in the presurgical evaluation of impacted mandibular third molars. *Int J Oral Maxillofac Surg* 2009;38:1184–7.
10. Bouquet A, Coudert J, Bourgeois D, et al. Contributions of reformatted computed tomography and panoramic radiography in the localization of third molars relative to the maxillary sinus. *Oral Surg Oral Med Oral Pathol Oral Radiol Endod* 2004;98:342–7.
11. Miracle A, Mukherji S. Conebeam CT of the head and neck, part 2: clinical applications. *AJNR Am J Neuroradiol* 2009;30:1285–92.
12. Tantanapornkul W, Okouchi K, Fujiwara Y, et al. A comparative study of cone-beam computed tomography and conventional panoramic radiography in assessing the topographic relationship between the mandibular canal and the impacted third molars. *Oral Surg Oral Med Oral Pathol Oral Radiol Endod* 2007;103:253–9.
13. Miracle A, Mukherji S. Conebeam CT of the head and neck, part 1: physical principles. *AJNR Am J Neuroradiol* 2009;30:1088–95.
14. Ghaeminia H, Meijer G, Soehardi A. Position of the impacted third molar in relation to the mandibular canal. Diagnostic accuracy of cone beam computed tomography compared with panoramic radiography. *Int J Oral Maxillofac Surg* 2009;38:964–71.
15. Tymofiyeva O, Rottner K, Jakob P. Three-dimensional localization of impacted teeth using magnetic resonance imaging. *Clin Oral Investig* 2010;14:169–76.
16. Varvalho R, Vasconcelos B. Assessment of factors associated with surgical difficulty during removal of impacted lower third molars. *J Oral Maxillofac Surg* 2011;69:2714–21.
17. Blaeser B, August M, Donoff R, et al. Panoramic radiographic risk factors for inferior alveolar nerve injury after third molar extraction. *J Oral Maxillofac Surg* 2003;61:417–21.
18. Archer W. *Oral and maxillofacial surgery*. 5th edition. Philadelphia: Saunders; 1975.
19. Kruger GO. *Oral & Maxillofacial Surgery*. 6th Edition. St Louis (MO): Mosby; 1984.
20. Pell G, Gregory B. Impacted mandibular third molars: classification and modified techniques for removal. *Dent Dig* 1993;39:330–8.
21. Pedersen G. *Surgical removal of teeth*. Oral surgery. Philadelphia: Saunders; 1988.
22. Winter G. *Impacted mandibular third molars*. St Louis (MO): American Medical Book Co; 1926.

**How to cite this article:** Mandal S, Pahadia M, Sahu S, Joshi A, Suryawanshi D, Tiwari A. Clinical and Imaging Evaluation Of Third Molars: A Review. *JOADMS* 2015;1(3):3-9.  
Source of Support: Nil, Conflict of Interest: None declared