



CASE REPORT

Flangeless over denture with preci-clix attachment- a case report

Sumit Singh¹, Abhinav Shekhar², Anshuman Chaturvedi³

^{1,3}Post Graduate Student, Department of Prosthodontics, Sardar Patel Post Graduate Institute of Dental and Medical Sciences, Lucknow

²Reader, Department of Prosthodontics, Sardar Patel Post Graduate Institute of Dental and Medical Sciences, Lucknow

ARTICLE INFO

Article history:

Received 9th Aug 2015

Accepted 20th Aug 2015

Keywords:

Overdenture, Abutment tooth, Preci-clix attachment, Preventive Prosthodontics

ABSTRACT

With increasing stress on preventive prosthodontics, the use of over dentures has reached a point where it is now a feasible alternative to most treatment plan. Outlines in the construction of a prosthesis for patients with remaining teeth. The overdenture, a complete or partial denture prosthesis constructed over existing teeth or root structure, is not a new concept in a technical approach to a prosthodontic problem. Indeed its use dates back to 100 years. According to GPT-8, It is defined as “Any removable dental prosthesis that covers or rests on one or more remaining natural teeth, the roots of natural teeth ,and/or dental implants; a dental prosthesis that covers and is partially supported by natural teeth, natural tooth roots, and/or dental implants”. The major advantage of an over denture is that it maintains proprioception of teeth and improve stability and retention. Overdenture is preventive prosthodontics concept involving the multidisciplinary approach involving periodontal, endodontic & prosthodontics intervention. Prefabricated attachments are versatile and provide considerable retention and stability.

Introduction

According to recent definition of overdenture it is defined as “An over-denture is defined as a removable partial denture or complete denture that covers and rests on one or more remaining natural teeth, the roots of natural teeth and/or dental implants; a prosthesis that covers and is partially supported by natural teeth, natural tooth roots and/or dental implants.”^[1]

Overdentures are also known by various names

such as an overlay denture, telescopic denture, tooth supported dentures, hybrid prosthesis, crown and sleeve prosthesis, and the superimposing dentures.^[2]

Primary concept of Preventive prosthodontics is to conserve the few remaining natural teeth. There are two physiologic importance related to this therapy. The first theory is concerned about the continued preservation of alveolar bone around the retained teeth^[3] while the

* Corresponding author: Dr.Sumit Singh., Department of Prosthodontics Sardar Patel Post Graduate Institute Of Dental And Medical Sciences, Lucknow Email :sumit.singh.dr@gmail.com

second theory relates to the continuing presence of periodontal sensory mechanisms^[4] that guide and monitor gnatho-dynamic functions. Studies have shown that saving teeth will preserve the proprioceptive mechanism in the jaws, thereby preserving the alveolar bone^[5]. Certain special modified complete denture procedures have been developed and overdenture is one of the logical methods for the dentists to use in preventive prosthodontics. Ball and socket devices have become popular now days, because of reduced laboratory procedure in over denture treatment^[6]. In this case report preci-clix over denture system is used to rehabilitate the maxillary arch.

CASE REPORT

A 58 years old female patient reported to the department of Prosthodontics and crown and bridge, with the complaint of missing teeth because of which she was unable to chew food properly. And had bad look. The patient is a social worker by profession and was concerned mainly about the retention of the prosthesis because her previous dentures were ill fitting. Her medical history was non contributory. On extra-oral examination the patient had a concave profile with ovoid face form, and TMJ had no abnormality. On intra-oral examination, she had completely edentulous and favorable mandibular arch and also a moderately favorable maxillary arch with retained 13 and

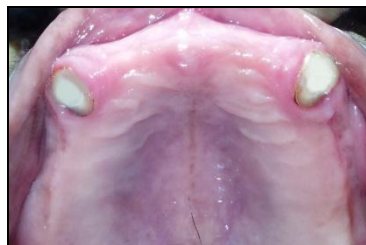

Fig 1: After RCT and crown preparation crown reduction

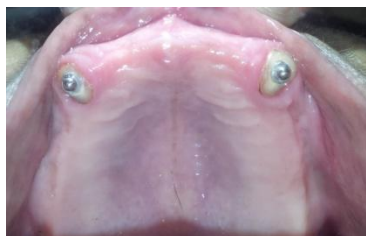

Fig 2: Cementation of posts

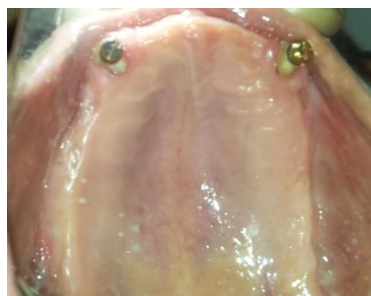

Fig 3: Post analogues were cemented before secondary impression

23, which were firm and had good soft tissue attachment and an ideal maxillary distance of 18.5mm. Routine clinical and radiographic examination(OPG & IOPA) was followed. Considering the patients chief complain as well as the condition of the oral cavity, overdentures with attachments in the maxillary arch was planned out for her, because of the presence of a deep under cut in the anterior region of maxilla in the alveolar process region bilaterally, therefore, it was decided that the maxillary denture will be flangeless, as the denture with a flange will




Fig4: Black rubber spacer, retention cap, metal housing

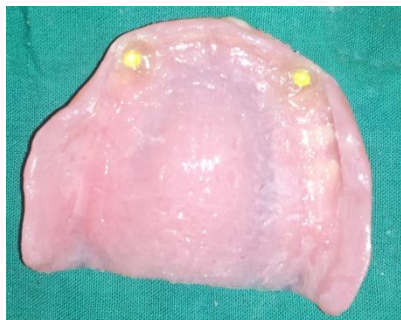

Fig 5: Intaglio surface of final denture with metal housing and retention caps

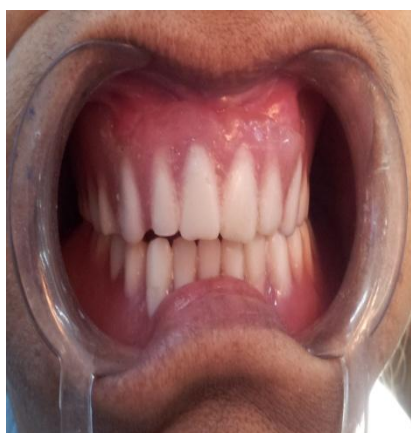

Fig 6: Flangeless denture with preci-clix attachment

cause over contouring and compromised esthetics. Also denture prosthesis may cause interferences due to unfavourable path of insertion and removal . Out of the available options for attachments Ceka Preci-Clix attachments were chosen for the maxillary teeth 13 and 23 because the Preci-clix female

component engages all around the sphere or ball for an increased area of retention and it audibly CLICKS into place providing very positive retention. A thorough oral prophylaxis was done followed with intentional RCT of 13 and 23 was done in the department of Endodontics. After a period of 15 days prosthodontic phase/restorative phase was started [6].

STEP 1- Preparation of the teeth

According to Angle's classification of the inter arch distance, the patient exhibited an Angle's Class I ridge relation with an ideal 18.5mm inter-arch distance. After completion of the root canal treatment in the Endodontics department the teeth 13 and 23 were reduced at the level of the gingiva that is equi-gingivally and all the sharp edges were reduced as well as the tooth structure was rounded up. (*Figure 1*)

STEP 2- Root preparation for post placement

Root canals were prepared at slow speed with No. 1227 pre-drilling bur. Then No. 1228 cavity bur was used to prepare the canal (to facilitate countersinking) and finally with No. 1229 precision reamer (to calibrate the canal for the diameter of No. 1291 post). Post (Ceka Preci-Clix RC Post) was sandblasted before cementation which is provided with attachment kit. Bonding resin composite (Flourocore 2+, DENTSPLY Caulk) was coated over the post

and root canal surface and Preci-Clix post was seated in the prepared canal. Then at the surface of tooth the composite was cured with light curing unit. After the composite was set, the root surface on which the post is cemented was polished with the finishing burs. (*Figure 2*)

STEP 3- Impression making

Preliminary impression was made using irreversible hydrocolloid impression material. Impressions were poured in Type II dental plaster(DENTSPLY regular setting) and diagnostic casts were obtained, both maxillary and mandibular. Acrylic special tray(DPI RR Cold Cure) prepared on primary cast by giving two layer thick spacer (4mm) around the posts. After this, sectional incremental border molding of the tray was done with (DPI Pinnacle Tracing Sticks) Type II low fusing impression compound material. The spacer was removed and vent holes were made in the tray. Secondary (Final) impression was made with monophasic rubber base impression material.(DENTSPLY Aquasil monophasic) No. 1201D post analogue were re-indexed into the recess within the impression and master casts was made. (*Figure 3*)

STEP 4- Jaw relation and trial of denture

Metal housing with retention caps were placed over the posts on the cast. Next, metal housing was blocked out with wax and record base was

fabricated. Occlusion rims were prepared and the jaw relation was recorded. Teeth arrangement was completed and try in of the denture was done to check for centric relation, vertical dimension and esthetics. The investing and flasking was done conventionally and after de-waxing the analogue were blocked out and denture was fabricated in conventional manner. (*Figure 5*)

STEP 5- Insertion of denture

Black rubber spacers supplied in the kit were placed over the post that is the male component. The female component retention caps and metal housing were placed over the posts. The denture was placed over female components and rechecked for any interference (*Figure 4*). The prosthesis was relieved until there was no interference and proper occlusion with even tissue contact. It was made sure that the prosthesis had no contact with attachment or abutment. Small amount of self cure resin was placed in relieved area of the prosthesis and seated in the mouth and was allowed to set. Before the resin was completely set, the denture was removed out and the intaglio surface of the denture that had metal housing with retention caps deep buried within. The denture was then finished and polished. Black rubber spacer removed. The advantage of this system is the female retention caps can be easily changed in metal housing to adjust the

retention. The denture was inserted and post insertion instructions were given . Patient was recalled after 24 hrs for check-up. (**Figure 6**)

DISCUSSION

Of all the attachments present, the ball and socket type of attachments are the most user friendly for the patient as well as, have much better denture stability, retention and higher chewing efficiency because of proprioception. The snap fit of the denture in mouth makes the patient more comfortable during functional movements^[6]. Tooth supported over-denture is a viable and tissue tested alternative technique for those who cannot have implants due to various reasons like medical contraindications, cost factors and also for patients who are not willing for the implants^[7]. Use of remaining natural teeth for supporting the dentures is always aimed at reducing the load, stresses on the osseous structures of the denture bearing areas and also to minimize the process of resorption when the dentures are worn^[6]. The anterior flange portion of the maxillary denture was removed as it was causing over contouring of the patient's face and was not looking esthetically good ; hence the anterior flange from maxillary left canine to maxillary right canine portion was removed. The psychological advantage resulting from the dental anchorage, which allows the patient to be more confident

in social life, is also relevant. Finally, when the dental support is lost, converting over-denture into complete denture is simple and quick, and makes easier the longitudinal clinical maintenance of the denture^[8].

REFERENCES

1. Glossary of prosthodontic terms. Journal of Prosthetic Dentistry, Volume 94, Issue 1, Pages 10-92.
2. Henking JP. Overdentures. J Dent 1982;10:217
3. Prince IB. Conservation of the supporting mechanism. J Prosthet Dent 1965;15:327.
4. Yalisove IL. Crown and sleeve-coping retainers for removable partial prosthesis. J Prosthet Dent 1966; 16:1069-85
5. Crum R, Loisel R. Oral perception and proprioception: A review of the literature and its significance to prosthodontists. J Prosthet Dent 1972; 28: 215-30
6. Rajendra B Hallikerimath. Prosthodontic Rehabilitation with Preci-Clix Overdenture System - A case report. IJCDS Nov 2010 ;1(1):73-76.
7. Hallikerimath RB, Patil V, Magadam S. Prosthodontic Rehabilitation with Preci-Clix Overdenture System - A case report. Int. Journal of Clinical Dental Science 2010;1:73-76

-
8. Scotti R, Melilli D, Pizzo G. Overdenture supported by natural teeth: analysis of clinical advantages. *Minerva Stomatol.* 2003;52:201-210.

How to cite this article: Singh S, Shekhar A, Chaturvedi A. Flangeless over denture with preclic attachment- a case report. *JOADMS* 2015;1(2):43-48.
Source of Support: Nil, Conflict of Interest: None declared