

Case Report

Tooth Jewellery – Brightening Smiles the World Over

Abhijeet Buragohain

Junior Resident, Department of Dentistry, Assam Medical College and Hospital, Dibrugarh, Assam, India

ARTICLE INFO



Keywords:

Dental jewellery, Cosmetic dental treatment, Dental rings, Dental tattoo

ABSTRACT

The nature of fashion is constantly changing and this act applies to dentistry. Dental treatments are now enhancing basic attitude of a healthy life and accordingly fashion aspects are further gaining incorporated into it. The need of intraoral jewellery and piercings of oral and perioral tissues have been gaining demand among adolescents and young adults. Dental jewellery is a cosmetic dental procedure wherein diamond or another stone is adhered to the tooth surface. This method is non-invasive and with less side effects. So being a dentist of 21st century, we should have the idea of new advances in addition to routine therapeutic procedures. This case report adds a brief sketch of tooth jewellery which adds a sparkle to the smile.

INTRODUCTION

Esthetics has become an essential form of dentistry over the past few years and has led to the advancement of modern materials and techniques. People are now a days becoming more self-conscious about their appearance and smile. Body decoration has also attained influence with wearing of jewellery. Thus being the latest trend, tooth jewellery turns into a manifestation of increasing the order of living of an individual in the society.^[1] With the preface of cosmetic dental treatments like porcelain veneering, composite veneering, bleaching and placing of tooth jewellery, a patient smile can be made more attractive, engaging and aesthetic. Tooth jewellery is a non-invasive, painless method with less of side-effects. It is not a costly procedure with amount differs according to the type of the jewel which is to be placed and depends upon clinic to clinic.^[2] Hence, tooth jewellery is

one form of self-expression and when placed perfectly it certainly adds a beautiful rare smile.

TOOTH JEWELLERY

A small precious gem which is adhered to a tooth surface. Many different forms of jewellery designs are available to choose and express the smile. Jewels are only 0.4 mm – 0.9 mm thick and 1.8 mm – 3.0 mm in diameter. They are temporary or can last as long as we need or may be for 6 months or up to few years.^[3]

Different brands of tooth jewellery are available in the market including Skyce (Ivoclar, Vivadent AG, Schann, Liechtenstein), Twinkle (Twindent AB, Uppsala, Sweden). They are rather attached on upper incisors and canine teeth using composite resin cement just for cosmetic design.

* Corresponding author: **Dr. Abhijeet Buragohain**, Junior Resident, Department of Dentistry, Assam Medical College and Hospital, Dibrugarh, Assam, India.

PROCEDURE

Selection of patient and tooth jewellery

The teeth to which the jewel is to be adhered should be healthy. They should be advised to deal with their assumption and know that the dental jewellery will be a brand new symbolic part of their look. The tooth jewellery used is Skyce. (Figure.1)

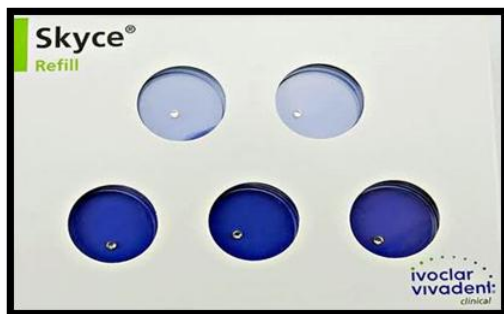


Fig. 1: Skyce (Ivoclar, Vivadent)

Application Procedure^[4]

After oral hygiene, the tooth is rinsed with fluoride free polishing paste.

The tooth is then dried and isolated with rubber dam.

The tooth is etched with 37% phosphoric acid for about 15–20 seconds to enhance the surface area for bonding. Later on the enamel is treated with topical fluoride to remineralize the etched area. (Figure.2)

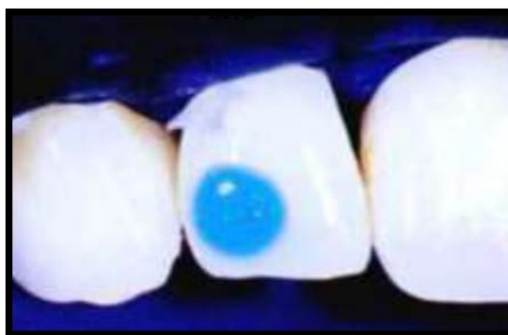

Fig. 2: Etching of tooth

Cleaning the surface thoroughly with water for 1 minute and blow dry for 10 seconds such that no etchant should remain on the tooth surface.

Bonding agent (Heliobond) is applied and then light curing is done for 20 seconds. (Figure.3)



Fig. 3: Heliobond (Ivoclar, Vivadent)

Small amount of flowable composite (Te-Econom Flow) is applied on the tooth surface. (Figure.4)

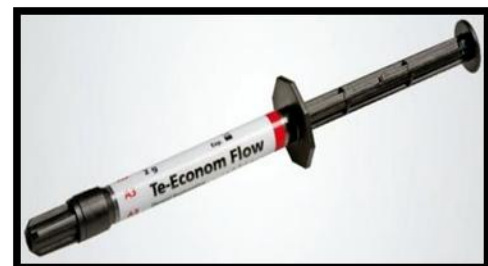

Fig. 4: Te-Econom Flow (Ivoclar, Vivadent)

A jewel handler is used to easily grasp up the jewel and hold it into the center of the composite.

Now we can fix the jewel, while letting the patient verify the desired position in the mirror.

Light curing the composite from all the sides for total of 180 seconds and making sure the composite hardens uniformly. (Figure.5)

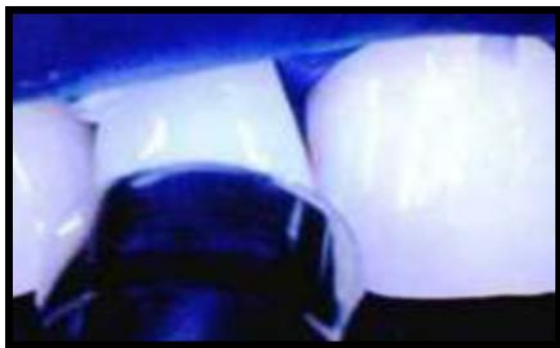

Fig. 5: Light curing is done from all sides

The entire time for jewel to set onto the composite is 20 seconds and takes about 4 minutes to safely fasten the jewel. (Figure.6 and Figure.7)

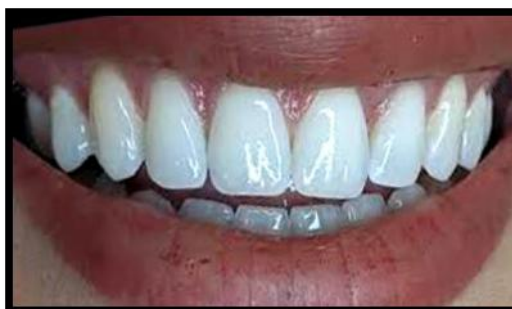

Figure 6: Before Placement

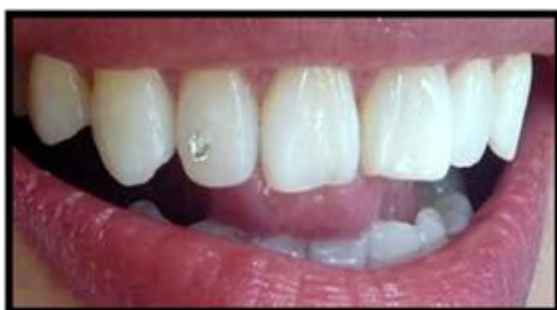

Fig. 7: After Placement

Post-operative instructions^[5]

Patient should be advised that it might take few hours for them to get used to the jewel in the mouth and to sustain good oral hygiene.

Hard brushing, eating sticky and hard foods should be minimized to some extent as it might get debonded if more stress is applied at bonding interface.

So, patient is instructed about these to take care before and after tooth jewellery procedure.

Steps to be followed after removal^[6]

The dental jewellery is detached the same manner as an orthodontic bracket without enamel breakage.

After being the removal of gem, the tooth is polished which takes aside any remaining bonding materials.

While remaining the same, one should use a scaler or a rubber polisher.

If in case of any leftover bonding or composite on the tooth, just easily remove it by using a polishing tool.

It is necessary to treat the tooth with fluoride, so that the remineralization and stabilization of the enamel is administered.

COMPLICATIONS^[7-8]

Though it has not plenty of side effects, aside from interim sensitivity of the teeth caused by the acid.

In case of poor oral hygiene, there is prone for plaque accumulation and ideal growth for caries bacteria.

It may get debonded, if extra stress is enforced at bonding interface due to hard brushing, eating hard and sticky foods, then it may lost or may go to digestive tract or respiratory tract which needs medical emergency.

It can also be an obstruction pathway, while taking x-ray for complete oral examination.

CONCLUSION

Tooth jewellery has emerged as a current fashion trend. Today, dentistry is not only defined to treat dental problems or diseases only but also to achieve ample concern when matter comes on looking dazzling or beautiful.^[9] Tooth jewellery is believed to adorn the presence of a person and adds more allure and gleam to the smile. Only individuals with good oral care should be advised the need of these jewels. Thus, dentists should make patients familiar of the possible complications of piercings and should tell them the effect of proper oral hygiene.^[10]

REFERENCES

1. Jeger F, Lussi A, Zimmerli B. Oral jewellery: A review. *Schweiz Monatsschr Zahnmed.* 2004; 111(11):615-31.
2. Patil AG. Tooth jewellery: A simple way to add sparkle to your smile. *Ind J Dent Advance.* 2010; 2(4):356-358.
3. Vazhiyodan A, Mohan S, Vizhi GK, Khan R. Sparkling smile. *Jident.* 2013; 1(1):1-3.
4. Peter T, Titus S, Francis G, Alani MM, George AJ. Ornamental Dentistry- An overview. *Journal of evolution of media and dental sciences.* 2013; 2(7):666-676.
5. Kaur H, Jain P, Dutta K. Dental enhancements and tattoos:- Current Trends in Aesthetic Dentistry. *International journal of research in dentistry.* 2014; 4(3):48-53.
6. Jaybala B, Dhruvi P, Arpit P, Darmina J. Fashion trends in dentistry. *Journal of research in medical and dental sciences.* 2014; 2(1):102-104.
7. Sharma M, Sharma RK, Upadhyay M, Mishra P. Making a Fashion Statement with Dental Jewellery. *I J Pre Clin Dent Res.* 2014; 1(3):53-55.
8. Bhatia S, Gupta N, Gupta P, Arora V, Mehta N. Tooth Jewellery: Fashion and Dentistry go Hand in Hand. *Indian J Dent Adv.* 2015; 7(4):263-267.
9. Sonal *et al.* Tooth Jewellery – Knowledge among Dentists. *Journal of Clinical and Diagnostic Research.* 2016; 10(3):32-35.
10. Monisha N, Ganapathy D, Sheeba SP, Kanniappan N. Dental Jewellery - A review. *Journal of Pharmacy Research.* 2018; 12(1):73-75.