

## Case Report

# Clinical management of Invasive Cervical Resorption using combination of internal and external approach- A case report

Sneha R. Dole<sup>1</sup>, Desai N<sup>2</sup>, Shah D<sup>3</sup>, Sharma M<sup>4</sup>, Patil G<sup>5</sup>, Sonvane B<sup>6</sup>

<sup>1</sup>PG Student, Dept of Conservative Dentistry and Endodontics, SDCH, Pune, India

<sup>2</sup>MDS, Professor, SDCH, Pune, India

<sup>3</sup>MDS, Prof and Head, SDCH, Pune, India

<sup>4</sup>MDS, Assistant Prof, SMBT, IDSR, Nashik, India

<sup>5</sup>PG Student, SDCH, Pune, India

<sup>6</sup>PG Student, SDCH, Pune, India

## ARTICLE INFO



### Keywords:

Invasive cervical resorption, Resin modified GIC, Mineral trioxide aggregate (MTA), Trichloroacetic acid (TCA)

## ABSTRACT

Invasive cervical resorption (ICR) of dental tissue is a rare pathology which has been associated with various predisposing factors including dental trauma, caries, periodontal infections, excessive heat generated during restorative procedures on vital teeth, calcium hydroxide procedures etc. It is not well understood within the dental community and is often undiagnosed or remains misdiagnosed. This case describes the management of a maxillary central incisor with ICR in a 28-year-old male patient where root canal treatment, endodontic surgery, mineral trioxide aggregate (MTA) and resin modified glass ionomer cement (RMGIC) were used to repair and restore the function.

## INTRODUCTION

Invasive cervical resorption (ICR) is a clinical term which used to describe an, insidious and aggressive form of external tooth resorption, which occurs in any tooth in the permanent dentition. <sup>1</sup> Although common, ICR is not well understood within the dental practitioners and is undiagnosed or often misdiagnosed. In spite of correct diagnosis, there is often confusion about the best course of treatment, within the endodontic community.<sup>2</sup>

A wide number of etiologic factors have been associated with ICR, including dental trauma, caries, periodontal infections, excessive heat generated during restorative

procedures on vital teeth, calcium hydroxide procedures, non-vital tooth bleaching, orthodontic treatment, or idiopathic dystrophic changes within normal pulps. <sup>2</sup> Resorption of coronal dentin and enamel often creates a clinically visible pinkish hue in the tooth crown due to the presence of as highly vascular resorptive granulation that is seen through thin residual enamel. In other cases detection may be accidental while examining routine radiographs. The condition is usually painless unless there is superimposed secondary infection in which case symptoms may arise.<sup>3</sup>

\* Corresponding author: **Dr. Sneha R. Dole**, PG Student, Dept of Conservative Dentistry and Endodontics, SDCH, Pune, India.

The various other terms used for ICR include odontoclastoma, idiopathic external resorption, fibrous dysplasia of teeth, burrowing resorption, peripheral cervical resorption, late cervical resorption, cervical external resorption, extra-canal invasive resorption, supraosseous extra-canal invasive resorption, peripheral inflammatory root resorption, invasive cervical resorption, subepithelial inflammatory root resorption, periodontal infection resorption, or simply cervical resorption.<sup>1</sup>

### CLINICAL REPORT

A 28-year-old male patient reported to the Department of Conservative Dentistry and Endodontics with complaint of pain in the upper anterior region of jaw since last 8 months and broken front tooth. Patient gave history of trauma 4-5 years back. Clinical examination revealed a discolored 11 and fractured 12 (Elli's Type IV). Both teeth were tender on percussion. Overall patient had good oral hygiene. Pulp sensibility test revealed that both 11 and 21 were non-vital. Radiographic examination revealed moth eaten appearance in cervical and middle third of the root canal. Based on clinical and radiographic examination it was tentatively diagnosed as a case of invasive cervical resorption with apical periodontitis w.r.t. 11. Tooth 12 presented poor post-restorative prognosis and was extracted.

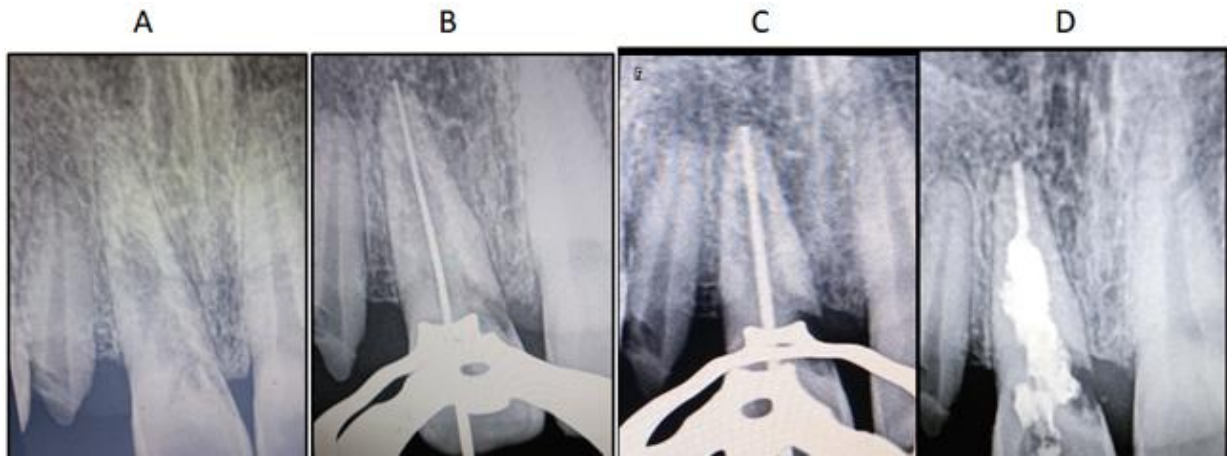
Treatment options were discussed with the patient. These were (1) surgical exposure of the lesion, debridement, and restoration with endodontics, (2) observation of the tooth followed by extraction of the tooth when it becomes symptomatic, (3) extraction followed by prosthetic rehabilitation. After some discussion, the patient decided to go ahead with treatment option 1.

During the first visit, the tooth was isolated with rubber dam under adequate anaesthesia and endodontic access was performed. The working length was established at 24.5 mm (Ingle's technique) (Fig-1B). Afterwards, chemomechanical preparation using the hybrid technique was performed with circumferential filling using 2% taper K files and Gates Gliden (GG) drills. Preparation was done till master apical file ISO number 60 (Fig-1B). Preparation was always performed under irrigation with 3% sodium hypochlorite (NaOCl) solution. A calcium hydroxide paste (Calcein, Tehnodent), was applied as an intracanal medicament dressing, and the tooth was provisionally restored with cavite (3M ESPE). After every 2 weeks days, the calcium hydroxide paste was replaced. This treatment with calcium hydroxide was continued for 6 months.

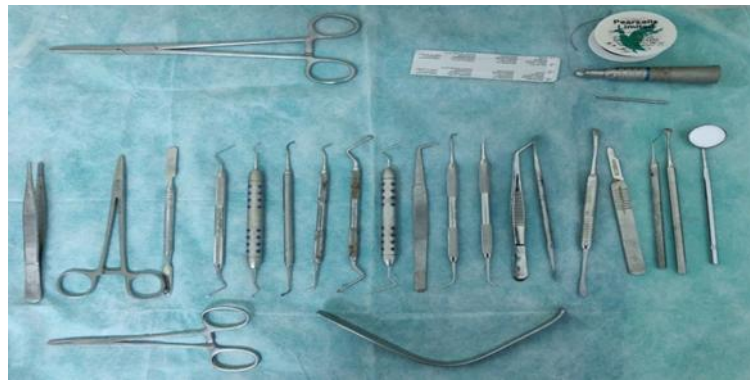During the next visit, calcium hydroxide was removed from the canal using ultrasonic activation and the canal was irrigated copiously with 3% NaOCl (Septodont). Following which 17% EDTA (Prime) was used for 1 minute to remove smear layer. No more bleeding was evident in the canal and hence the apical third of root canal was obturated with gutta-percha using sectional obturation technique. The remaining canal was obturated using MTA (Dentsply) (Fig-1D). After 24 hours the resorption defect was opened surgically. A full thickness flap was elevated which exposed the granulation tissue and the bone destruction (Fig-3A). The granulation tissue was excavated using curette, and the irregular borders of the perforation site were smoothed with a large round bur attached to a straight surgical handpiece. All the visible resorptive tissue was removed until clean dentin was seen. The dentin was then scrubbed with 90% TCA (Trichloroacetic acid) applied on a cotton ball for 60 seconds (Fig-3B). The defect was then irrigated with saline and packed with MTA followed by repair of the

cervical defect with RMGIC. After radiographic examination the flap was approximated and sutured using 3-0 silk (Fig-4B). Post-operative instructions were given to the patients following which suture removal was

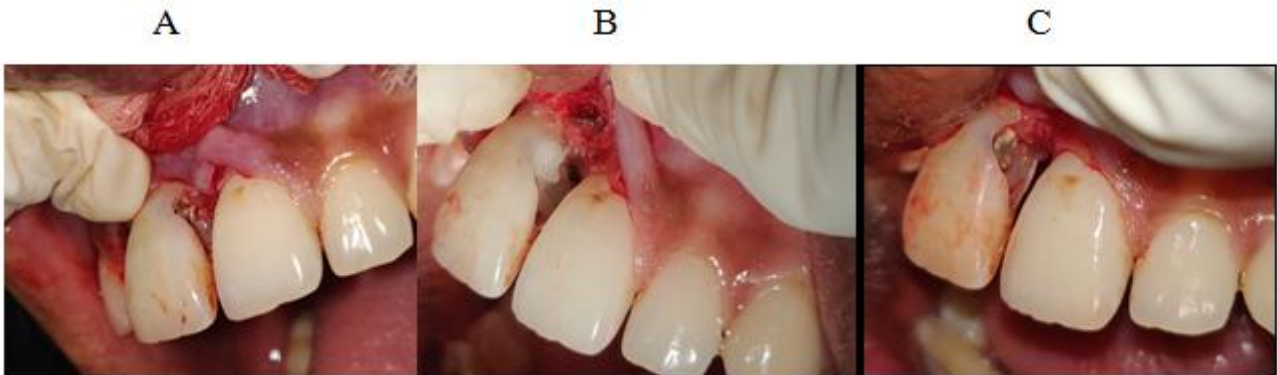carried out after 7 days along with post endodontic restoration with composite resin (Fig-4C). The patient was called for follow up after 3 month.



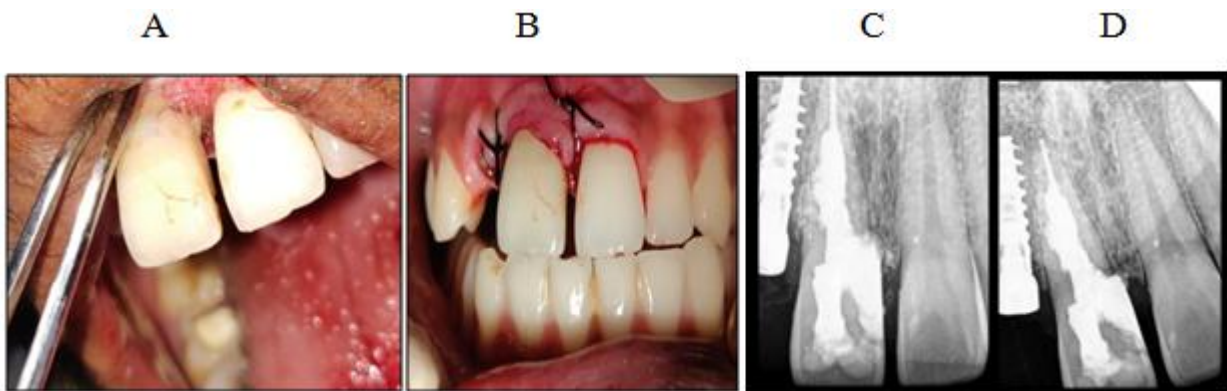
**Fig. 1:** A- Pre operative IOPA of 11, B- IOPA showing determination of working length using Ingle's technique, C- IOPA with master apical gutta percha cone, D- IOPA showing completely obturated root canal with Gutta percha and MTA



**Fig. 2:** Figure showing surgical instruments used during external surgery of ICR



**Fig. 3:** A- figure showing ICR defect, B- figure showing application of TCA (trichloroacetic acid), C- showing defect after removal of granulation tissue

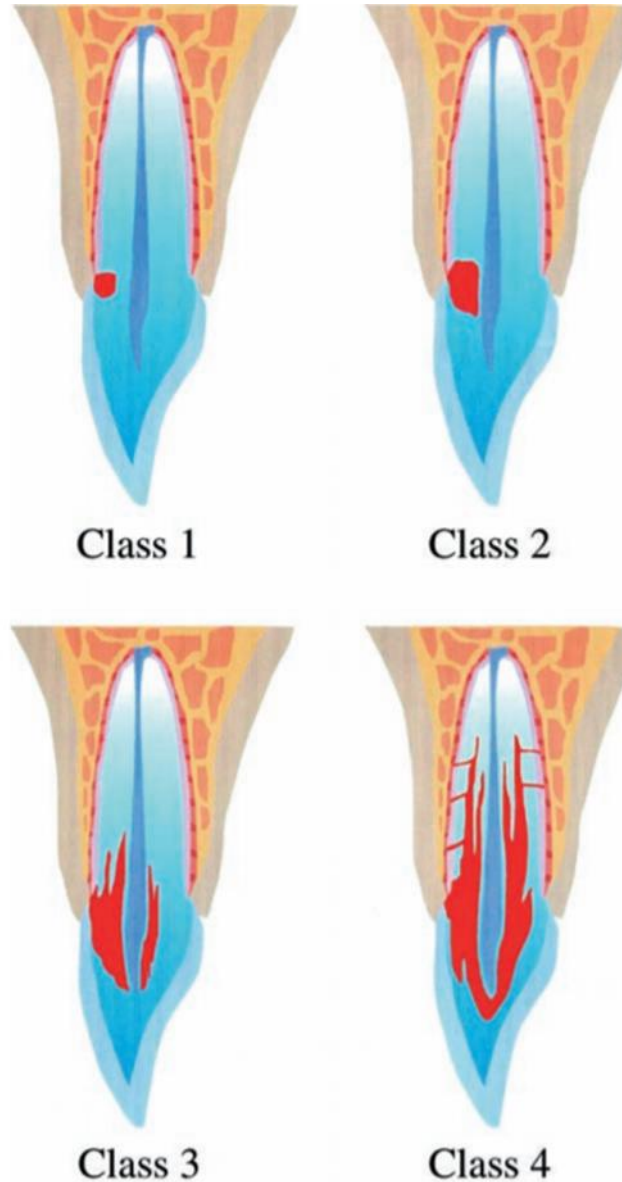


**Fig. 4:** A-showing repair of defect using RMGIC, B- post-operative picture with sutures, C-post operative IOPA showing repair of defect, D- 3 month follow up X-ray showing complete repair of defect

## DISCUSSION

ICR represents a challenge for dental practitioners. The treatment depends on the extent, location and the size of resorptive defect.

A clinical classification has been developed by Heithersay for research that provides a clinical guide in the assessment of cases of invasive cervical resorption.<sup>3</sup> The diagrammatic representation of this classification is shown below (Fig-5).



**Fig. 5:** Class 1 – Denotes a small invasive resorptive lesion near the cervical area with shallow penetration into dentin. Class 2 – Denotes a well-defined invasive resorptive lesion that has penetrated close to the coronal pulp chamber but shows little or no extension into the radicular dentin. Class 3 – Denotes a deeper invasion of dentine by resorbing tissue, not only involving the coronal dentin but also extending into the coronal third of the root. Class 4 – Denotes a large invasive resorptive process that has extended beyond the coronal third of the root.<sup>3</sup>

Resorption of teeth results from the activation of clastic cells, termed odontoclasts, which are morphologically similar, to osteoclasts.<sup>1</sup>

In this particular case a combination of internal and external approach was made to treat the ICR.

Calcium hydroxide was used as an intracanal medicament because of its antibacterial property, and has been shown to effectively eradicate bacteria that persist after chemomechanical instrumentation. This is in accordance with case reports published by Andreason et al who suggested use of calcium hydroxide to depress osteoclastic activity by increasing the pH of root canal. Calcium hydroxide has a synergistic effect when used in conjunction with sodium hypochlorite to eliminate organic debris from the root.<sup>4</sup>

MTA is one of the most biocompatible sealing material available and has been shown to be effective in repairing furcation perforations,<sup>5</sup> lateral root perforations,<sup>6</sup> and in the treatment of large periapical lesions.<sup>7</sup> MTA is well-tolerated by periradicular tissues and has been shown to induce complete regeneration of the periodontium.<sup>5</sup> MTA has superior sealing, mechanical and biological properties when compared with other materials.<sup>8</sup> In this case hybrid technique was also be used to obturate canals; the canal apical to the resorption defect is obturated with gutta-percha, and then the resorption defect is sealed with MTA.<sup>4</sup>

90% aqueous solution of trichloroacetic acid (TCA) was used in this case as suggested by Heithersay et al 1999 which causes coagulation necrosis of the resorptive tissue without damaging the periodontal tissue. TCA penetrates small channels of resorption that are not accessible to and cannot be removed through mechanical instrumentation.<sup>9</sup> TCA is very caustic and causes burns when it comes in contact with the gingival tissues.<sup>2</sup> Dentin that has been treated with TCA becomes severely demineralized and is not suitable for bonding with either dentin-bonding agents or glass ionomer materials. This demineralized dentin must be “refreshed” with a bur before bonding procedures.<sup>2</sup>

Other treatment options for treating ICR include orthodontic extrusion. Extrusion provides better access to ICR lesions and permits the final bony and gingival architecture to be more ideal when surgery is necessary.<sup>2</sup> Purely internal treatment of ICR is always preferable when possible. Although it is impossible to totally eliminate the resorption from inside the tooth, careful mechanical and chemical debridement can stop the resorptive process and result in long-term success as shown with patient. This approach is viable only if the external surface of the tooth remains grossly intact.<sup>2</sup>

### CONCLUSION

Proper management of ICR needs knowledge and skills in endodontics and restorative dentistry. The treatment procedure provides better results when treated under magnification aids for better elimination of resorptive defects. The endodontist must be knowledgeable of all aspects of the treatment to direct the treatment. Often, nobody else is quite sure about the treatment modality of ICR.

### ACKNOWLEDGMENT

None

### REFERENCES

1. Heithersay GS. Invasive cervical resorption: an analysis of potential predisposing factors. *Quintessence Int.* 1999 Feb 1; 30.2.
2. Schwartz RS, Robbins JW, Rindler E. Management of invasive cervical resorption: observations from three private practices and a report of three cases. *J Endod.* 2010 Oct 1;36(10):1721-1730.
3. Heithersay GS. Management of tooth resorption. *Aus Dent J.* 2007 Mar; 52:105-121.
4. Sierra-Lorenzo A, Herrera-García A, Alonso-Ezpeleta LO, Segura-Egea JJ. Management of

Perforating Internal Root Resorption with Periodontal Surgery and Mineral Trioxide Aggregate: A Case Report with 5-Years Follow-Up. *Int J Periodontics Restorative Dent.* 2013;1; 33(2):65-71.

5. Regan JD, Gutmann JL, Witherspoon DE. Comparison of Diaket and MTA when used as root-end filling materials to support regeneration of the periradicular tissues. *Int Endod J* 2002; 35:840–847.
6. Main C, Mirzayan N, Shabahang S, Torabinejad M. Repair of root perforations using mineral trioxide aggregate: A long term study. *J Endod* 2004; 30:80–83.
7. Yildirima T, Gencoglu M. Use of mineral trioxide aggregate in the treatment of large periapical lesions: Reports of three cases. *Eur J Dent* 2010; 4:468–474.
8. Jacobovitz M, Vianna ME, Pandolfelli VC, Oliveira IR, Rossetto HL, Gomes BP. Root canal filling with cements based on mineral aggregates: An in vitro analysis of bacterial microleakage. *Oral Surg Oral Med Oral Pathol Oral Radiol Endod* 2009; 108:140–144.
9. Pathways of the Pulp by: Stephen Cohen and Richard Burns (Eds). *Australian Endodontic Newsletter.* 1987; 13(1):11