

## Original Research

### **Bisphosphonate- Related Osteoradionecrosis: A Case Report**

**Dr. Parnika Kuthiala<sup>1</sup>, Dr. Sunaina Singla<sup>2</sup>, Dr. Ramandeep Grewal<sup>3</sup>, Dr. Priya Pathak<sup>4</sup>, Priyanshi Sood<sup>5</sup>**

<sup>1</sup>Assistant professor, Department of Oral and Maxillofacial Surgery, Kartar Singh Saraba Dental College and Hospital, Ludhiana

<sup>2</sup>Consultant, Oral and Maxillofacial surgeon, New Delhi

<sup>3</sup>Assistant professor, Department of Oral and Maxillofacial surgery, JCD Vidyapeeth Dental College and Hospital, Haryana

<sup>4</sup>Consultant, Crescent Smiles Dental Clinic, Udaipur

<sup>5</sup>B.Pharm, MBA (Pharma Tech), Narsee Monjee Institute of Management Studies, Mumbai

#### ARTICLE INFO



Keywords:

Composite, Microleakage

#### ABSTRACT

Bisphosphonates are used to treat bony conditions like osteoporosis and malignant bone metastasis. Despite their therapeutic benefits, osteonecrosis of the jaws has recently emerged as a significant complication in patients receiving these drugs. Bisphosphonate-related osteonecrosis of the jaw (BRONJ) is a condition found in patients who have received intravenous and oral forms of bisphosphonate therapy for various bone-related conditions which in turn manifests as exposed, nonvital bone involving the maxillofacial structures. This case presentation focuses on 83-year-old man with a 4-year history of bisphosphonates for treatment of multiple myeloma, resulting in bisphosphonate-related osteoradionecrosis of the jaws (BRONJ).

#### INTRODUCTION

Bisphosphonates (BPs) are a class of agents used to treat osteoporosis and malignant bone metastasis.<sup>1</sup> They are synthetic analogs of pyrophosphates, a natural regulator of bone metabolism found in bone matrix. They inhibit the differentiation of osteoclastic precursors, induce apoptosis of osteoclasts and stimulate the release of osteoclastic inhibitory factors of osteoblasts. Despite these benefits, BP-related osteoradionecrosis of the jaws is significant complications in group of patients receiving these drugs.<sup>2</sup>

#### CASE REPORT

83 year old male patient reported to the department of Oral and Maxillofacial Surgery with chief complaint of exposed bone and pain in the lower back left jaw region for the past 2 months. History dates back to 2 months when patient first noticed the same. Pain was gradual in onset, intermittent in nature, moderate in intensity, localized, non radiating & non-referred in the lower left back jaw region for the past 2 months. Patient also gave history of multiple myeloma 4 years back for which he took bisphosphonates for consecutive 2 years. Patient had not undergone any radiotherapy. Patient was complete mandibular denture wearer for the past 7-8 years with uneventful extractions around 10 years back.

\* Corresponding author: **Dr. Parnika Kuthiala**, Assistant professor, Department of Oral and Maxillofacial Surgery, Kartar Singh Saraba Dental College and Hospital, Ludhiana.

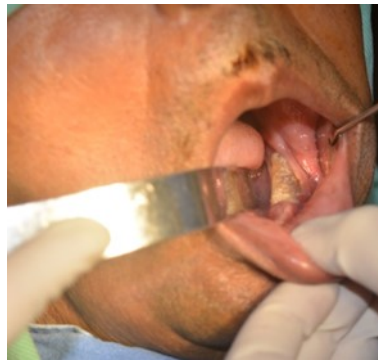Patient first reported to the department 2 years back with dull pain in the same region. The patient was then examined & attributed to history was advised to stop wearing the lower complete denture. Bisphosphonates were also stopped after the consultation with medical oncologist. Patient got relieved temporarily.

On extraoral examination, facial symmetry was intact with no extraoral sinus or fistula with a mouth opening of 3.5 cm (approx). On intraoral examination, presence of edentulous mandible and partially edentulous maxilla. Exposed bone was seen in the left body of the mandible of around 3cm X 1cm in size extending from the retromolar triangle to premolar region (Fig. I). The exposed bone was yellowish white and the surrounding mucosa was inflamed and foul smell was present. There was no discharge and no sinus. So correlating the history and clinical examination, provisional diagnosis of

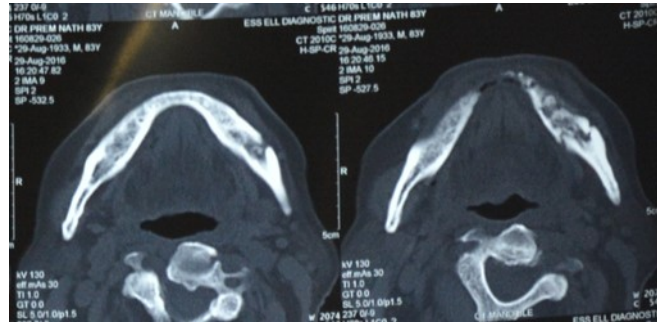
BRONJ was made with differential diagnosis of chronic osteomyelitis and tumor of the jaws.

Advanced radiological examination in form of the CT scan was done which showed the osteolytic lesion in the left body of the mandible region (Fig. II & Fig. III).

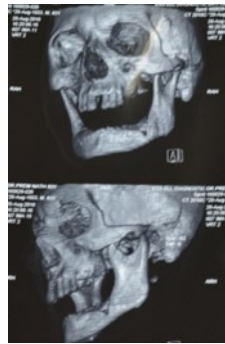After routine blood investigations along with LFT and RFT which were within normal physiological limits, sequestrectomy was done followed by the placement of PRF in the surgical site was done under local anaesthesia (Fig IV). Post operative antibiotic coverage was given. The removed bone was then sent for the histological examination which revealed bony tissue with empty lacunae and reversal line in a fibrocellular connective tissue stroma. The connective tissue stroma depicted numerous inflammatory cells and extravasated RBCs; suggestive of “*Sequestrum*” (Fig. V). After 6 months of the follow- up, there was no recurrence of the lesion on OPG and Patient was asymptomatic.



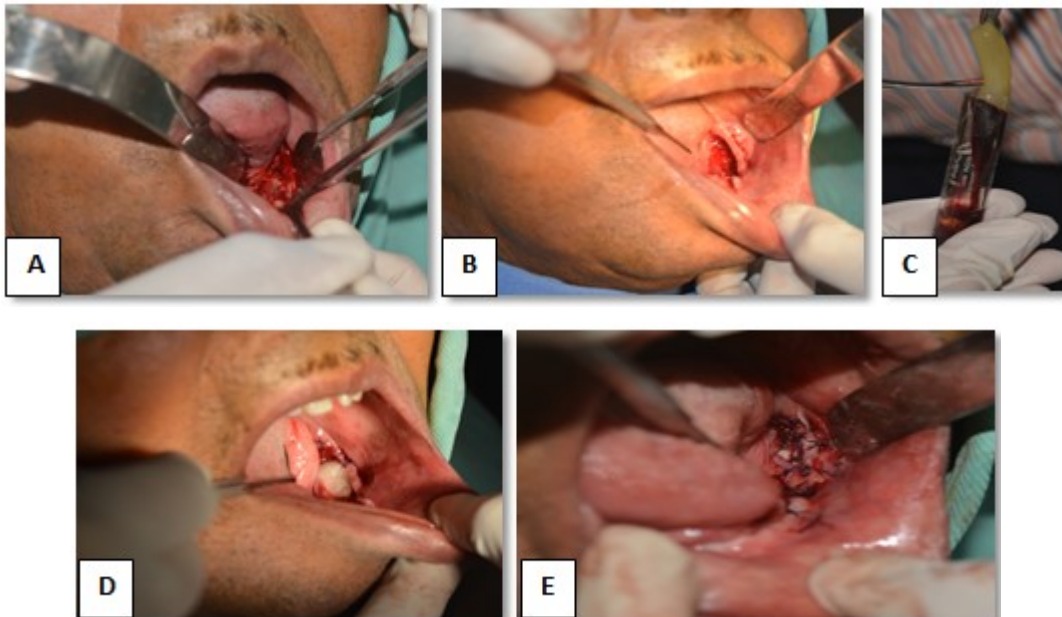
**Fig I:** Exposed bone in the left body of the mandible. around 3cm X 1cm in size extending from the retromolar triangle to premolar region

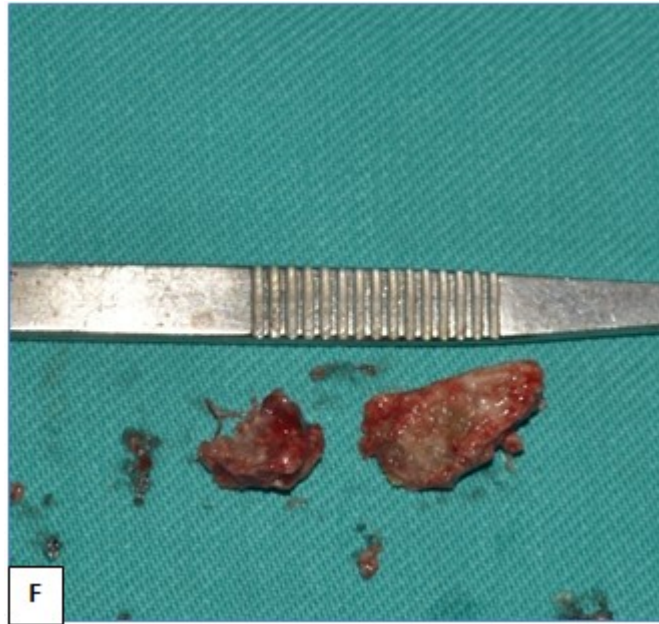


**Fig II:** Axial Section of CT scan showing diffuse osteolytic lesion in the left body of Mandible.

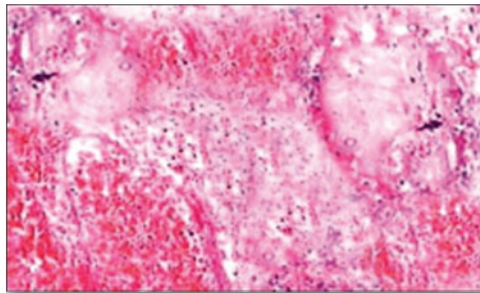


**Fig III:** 3D reconstruction of CT scan showing diffuse osteolytic lesion in the left body of mandible





**Fig IV:** A) Intraoral Surgical Site, B) Surgical Site After removal of Sequestrum, C) Preparation of PRF, D) Placement of PRF in the Surgical Site, E) Closure of the Surgical Site, F) Removed Sequestrum which is sent for HPE



**Fig V:** H& E stained section suggestive of SEQUESTRUM.

## DISCUSSION

Patient may be considered to have BRONJ if all the following three characteristics are present:

1. Current or previous treatment with bisphosphonates
2. Exposed bone in the maxillofacial region that has persist for more than 8 weeks.
3. No history of radiotherapy given to jaw.

In general, intravenous BPs shows higher incidence of BRONJ (0.8%-12%) as compared to oral forms (0.01-0.04%).<sup>2</sup>

## A REVIEW OF BISPHTHONATES

Bisphosphonates are synthetic analogues of inorganic pyrophosphates that have high affinity for calcium. Bisphosphonates are potent inhibitors of osteoclastic activity. Additionally, bisphosphonates have

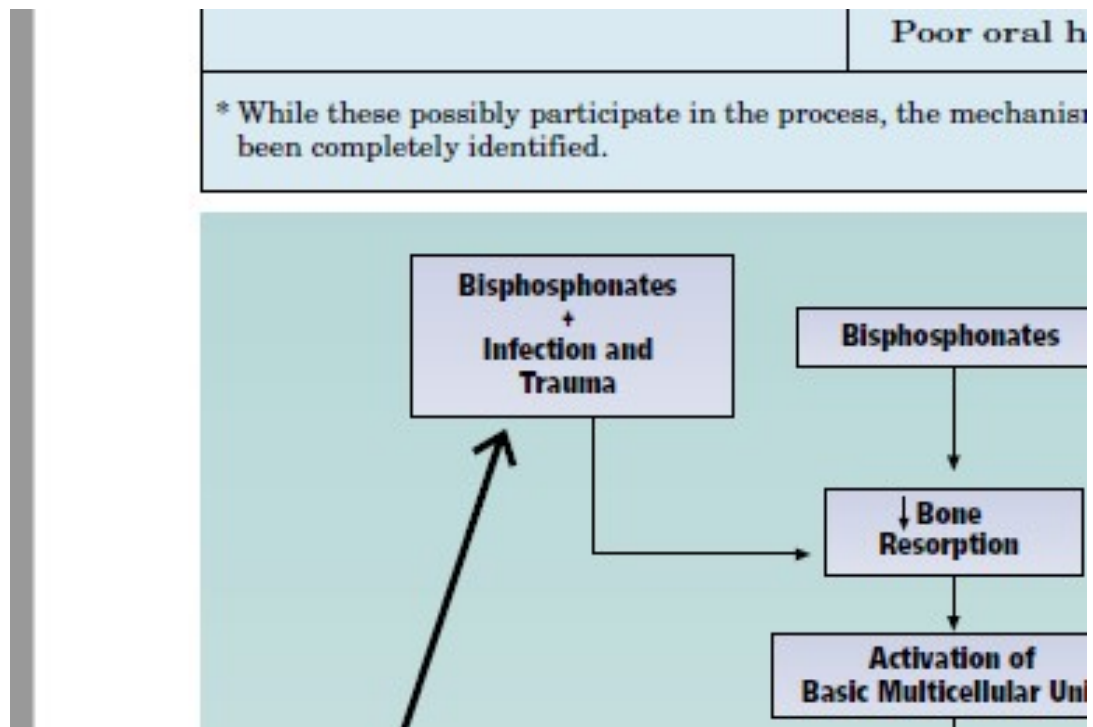
antiangiogenic properties and may be directly tumoricidal, making them an important agent in cancer therapy. Bisphosphonates are used to treat osteoporosis, Paget's disease of bone and hypercalcemia of malignancy.<sup>3,4</sup>

In patients with osteoporosis, it is expected that bisphosphonates will arrest bone loss and increase bone

density, decreasing the risk of pathological fracture resulting from progressive bone loss.

In patients with osteoradionecrosis, they inhibit the differentiation of osteoclastic precursors, induce apoptosis of osteoclasts and stimulate the release of osteoclastic inhibitory factors of osteoblasts.

**Pathobiological Model for the Development of BRONJ**



The AAOMS (American Association of Oral & Maxillofacial Surgeons) proposes use of **staging categories and their respective treatments** as under:<sup>2,6</sup>

Stage 0	Dull, aching bone pain in the body of the mandible, odontalgia with no odontogenic cause, sinus pain, periodontally involved teeth not explained by dental origin.	Symptomatic treatment, conservative management of local factors, including chronic pain management & possible antibiotic therapy
Stage I	Exposed/necrotic bone, asymptomatic, no evidence of infection	Antimicrobial rinses and no surgical intervention
Stage II	Exposed/ necrotic bone, pain, erythema, purulent drainage may or may not be present	Antimicrobial rinses, systemic antibiotics or antifungals, analgesics.
Stage III	Exposed/ necrotic bone, pain/ infection, pathologic fracture, extraoral fistula, osteolysis to inferior border,	Antimicrobial rinses, systemic antibiotics or antifungals, analgesics, surgical debridement or

## CONCLUSION

Given the many unknowns associated with BRONJ, it would seem prudent to develop a coordinated pretreatment and intratreatment protocol aimed at prevention and patient education. Preventive strategies such as establishment of meticulous oral hygiene regimes in conjunction with timely surgical procedures should be undertaken prior to commencing therapy. During therapy, strict review and maintenance of oral hygiene programs are essential in order to prevent the development of pathology

## REFERENCES

1. González-García M, Rodríguez-Lozano FJ, Villanueva V, Segarra-Fenoll D, Rodríguez-González MA, Oñate-Sánchez R et al. Cell Therapy in Bisphosphonate-Related Osteonecrosis of the Jaw. *Journal of Craniofacial Surgery*. 2013; 24(3), e226–e228.
2. Bhuyan R, Bhuyan S, Panigrahi RG, Panigrahi A. Bisphosphonate-induced osteoradionecrosis. *J Oral Maxillofac Pathol*. 2013; 17(3):460-462
3. Cankaya AB, Erdem MA, Isler SC, Demirçan S, Soluk M, Kasapoglu C, et al. Use of cone-beam computerized tomography for evaluation of bisphosphonate-associated osteonecrosis of the jaws in an experimental rat model. *International journal of medical sciences* 2011; 8(8):667.
4. Fehm T, Beck V, Banys M, Lipp HP, Hairass M, Reinert S et al. Bisphosphonate-induced osteonecrosis of the jaw (ONJ): Incidence and risk factors in patients with breast cancer and gynecological malignancies. *Gynecologic oncology*, 2009; 112(3):605-9.
5. Migliorati CA, Casiglia J, EPSTEIN J, Jacobsen PL, Siegel MA, Woo SB. Managing the care of patients with bisphosphonate associated osteonecrosis. *JADA*. 2005; 136:1658-1668.
6. Rosella D, Papi P, Giardino R, Cicalini E, Piccoli L, Pompa G. Medication-related osteonecrosis of the jaw: Clinical and practical guidelines. *J Int Soc Prev Community Dent*. 2016; 6(2):97-104.
7. Vyas T, Kuthiala P, Vishnoi P. Oral cancer: Etiology and Its diagnostic aids. *Int J Drug Research & Dent Science*. 2019; 1(2):13-18.